

## Ochronosis in a Young Female-A Rare Case Report

Dr. Madhavi Shrivastava<sup>1</sup>, Dr. Fakeha Firdous<sup>2</sup>, Dr. Ch V Ramana Murty<sup>3</sup>, Dr. Jaweria<sup>4</sup>

<sup>1</sup>Consultant Pathologist, Jubilee Lab, Hyderabad, Telangana, India

<sup>2</sup>Associate Professor, Dept of Pathology, Shadan Institute of Medical Sciences, Telangana, India

<sup>3</sup>Professor and HOD, Professor, Dept of Pathology, Shadan Institute of Medical Sciences, Telangana, India

<sup>4</sup>Assistant Professor Dept of Pathology Shadan Institute of Medical Sciences, Telangana, India

### \*Corresponding author

Dr. Fakeha Firdous

Email: [drfirdous23@rediffmail.com](mailto:drfirdous23@rediffmail.com)

---

**Abstract:** Alkaptonuria is a rare genetic autosomal recessive metabolic disorder resulting in a deficiency of homogentisic acid oxidase which causes the accumulation of homogentisic acid in various bodily tissues. This is a multisystem disorder with a characteristic blue-black discoloration of the skin and cartilage, which is termed *ochronosis*. Herein we report a profound case of ochronosis secondary to alkaptonuria. Furthermore, we review the clinical manifestations of alkaptonuria and discuss the spectrum of ochronosis, both endogenous and exogenous.

**Keywords:** ochronosis, Alkaptonuria, metabolic disorder, genetic disorder.

---

### INTRODUCTION

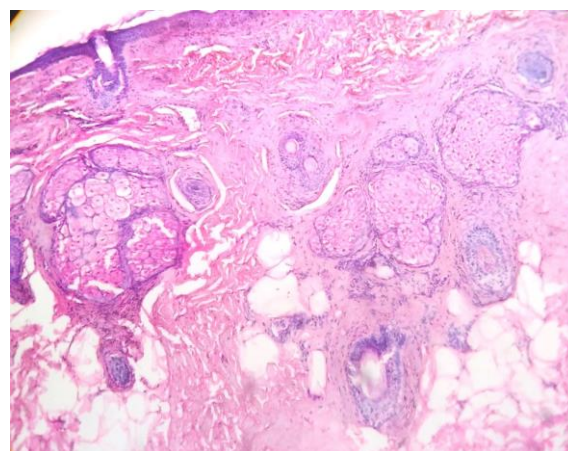
Ochronosis is the deposition of polymerized products of homogentisic acid in the connective tissues resulting in bluish black discoloration. It is one of the major manifestations of alkaptonuria, which is a rare autosomal recessive metabolic disorder characterized by deficiency of homogentisate 1,2-dioxygenase enzyme [1]. The major manifestations include the following: Urinary elimination of homogentisic acid, arthritis of large joints, deposition of pigment in soft tissues, and rarely cardiac, renal (nephrolithiasis), and ocular affliction. The joint involvement is generally clinically manifested in the third decade [2]. We encountered 1 case of ochronosis with skin involvement -pigmented macules at multiple sites. The rare and interesting presentation of this case has prompted us to report this case

### CLINICAL DETAILS

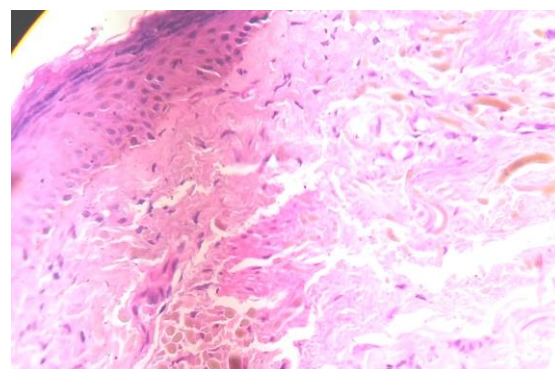
30-year-old woman presented with and history pigmented macules[progressive bluish black] at multiple sites over right cheek and of passing dark colored urine since childhood. Skin involvement was noted over the face, predominantly right cheek. Urine alkalization showed development of black color. Diagnosis of ochronosis was made on the basis of the clinical and laboratory findings and the patient underwent skin biopsy.

Gross examination showed blackish discoloration of the skin over the right cheek, face. Histopathological examination revealed epidermis and dermis. epidermis revealed mild to moderate atrophy with superficial dermis showing thickened collagen bundles with yellow brown discoloration. Some of the

bundles show curving and bending of collagen fibers. Deeper dermis revealed sebaceous glands and hair follicles. No evidence of melanin pigment [S100-negative for melanin pigment].



**Fig-1: low power view -Ochronosis**



**Fig-2: High power view-Ochronosis**

## DISCUSSION

Alkaptonuric ochronosis is a rare autosomal recessive metabolic disorder resulting in a deficiency of homogentisic acid oxidase (alkaptonuria). Ultimately, this enzyme deficiency enables homogentisic acid to accumulate, become polymerized, and be systemically deposited within various tissues of the body (ochronosis). This is a multisystem disorder with a characteristic blue-black discoloration of the skin and cartilage, which is termed ochronosis [6]. As the disease progresses, tissue deposition of polymerized homogentisic acid eventually will lead to the progressive degeneration of all affected body systems.

The term alkaptonuria was first coined by Boedeker in 1891, as quoted by Fischer *et al.* [2]. The term ochronosis was first used by Virchow due to the accumulation of the granular yellowish pigment in the connective tissue, which resembled ochre (yellow) [2]. Ochronosis was first described by Scribonius in 1584 in a boy whose urine was "as black as ink."

One of the earliest manifestations of alkaptonuria is darkening of urine. The urine is of a normal color on voiding; however, it darkens on standing for several hours [2, 3]. Our patient gave history of passing dark urine, thus highlighting the utility of the simple urine alkalization test for diagnosis.

Discoloration of the skin is usually observed after the third decade [2]. The most commonly involved sites are the ear cartilage, eyelids, sclera, and nails. Tendons may also be involved, frequently observed as discoloration over the knuckles. Our patient showed significant skin discoloration.

Degenerative joint disease usually develops after the third decade. Low back pain was observed in 94% of patients before the age of 40 years in one large series [1]. The knee, hip, and shoulder joints are also frequently affected. By the age of 55 years, 50% of patients required at least one joint replacement surgery [1]. Reviewing the literature, ochronosis has been documented to be associated with affection of the heart in the form of valvular dystrophic calcification, aortic stenosis, and coronary disease. Some workers have reported occurrence of nephrolithiasis. Ocular manifestations in ochronosis have been reported to be mistaken for melanoma [2]. It must be mentioned that in our case there was absence of cardiac, renal, or ocular complications and these were ruled out by relevant investigations. Macroscopically the tissue pigmentation varied from brown to black. Ochronotic pigment is documented to be deposited in the form of ochre colored granules in all layers of the cartilage [4].

Currently there is no effective treatment for alkaptonuria and management is symptomatic. Treatment is aimed at controlling and ameliorating

symptoms Arthropathy is usually treated with NSAIDs; however, in advanced cases, joint replacement surgery provides significant relief from symptoms.

## Exogenous ochronosis

Exogenous ochronosis was first described by Beddard and Plumtrein in a patient following the use of phenol for leg ulcer. Topical application of hydroquinone (1975 by Findlay), phenol, resorcinol, oral anti-malarials have been implicated too. Facial hyperpigmentation not responding to long term treatment with bleaching agents should be dealt with high index of suspicion for exogenous ochronosis. An early diagnosis necessitates immediate discontinuation of hydroquinone, rather than increasing the concentration in attempt to clear the dermatosis. Exogenous ochronosis is often missed clinically and also under reported [7, 8].

Microscopy of ochronosis: Yellow-brown sharply defined irregularly shaped and frequently fragmented fibers in superficial dermis

- Ochronotic pigment is autofluorescent, appears black with methylene blue, but does not stain with Van Gieson or Pearl's stain or the Masson Fontana reaction
- Pigment granules often present in epithelium and basement membrane of sweat glands, in endothelium and within dermal macrophages
- Hydroquinone induced ochronosis shows melanophages in upper dermis associated with depigmentation of the epidermal melanocytes
- In early lesions, collagen fibers appear basophilic and swollen before developing characteristic yellow ochronotic morphology
- With chronicity, large amorphous eosinophilic granules may develop resembling colloid milium
- Solar elastosis and foreign body granuloma are common features
- Pigmentation secondary to antimalarial drugs is due to melanin and hemosiderin deposition in addition to the classic ochronotic fibres [7, 8].

**CONSENT:** Taken from the patient

## REFERENCES

1. Phornphutkul C, Introne WJ, Perry MB, Bernardini I, Murphey MD, Fitzpatrick DL. Natural history of alkaptonuria. *N Engl J Med.* 2002;347:2111-21.
2. Fisher AA, Davis MW. Alkaptonuric ochronosis with aortic valve and joint replacements and femoral fracture. *Clin Med Res.* 2004;2:209-15.
3. Longo N. Inherited disorders of amino acid metabolism presenting in adults. In: Braunwald E, Fauci AS, Kasper DL, Hauser SL, Longo DL, Jameson JL, editors. *Harrison's Principles of Internal Medicine.* 15<sup>th</sup> ed. New York: McGraw Hill; 2001. p. 2307.

4. Laskar FH, Sargison KD. Ochronotic arthropathy. *J Bone Joint Surg.* 1970;52:653-66.
5. Kruithof E, Baeten D, Veys EM, De Keyser F, Suykens S, De Wilde L. Case Number 29: Ochronosis: Synovial histopathological characteristics. *Ann Rheum Dis.* 2004;63:130.
6. Albers SE, Brozena SJ, Glass LF, Fenske NA. Alkaptonuria and ochronosis: case report and review. *Journal of the American Academy of Dermatology.* 1992 Oct 1;27(4):609-14.
7. Findlay GH, Morrison JGL, Simson IW. Exogenous ochronosis and pigmented colloid milium from hydroquinone bleaching creams. *Br J Dermatol.* 1975;93:613-22.
8. Levin CY, Maibach H. Exogenous ochronosis: An update on clinical features, causative agents] and treatment options. *Am J Clin Dermatol.* 2001;2:213-7.