

Intrapulmonary Localization of a Solitary Fibrous Tumour: A Case Report

Walid El Harich^{1*}, Bayem Joel Cedric¹, Hicham Fenane¹, Yassine Msougar¹

¹Thoracic Surgery Department of the University Hospital of Marrakech, Morocco

DOI: [10.36347/sajs.2023.v09i04.005](https://doi.org/10.36347/sajs.2023.v09i04.005)

| Received: 02.03.2023 | Accepted: 14.04.2023 | Published: 18.04.2023

*Corresponding author: Walid El Harich

Thoracic Surgery Department of the University Hospital of Marrakech, Morocco

Abstract

Case Report

Solitary fibrous tumour (SFT) is a relatively rare neoplasm, accounting for only 5% of all pleural tumors¹. SFTs are ubiquitous and can involve any organ. Intra pulmonary localization is extremely rare. Some authors suggest the probability of originating from mesenchymal cells of the sub mesothelial tissue of the pleura². They are usually benign but may degenerate. Their diagnosis is pathologic after complete surgical resection. Long-term follow-up is essential.

Keywords: Lung tumor, Solitary fibrous tumor, Surgery.

Copyright © 2023 The Author(s): This is an open-access article distributed under the terms of the Creative Commons Attribution **4.0 International License (CC BY-NC 4.0)** which permits unrestricted use, distribution, and reproduction in any medium for non-commercial use provided the original author and source are credited.

INTRODUCTION

The solitary fibrous tumour (SFT) is a relatively rare neoplasm, which makes only 5% of all pleural tumors [1]. SFT is ubiquitous and can affect any organ. Intra-pulmonary localization is extremely rare. Authors suggest the probability of provenance of mesenchymal cells from the sub mesothelial tissue of the pleura [2]. They are generally benign but can degenerate [3, 4]. Their diagnosis is anatomopathological after a complete surgical resection.

We report a case of a solitary fibrous tumour, admitted and managed in the department of thoracic surgery at the Mohammed VI University Hospital of Marrakech.

OBSERVATION

We report the case of a 62-year-old woman, followed for a hetero nodular goitre under medical treatment, presenting with a dry cough and dyspnea stage IV for 4 months.

The chest X-ray showed a large homogeneous opacity taking up the upper 2/3 of the left hemi field. With a history of passive smoking and exposure to wood smoke for 40 years. A thoracic CT scan revealed a left anteroposterior compressive mediastino-pulmonary mass measuring 11.6 x 15 x 15.7 cm, with micro calcifications and necrosis (figure 1).

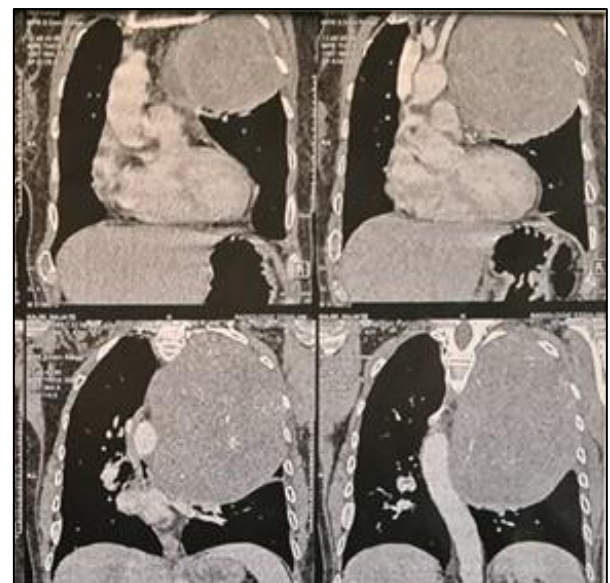


Figure 1: Sagittal slice TAP CT showing a large left upper mediastino-pulmonary mass compressing the mediastinal elements

Two biopsies were performed, the first in favour of a pulmonary sarcoma and the second in favour of a solitary fibrous tumour. Given this duality and the compressive nature of the mass, a thoracotomy for diagnostic and therapeutic purposes was indicated. Exploration by posterolateral thoracotomy revealed a large intraparenchymal tumour process occupying the entire upper left lobe and invading the lower left lobe. A left pneumonectomy was performed (figure 2).

Anatomopathological study of the left pneumonectomy specimen confirmed the diagnosis of Solitary Fibrous Tumour. Immunohistochemistry showed that the tumour expressed the anti-CD34 antibody, the anti-STAT6 antibody. The Anti-Bcl2 antibody, Anti-Desmin antibody and Anti-PS100 antibody are negative.

The patient had a simple postoperative aftermath and declared outgoing to D11 after surgery.

A thoracic CT scan performed after 10 months of follow-up revealed no recurrence.

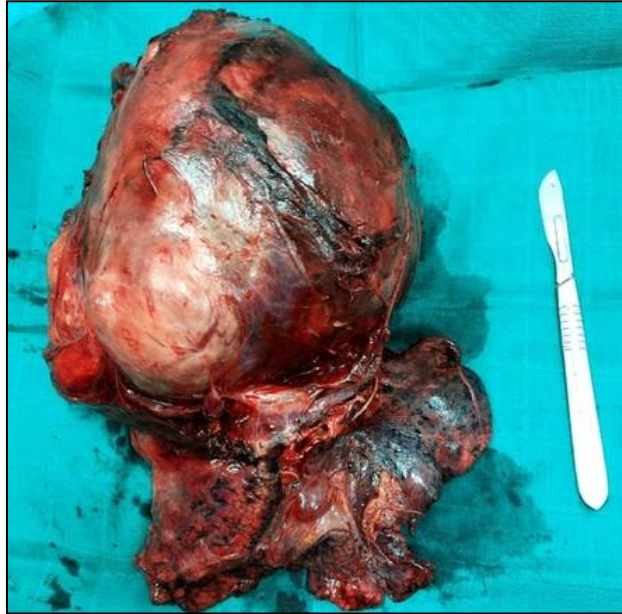


Figure 2: An image showing the surgical specimen after a left pneumonectomy

DISCUSSION

SFTs are rare mesenchymal proliferations, with an incidence of 1.4 per million and a fairly low rate of malignancy (13% to 37%) [5, 6]. The intrapulmonary forms described as unusual locations are only (5% to 13%) [5, 7–9]. In such cases, the radiographic characteristics mimic those of a primary lung tumour, the advanced age (the 6th to the 8th decade) is common, with no sex predilection or exposure to a promoting toxic agent [7, 10, 11]. The intrapulmonary localizations of SFT can be attributed to two main hypotheses. The first relates to the mesenchyma under pleural which is in direct continuity with intra lobular connective septa or visceral pleura invagination which gives rise to intrapulmonary fibromas. The second is that these tumours come from optional fibroblastic elements present in sub mesothelial areas of normal pulmonary parenchyma.

According to the literature, intrapulmonary SFT is rarely malignant (12.5%) [8]. However, this figure reflects only a limited number of cases.

Clinically, the majority of SFT patients are symptomatic and present with cough, chest pain, dyspnoea and sometimes fever. In asymptomatic patients, tumours are usually discovered on routine chest radiographs [11]. The chest scanner helps to clarify the size and location of the tumour and helps with surgical planning. Mass biopsy and histopathology

examination is usually required. Fine needle aspiration or bronchoscopic biopsy are often insufficient for reliable therapeutic guidance [12].

The differential diagnosis of SFT is that of any massive lesion of the thorax; from lung cancer to various intra-pleural sarcomas.

Immunohistochemistry is essential to differentiate SFT from other neoplasms. These tumours are positively stained at CD34, Vimentin and Bcl2, and show no immunoreactivity to cytokeratin, Desmine, smooth muscle alpha actin and S100 protein [13, 14].

The mainstay of intrapulmonary SFT treatment is complete and wide surgical resection (1 to 2 cm safety margin) [11, 12]. To avoid locoregional recurrences, thoracotomy or video-assisted surgery (VATS). We opted for a left posterolateral thoracotomy based on the size of the tumour and a left pneumonectomy based on the invasion of the lower left lobe.

The results were favourable in the majority of patients with intrapulmonary SFT. The prognosis is generally good, which depends on the size, site of the tumour and its aggressiveness.

Prolonged periodic monitoring is required, starting with 6-month intervals for the first 2 years, with

annual CT checking [7]. There is no consensus on follow-up in the literature.

CONCLUSION

Solitary fibrous intrapulmonary tumour is extremely rare. Complete and wide resection remains the best treatment to cure and avoid recurrence. Long-term patient monitoring is essential.

CONFLICTS OF INTEREST

The authors declare that they have no conflicts of interest.

REFERENCES

1. Ichiki, Y., Kakizoe, K., Hamatsu, T., Matsuyama, A., Suehiro, T., Tanaka, F., ... & Sugimachi, K. (2017). Solitary fibrous tumor of the lung: a case report. *Surgical Case Reports*, 3, 1-5. doi:10.1186/s40792-016-0286-7
2. Magdeleinat, P., Alifano, M., Petino, A., Le Rochais, J. P., Dulmet, E., Galateau, F., ... & Regnard, J. F. (2002). Solitary fibrous tumors of the pleura: clinical characteristics, surgical treatment and outcome. *European journal of cardio-thoracic surgery*, 21(6), 1087-1093. doi:10.1016/s1010-7940(02)00099-4
3. Franzen, D., Diebold, M., Soltermann, A., Schneiter, D., Kestenholz, P., Stahel, R., ... & Kohler, M. (2014). Determinants of outcome of solitary fibrous tumors of the pleura: an observational cohort study. *BMC Pulmonary Medicine*, 14(1), 1-8. doi:10.1186/1471-2466-14-138
4. Furukawa, N., Hansky, B., Niedermeyer, J., Gummert, J., & Renner, A. (2011). A silent gigantic solitary fibrous tumor of the pleura: case report. *Journal of Cardiothoracic Surgery*, 6(1), 1-4. doi:10.1186/1749-8090-6-122
5. Thorgeirsson, T., Isaksson, H. J., Hardardottir, H., Alfredsson, H., & Gudbjartsson, T. (2010). Solitary fibrous tumors of the pleura: an estimation of population incidence. *Chest*, 137(4), 1005-1006. doi:10.1378/chest.09-2748
6. Ardissonne, F. (2011). Thoracic malignant solitary fibrous tumors: Prognostic factors and long-term survival. *J Thorac Dis.*, 3(2), 84-85. doi:10.3978/j.issn.2072-1439.2011.03.05
7. de Perrot, M., Fischer, S., Bründler, M. A., Sekine, Y., & Keshavjee, S. (2002). Solitary fibrous tumors of the pleura. *Ann Thorac Surg.*, 74(1), 285-293. doi:10.1016/s0003-4975(01)03374-4
8. Gold, J. S., Antonescu, C. R., Hajdu, C., Ferrone, C. R., Hussain, M., Lewis, J. J., ... & Coit, D. G. (2002). Clinicopathologic correlates of solitary fibrous tumors. *Cancer*, 94(4), 1057-1068.
9. Carretta, A., Bandiera, A., Melloni, G., Ciriaco, P., Arrigoni, G., Rizzo, N., ... & Zannini, P. (2006). Solitary fibrous tumors of the pleura: Immunohistochemical analysis and evaluation of prognostic factors after surgical treatment. *Journal of Surgical Oncology*, 94(1), 40-44. doi:10.1002/jso.20562
10. Robinson, L. A. (2006). Solitary fibrous tumor of the pleura. *Cancer Control J Moffitt Cancer Cent.*, 13(4), 264-269. doi:10.1177/107327480601300403
11. England, D. M., Hochholzer, L., & McCarthy, M. J. (1989). Localized benign and malignant fibrous tumors of the pleura. A clinicopathologic review of 223 cases. *Am J Surg Pathol.*, 13(8), 640-658. doi:10.1097/00000478-198908000-00003
12. Cardillo, G., Facciolo, F., Cavazzana, A. O., Capece, G., Gasparri, R., & Martelli, M. (2000). Localized (solitary) fibrous tumors of the pleura: an analysis of 55 patients. *The Annals of thoracic surgery*, 70(6), 1808-1812. doi:10.1016/s0003-4975(00)01908-1
13. Zhu, Y., Du, K., Ye, X., Song, D., & Long, D. (2013). Solitary fibrous tumors of pleura and lung: report of twelve cases. *Journal of thoracic disease*, 5(3), 310-313. doi:10.3978/j.issn.2072-1439.2013.05.19
14. Sakurai, H., Tanaka, W., Kaji, M., Yamazaki, K., & Suemasu, K. (2008). Intrapulmonary localized fibrous tumor of the lung: a very unusual presentation. *The Annals of thoracic surgery*, 86(4), 1360-1362. doi:10.1016/j.athoracsur.2008.04.014