

Hydropneumothorax after Pyeloplasty Via Dorsal Lumbotomy: A Rare Complication

Dr. Apoorva Kulkarni, Dr. Abhaya Gupta, Dr. Vishesh Dikshit, Dr. Paras Kothari, Dr. Prashant Patil

Department of Pediatric Surgery, Lokmanya Tilak Municipal Medical College and Government Hospital, Mumbai, India

***Corresponding author**

Dr. Apoorva Kulkarni

Email: apookool@gmail.com

Abstract: Open Anderson-Hyne's pyeloplasty is a standard treatment for pelvi-ureteric junction obstruction (PUJO). Hydropneumothorax is an unheard of complication in pyeloplasty. A 2 month old male child operated for pyeloplasty via dorsal lumbotomy developed dyspnea due to hydrpneumothorax on post-operative day 1. The patient went into cardiac arrest, was ventilated, an intercostal drain inserted, but the patient eventually recovered and was discharged subsequently after post-operative day 10.

Keywords: hydropneumothorax, dorsal lumbotomy, pyeloplasty

INTRODUCTION

A 2 month old male child, antenatally diagnosed case of left sided hydronephrosis, was posted for open modified Anderson-Hyne's pyeloplasty. He developed hydropneumothorax, a rare, almost unheard of complication. Its urgent and aggressive management led to the eventual discharge of the patient.

CAES REPORT

A 2 month old male child, antenatally diagnosed case of left hydronephrosis, was followed up in our OPD postnatally. There was no history of any urinary complaints. There was no palpable lump in lumbar region or renal fossa. He was non-hypertensive.

All routine blood investigations were normal. Ultrasonography of kidney-ureter-bladder showed good kidney size and parenchymal thickness on both sides. Antero-posterior diameter of left renal pelvis was 2.1 cm. Right renal pelvis was not dilated. Both ureters were not dilated. Bladder wall was not thickened. There were no internal echoes.

A mercaptoacetyltriglycine (MAG3) renal scan showed a progressive but obstructed drainage curve of the left kidney. The T1/2 was not achieved. Urine routine and microscopy was normal. Urine culture showed no growth.

Micturating cystourethrogram was normal. Posterior urethra was normal. Bladder was not trabeculated. There was no vesicoureteral reflux.

Patient underwent a left sided modified Anderson-Hyne's dismembered pyeloplasty via a transverse dorsal lumbotomy incision. This incision is regularly used for pyeloplasties at our institute [1, 2]. Muscle layers were split to reach the renal pelvis. A dismembered pyeloplasty was done. A perinephric mini-suction drain was kept with its tip under the Gerota's fascia. After the procedure, it was noticed that there was a slight oscillatory movement of the fluid in the drain tubing, but was deemed to be due to hand ventilation by the anesthetist. Patient was extubated and shifted to the recovery uneventfully.

Patient started having respiratory distress on post-operative day 1 morning. Patient did not improve with oxygen and nebulization. Urgent bed-side chest radiograph was done which showed an air-fluid level in the left hemithorax. (Fig. 1) An intercostal drain (ICD) was inserted bed-side under local anesthesia. Patient went into cardiac arrest and was given cardiopulmonary resuscitation, was intubated and ventilated.. Patient was revived, was ventilated for 2 days after which his vitals stabilized and he was extubated. There was significant improvement of left hemithorax after ICD insertion. (Fig 2) The ICD was removed after 3 days after confirming full lung expansion. The perinephric drain was removed on post-operative day 7 after nil output for 3 days. Patient was discharged on chemoprphylaxis on post-operative day 10.

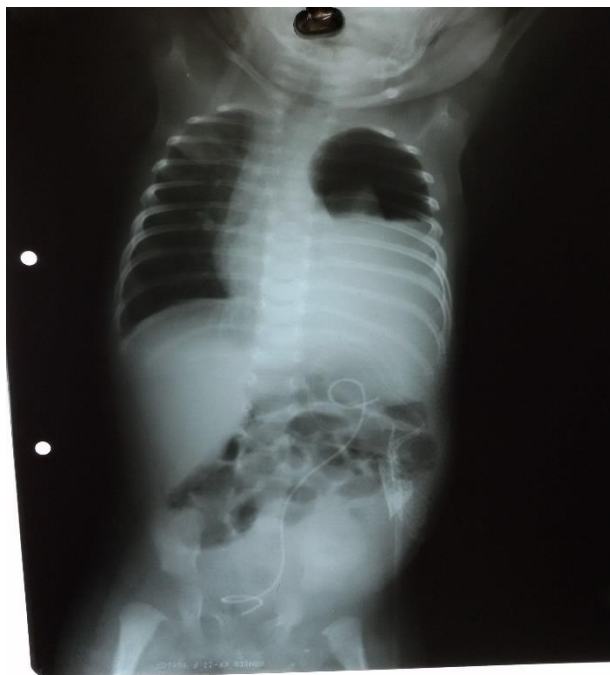

Fig-1: Hydropneumothorax of left side

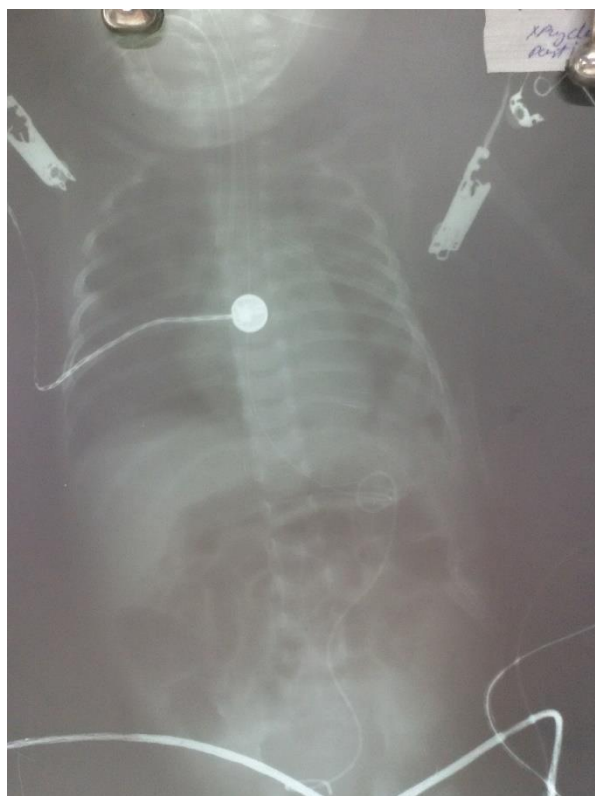


Fig-2: Expanded lung on post-operative day 3

DISCUSSION

Congenital PUJO is defined as a functional or anatomic obstruction to urine flow from the renal pelvis to the ureter that left untreated results in symptoms or renal damage. The term *obstruction* is imprecise. Complete antenatal obstruction of the PUJ results in a nonfunctioning kidney, such as a multicystic dysplastic

kidney. In clinical practice, the problematic issue regarding UPJ obstruction is whether it is incomplete or partial. Generally, PUJ obstructions are described as minimal, moderate, or severe [3].

The clinician relies mainly on three criteria for determining the significance of hydronephrosis: (1) the

amount of hydronephrosis present on ultrasound (anteroposterior diameter), (2) the relative renal function as measured by renal scintigraphy, and (3) the rate of radionuclide washout with furosemide [4].

Open Anderson–Hynes pyeloplasty has been widely accepted as the surgical treatment of choice for PUJ obstruction in children, with a success rate of >90% in most reports [5]. Pyeloplasty can be performed by anterolateral, flank or dorsal lumbotomy approach. Dorsal lumbotomy is either via vertical or transverse incision [6]. In our institute, we advocate use of transverse incision in all our cases, including patients with malrotated kidney and red-pyeloplasty cases, although some authors advise against it [7]. The advantages of dorsal lumbotomy approach are quick and easy access to the renal pelvis, minimal post-operative pain, short duration of hospital stay and low incidence of incisional hernia [8].

Hydrothorax is a rare but known complication after nephrolithotomy (PCNL) carried out via a supracostal incision (between 11th and 12th ribs) [9]. Hydrothorax has been described as a rare complication developing after endopyelotomy for pelvi-ureteric junction obstruction (PUJO). It has not been described in literature yet as a complication of open pyeloplasty, particularly via dorsal lumbotomy. It is the first case reported to have such a complication.

CONCLUSION

Hydropneumothorax as a complication is a rare possibility after pyeloplasty procedure. It should be kept in mind especially when the patient has respiratory distress post-operatively. Urgent and aggressive management is warranted.

REFERENCES

1. Bajpai M, Kumar A, Tripathi M, Bal CS. Dorsal lumbotomy incision in paediatric pyeloplasty. *ANZ J Surg.* 2004 Jun;74(6):491-4.
2. Kumar R, Smith G. Dorsal lumbotomy incision for pediatric pyeloplasty – a good alternative. *Pediatr Surg Int.* 1999;15: 562.
3. Park JM, Bloom DA. The pathophysiology of UPJ obstruction: current concepts. *Urologic Clinics of North America.* 1998 May 1;25(2):161-9.
4. DiSandro MJ, Kogan BA. Neonatal management: role for early intervention. *Urologic Clinics of North America.* 1998 May 1;25(2):187-97.
5. Mikkelsen SS, Rasmussen BS, Jensen TM. Long-term follow-up of patients with hydronephrosis treated by Anderson-Hynes pyeloplasty. *Br J Urol.* 1992; 79:121.
6. Bajpai M, Kumar A, Gupta AK, Pawar DK. Lumbotomy approach for upper urological tract surgery in children- An analysis of 68 consecutive lumbotomies. *Eur J Pediatr Surg.* 2004; 14:163-167.
7. Chottopadhyay A, Mukhopadhyay B, Mitra SK. Lumbotomy for multicystic dysplastic kidney: A trap for the unwary. *J Pediatr Surg.* 2014; 4: 145-147.
8. Braga LH, Lorenzo AJ, Bagli DJ. Comparison of flank, dorsal lumbotomy and laparoscopic approaches for dismembered pyeloplasty in children older than 3 years with ureteropelvic junction obstruction. *J Urol.* 2010;183: 306-311.
9. Prakash S, Virmani P, Gupta P, Pawar M. Massive hydrothorax following supracostal percutaneous nephrolithotomy. *Indian J Anaesth.* 2015 May; 59(5): 328–330.