

Malignant Peripheral Nerve Sheath Tumour involving scapular region – A cyto histo correlation

Dr. S. Srikanth

Associate Professor, Department of Pathology, Prathima Institute of Medical Sciences, Karimnagar, Telangana State, India.

***Corresponding author**

Dr. S. Srikanth

Email: drshastrysri@yahoo.com

Abstract: Malignant peripheral nerve sheath tumor (MPNST) is a rare soft tissue sarcoma of ectomesenchymal origin. It is the malignant counterpart of benign soft tissue tumors like neurofibromas and schwannomas and may often follow them. Common sites include deeper soft tissues, usually in the proximity of a nerve trunk. MPNSTs have an incidence of 1 per 1,000,000 people per year and comprise around 3% of soft-tissue sarcomas. Tumours arise from Schwann cells or perineural cells that ensheath axons and extend along neural tracts. They are aggressive cancers that have high rates of recurrence and a poor prognosis.

Keywords: MPNST, scapular region, Cytology, Histopathology finding

INTRODUCTION

MPNSTs are high grade sarcomas with a high tendency for local recurrence and distant metastasis. MPNSTs are rare neoplasms accounting for approximately 5-10% of all soft tissue sarcomas. Approximately, 50-60% of MPNSTs are associated with Von Recklinghausen's disease. MPNSTs are rare neoplasms originating from the neural sheath of peripheral nerves. MPNST is the preferred term for tumors originating from peripheral nerves or from cells associated with the nerve sheath, such as Schwann cells, perineural cells replacing previous entities such as malignant schwannoma, malignant neurilemmoma and neuro fibro sarcoma. They represent approximately 10% of all soft tissue sarcomas [1]. Here we are presenting a case of MPNST located over right scapular region which was diagnosed cytologically and confirmed by Histopathology.

CASE REPORT

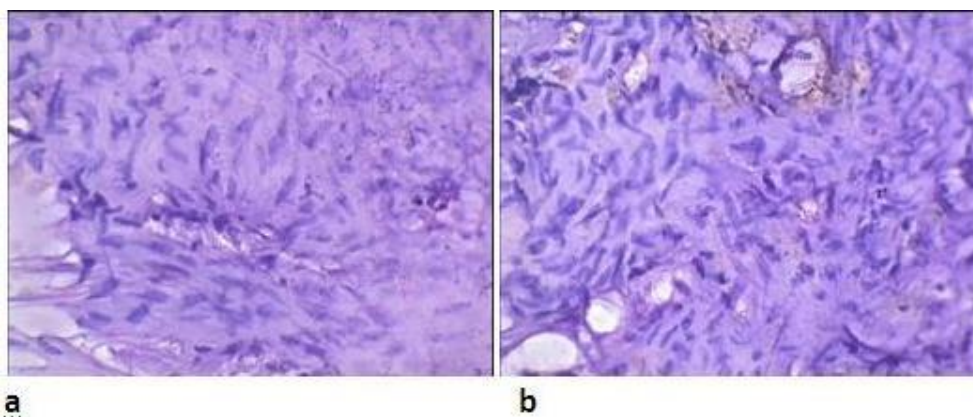
A 50 year male patient came with complaints of swelling over right scapular region since three years. Swelling was small in size initially later increased to the present size measuring upto 8x6cm. The swelling was firm in consistency with restricted mobility and nodular on palpation. FNAC was performed and reported as low grade MPNST. Later the swelling was operated and sent for biopsy. We received a skin covered soft tissue specimen measuring 8x6 cm firm to hard in consistency, cut section show well circumscribed lesion, grey white to yellowish in colour with multiple nodules along with focal areas of necrosis. Multiple bits were given and diagnosed as MPNST Histopathologically.

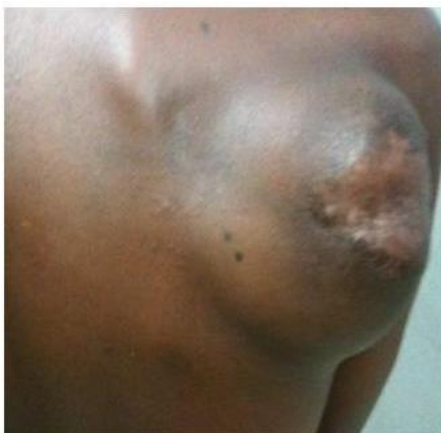
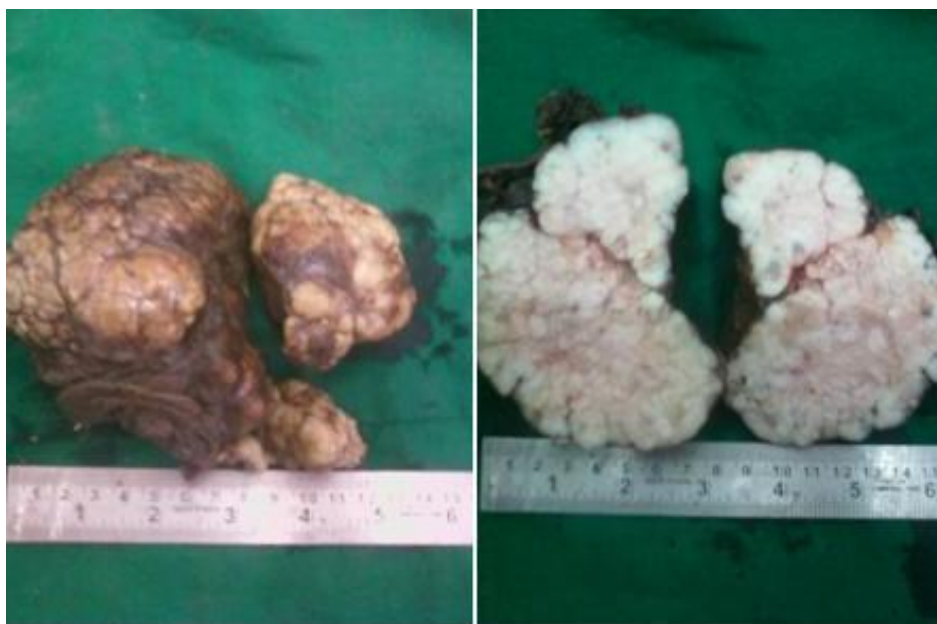
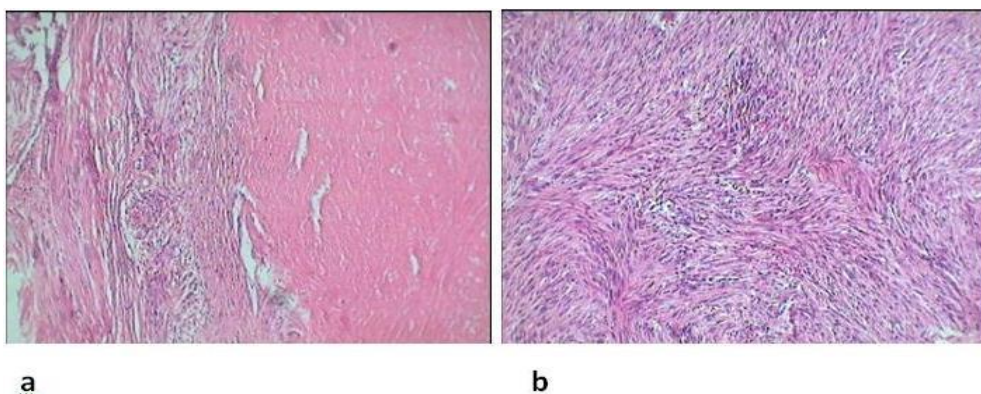
Fig 1: Swelling over right scapular region of size 8x6cm, firm in consistency with restricted mobility and nodular on palpation.



a **b**
Fig 2: Gross specimen measuring 8x7cm, firm in consistency (figure a).Cut section showing well circumscribed lesion, greyish yellow in colour with focal areas of necrosis (figure b).



a **b**
Fig 3: FNAC smears showing highly cellular smears comprising of plump and spindle shaped cells with wavy and tapering nuclei along with focal areas of necrosis (fig a & b. H&E X 40).



a **b**
Fig 4: Histopathology sections showing tumour tissue arranged in whirling pattern comprising of wavy and tapering nuclei along with areas of necrosis(figure a H&E X40).Tumour tissue arranged in whorls and fascicles (fig b H&E X 10).

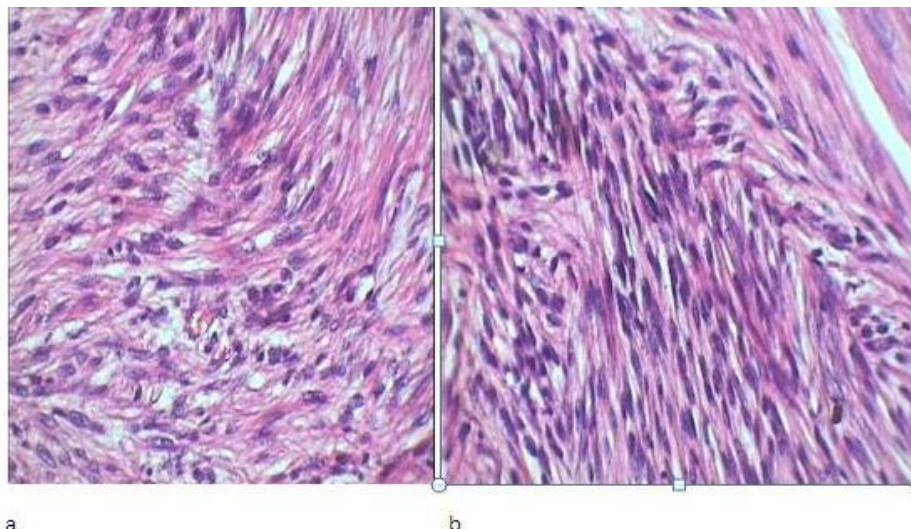


Fig 5: Histopathology sections showing tumour having wavy and tapering nuclei arranged in interlacing fascicles and in whorls having wavy and tapering nuclei (Fig a & b H&E X40).

DISCUSSION

MPNSTs commonly arise in adult patients ranging from 20 to 50 years of age. They originate from a major or minor peripheral nerve branch or its sheath. The common sites of origin include the extremities and trunk usually sciatic nerve, brachial plexus and the sacral plexus. Most cases average more than 5 cm in diameter [2].

In our case, FNAC show high cellularity comprising of plump and spindle shaped cells with wavy and tapering nuclei arranged in whirling pattern and in tight clusters interspersed with epithelioid cells and fibroblasts in a hemorrhagic background. We diagnosed it as low grade MPNST cytologically. On Histopathology multiple bits show tumour tissue arranged in whirling pattern and in fascicles having wavy and tapering nuclei, areas of necrosis also seen along with areas of hemorrhage. Areas of hyper and hypocellularity comprising of plump spindle shaped cells arranged in whirling pattern also noted. We reported it as MPNST.

The definitive diagnosis of MPNST is obtained by biopsy. Metastasis occurs in 39% of patients and 68% die from this tumor [3]. Surgery is the most beneficial treatment, but postoperative radio- and chemotherapy are part of adjunctive therapy [4]. Most MPNSTs are large, fleshy, often necrotic neoplasms that may involve proximal portions of major nerve trunks of the neck, extremities, retroperitoneum, mediastinum, and viscera. Less commonly, intradural nerves are involved. Although MPNSTs can develop in any anatomical region, the sciatic nerve is most often affected [5]. Such tumors usually occur in large nerve trunks in patients with NF1 and are associated with a highly aggressive course of recurrence, metastases, and death in most patients [6].

MPNSTs are fusiform to globular in shape and vary from white and firm to yellow and soft, depending on the absence or presence of necrosis. Although the tumors usually appear well circumscribed, they are not truly encapsulated. The histologic features of MPNSTs are those of a highly cellular, spindle-cell neoplasm resembling a soft-tissue sarcoma, but with differentiation towards elements of the nerve sheath, Schwann cell, and perineural cell⁷. Frequent mitoses and focal necrosis are typical. Metastases occur in 39% of patients [3]. The most common metastatic sites are the lungs, followed in decreasing order of frequency by soft tissue, bone, liver, intra-abdominal cavity, adrenal glands, diaphragm, mediastinum, brain, ovaries, kidneys, and retroperitoneum.

Biopsy is necessary to diagnose an MPNST definitively. The differential diagnosis between benign schwannoma and neuro sarcoma may be challenging: one must look for necrotic foci, the number of atypical mitoses, and an absence of differentiated cells. The treatment of choice is surgery, but postoperative radio- and chemotherapy are part of adjunctive therapy [4]. When radical tumor removal is not possible, excision combined with high-dose radiation therapy seems to be the best alternative treatment. The MPNST is classified into three types – epithelioid, mesenchymal (including Triton tumor) and glandular variants. Immunostaining shows focal staining for S-100, CD57 and Leu-7 and myelin basic protein in 50% of the cases. MPNST in most instances has a poor 5 year survival rate. Treatment is complete surgical excision of the tumor with negative margins along with radiotherapy for best outcome with respect to local recurrence and distant metastases.

REFERENCES

1. Weiss SW, Goldblum JR: Malignant tumors of the peripheral nerves. In Enzinger and Weiss's Soft

- Tissue Tumours. 4th edition. Edited by Strauss M, Grey L. St. Louis: Mosby, Inc; 2001:1209-64.
2. Ducatman BS, Scheithauer BW, Piepgras DG, Reiman HM, Ilstrup DM. Malignant peripheral nerve sheath tumors. A clinicopathologic study of 120 cases. *Cancer*. 1986 May 15; 57(10):2006-21.
 3. Wanebo JE, Malik JM, Vandenberg SR, Wanebo HJ, Driesen N, Persing JA. Malignant peripheral nerve sheath tumors. A clinicopathologic study of 28 cases. *Cancer*. 1993 Feb 15; 71(4):1247-53.
 4. Aguiar VS, Sarrazin D, Henry-Amar M, Spielmann M, Genin J, Bernheim A, Contesso G. Neurosarcoma associated with Von Recklinghausen disease: Apropos of 25 cases observed at the Gustave Roussy Institute from 1967 to 1990. *Bulletin du cancer*. 1991 Dec; 79(1):101-12.
 5. Kchouk M, Rabet AM, Ghedas K, Nagi S, Douik M, Ben RK, Touibi S, Sliman N. Extensive malignant schwannoma of the sciatic nerve. Contribution of imaging techniques. *Journal de radiologie*. 1993 Dec; 74(12):641-4.
 6. Robey SS, Dement SH, Eaton KK, Aoun H. Malignant epithelioid peripheral nerve sheath tumor arising in a benign schwannoma. *Surgical neurology*. 1987 Dec 31; 28(6):441-6.
 7. Chitale AR, Dickersin GR. Electron microscopy in the diagnosis of malignant schwannomas a report of six cases. *Cancer*. 1983 Apr 15; 51(8):1448-61.