

A case study related to the treatment of Esophageal Variceal using β - blocker and a notion of *Helicobacter pylori* infection

Sampath Gattu¹, Sridharan K², Prabhusaran N^{3*}, Kayalvizhi N¹

¹Department of Zoology, Periyar University, Salem, India

²Department of Gastroenterology, Chennai Medical College Hospital and Research Centre (SRM Group), Tiruchirapalli, India [Affiliated to the Tamilnadu Dr. M.G.R. Medical University, Chennai]

³Department of Microbiology, Chennai Medical College Hospital and Research Centre (SRM Group), Tiruchirapalli, India [Affiliated to the Tamilnadu Dr. M.G.R. Medical University, Chennai]

*Corresponding author

Prabhusaran N

Email: leptoprabhu@gmail.com

Abstract: Despite a pronounced reduction of lethality rates due to upper gastrointestinal bleeding, esophageal variceal bleeding remains a challenge to diagnosis. Endoscopic variceal ligation is the definitive treatment of choice for active variceal hemorrhage. The gastric varices get ruptured and it considered as a most critical clinical complications of cirrhosis it leads to variceal hemorrhage. The influence of *H. pylori* in the pathogenesis of cirrhosis patients is rarely diagnosed. Thus, we reported the suspicion towards *H. pylori* infection provided no signals of such infection by microbiological and histopathological analysis were observed. Grade-III-1 column column varices was successful recovered after 3 weeks of six ligation bands deployed on esophageal varices with intake of β - blocker.

Keywords: Esophageal varices, gastrointestinal bleeding treatment, β -Blocker

INTRODUCTION

Gastric variceal hemorrhage is general complication of portal hypertension and is connected with higher rates of morbidity and mortality than hemorrhage of esophageal varices [1]. Endoscopic esophageal variceal ligation is the ultimate treatment of choice for active varices. It is a relatively simple procedure and is associated with fewer complications than endoscopic sclerotherapy [2]. In this study, we reported the recovery of patient after 3 weeks of esophageal ligation. The incidence and prevalence of cirrhosis are found high and considered as an emerging health issue globally. The close associations of altering gastrointestinal mucosa with increased risk of peptic ulcer are also observed [3]. This type of clinical gastropathy was observed with mucosal lesions that cause acute or chronic gastric internal hemorrhage leads to anemia; it is identified and differentiated by endoscopy as mosaic like pattern that resembles like snake skin with or without red spots [4]. This type of patients may explore different pathological mechanisms including elevated serum gastrin that increased acid secretion and blood flow variations [5, 6]. If this clinical condition exists, prostaglandins secretion reduced and leads to *H. pylori* infection. Previous studies suggested knowledge of incidence of *H. pylori* infection in patients with cirrhosis and association with esophageal variceal bleeding may be a better tool to understand the pathogenesis of peptic ulcer and its relative infections [7, 8]. This case report was

documented and it was determined the treatment of esophageal varices by band ligation with β -blocker.

CASE REPORT

A 54 year aged men presented in outpatient Department of Gastroenterology on March, 2017, with right-sided chest pain, abdominal pain, dyspnea and haematemesis was included in this report. Further, the sociodemographic details of the patient were documented as alcohol intake of once a week and an ex-smoker. On that day of visit, the patient was suggested for upper gastro endoscopy, which confirmed the presence of a small amount of altered blood in the stomach, Grade-III-1 column varices Distal 10 cm (Figure 1a) without any stigmata of recent bleeding (fibrin plugs) with red spots. On the same day, suggestion was given to do band ligation, and the patient had willing to do, hence six ligation bands were successfully deployed on oesophageal varices (Figure1b). The correlative diagnosis was made to find out the presence of *H. pylori* was made by direct urease breath test, bacteriological culturing and histopathology revealed absence of fingerprints of *H. pylori* in the case. Then the treatment was started with β -blocker - propranolol for 20mg, once in a day for 3 weeks. The next follow up endoscopy was done after 3 weeks of treatment that revealed the better improvement in the effect of drugs which showed the presence of Grade-1-3 column varices Distal 7 cm (Figure 2) and suggestion was given to the patient to continue the same drug for one more week.

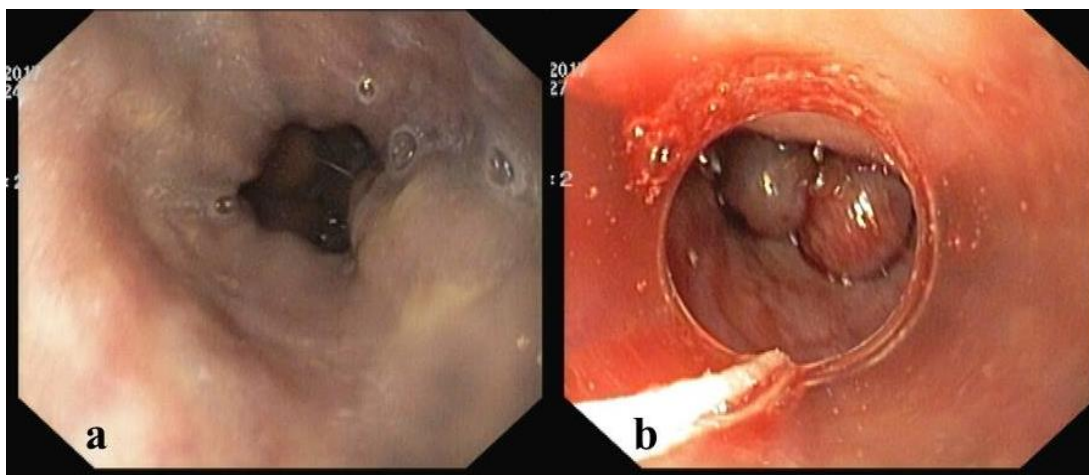


Fig 1: a) Grade III oesophageal varices b) Banding of oesophageal varices ligation

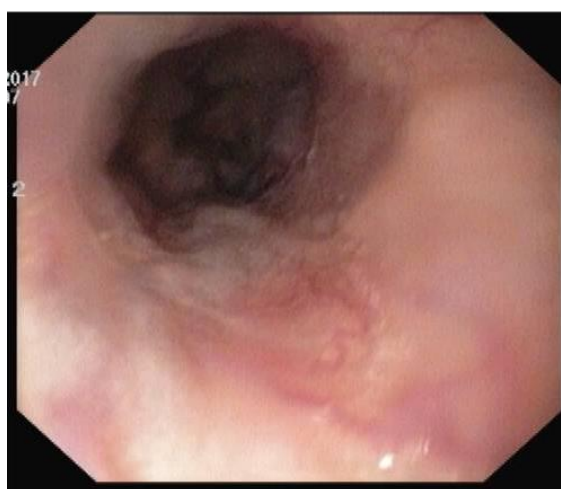

Fig 2: Follow up endoscopy after 3 weeks showed reduced varices to Grade III to Grade I

DISCUSSION

Endoscopic variceal banding works by capturing the varices cause venous occlusion from thrombosis and leading to tissue necrosis. The bands slough off in a few days, leaving a superficial ulceration that rapidly heals [9, 10]. Verities of clinical indications were determined in variceal bleeding including acute hemorrhage, initial prevention in high risk patients and drugs for re bleeding it is a medical emergency were both endoscopic treatment and chemotherapy achieved acute variceal bleeding. Through this therapy a study determined that 97% controlled bleeding and 90% surgery [11]. To controlled as for effective treatment the continues treatment using of β -blockers may reduce the risk in some incidences β -Blockers may develop side effects that leads to treatment dropout [12]. Most of the studies investigated the parable association between *H. pylori* infection and esophageal varices suggested the colonization of *H. pylori* was likely to be the contributing factor for pathogenesis [13]. The endoscopic treatment is having more benefits then other therapeutic indices were as reduction of bleeding while during procedures and minimizing local and systematic complications including fever, pain, ulceration

perforation etc. Thus variceal ligations along with β -Blockers are safe for and improve the probability of life. A relatively wide variations of recurrent bleeding has been observed with ligation may be due to technical insufficiency, more number of bands in each session and multiple band ligation [14, 15, 7]. From this case it was concluded that the combination of endoscopic ligation banding and β -Blocker may be best alternative.

CONCLUSION:

Variceal ligation by endoscopy is an effective and safe when β -Blocker is contraindicated or not tolerance for the prevention of variceal bleeding. However these therapeutic inducers may be effective for the prevention of recurrent bleeding and to reduced variceas grades. Most of the reports suggested to identify the assumption between *H. pylori* infection and esophageal variceas thus repute also warranted to show the presence of *H. pylori* by simple method for the benefits of complete treatment of the patient.

REFERENCES:

1. Trudeau W, Prindiville T. Endoscopic injection sclerosis in bleeding gastric varices.

- Gastrointestinal endoscopy. 1986 Aug 31; 32(4):264-8.
2. Mansour M, Abdel-Aziz Y, Awadh H, Shah N, Ajmera A. Complete Esophageal Obstruction after Endoscopic Variceal Band Ligation in a Patient with a Sliding Hiatal Hernia. ACG case reports journal. 2017; 4.
 3. Sathar SA, Kunnathuparambil SG, Sreesh S, Narayanan P, Vinayakumar KR. Helicobacter pylori infection in patients with liver cirrhosis: prevalence and association with portal hypertensive gastropathy. Annals of gastroenterology. 2014; 27(1):48.
 4. Thuluvath PJ, Yoo HY. Portal hypertensive gastropathy. The American journal of gastroenterology. 2002 Dec 1; 97(12):2973-8.
 5. Sarfeh IJ, Tarnawski A, Malki A, Mason GR, Mach T, Ivey KJ. Portal hypertension and gastric mucosal injury in rats. Effects of alcohol. Gastroenterology. 1983 May; 84(5 Pt 1):987-93.
 6. Sarfeh IJ, Tarnawski A, Maeda R, Raymond K, Mason GR, Ivey KJ. The gastric mucosa in portal hypertension: effects of topical bile acid. Scandinavian journal of gastroenterology. Supplement. 1983 Dec; 92:189-94.
 7. Malaty HM. Epidemiology of *Helicobacter pylori* infection. Best Practice and research clinical Gastroenterology. 2007; 21:205-214.
 8. Pellicano R, Leone N, Berrutti M, Cutufia MA, Fiorentino M, Rizzetto M, Ponzetto A. Helicobacter pylori seroprevalence in hepatitis C virus positive patients with cirrhosis. Journal of hepatology. 2000 Oct 31; 33(4):648-50.
 9. Saltzman JR, Arora S. Complications of esophageal variceal band ligation. Gastrointestinal endoscopy. 1993 Jan 1; 39(2):185-6.
 10. Schmitz RJ, Sharma P, Badr AS, Qamar MT, Weston AP. Incidence and management of esophageal stricture formation, ulcer bleeding, perforation, and massive hematoma formation from sclerotherapy versus band ligation. The American journal of gastroenterology. 2001 Feb 1; 96(2):437-41.
 11. Sarin SK, Sreenivas DV, Lahoti D, Saraya A. Factors influencing development of portal hypertensive gastropathy in patients with portal hypertension. Gastroenterology. 1992 Mar 31; 102(3):994-9.
 12. Lenz HJ, Hogan DL, Isenberg JI. Intestinal phase of gastric acid secretion in humans with and without porta caval shunt. Gastroenterology. 1985 Oct 31; 89(4):791-6.
 13. Yang DH, Huang CC, Yu JL, Song WS, Mao H, Xu c. The relationship between portal hypertensive gastropathy and *Helicobacter pylori* infection. Chinese Journal of Gastroenterology. 1997;5:27-28
 14. Rabinovitz M, Yoo YK, Schade RR, Dinzans VJ, Van Thiel DH, Gavalier JS. Prevalence of endoscopic findings in 510 consecutive individuals with cirrhosis evaluated prospectively. Digestive diseases and sciences. 1990 Jun 1; 35(6):705-10.
 15. Hopkins RJ, Girardi LS, Turney EA. Relationship between Helicobacter pylori eradication and reduced duodenal and gastric ulcer recurrence: a review. Gastroenterology. 1996 Apr 30; 110(4):1244-52.