

---

## Isolated Acute Sphenoid Sinusitis Causing Orbital Apex Syndrome – A Case Report

Vellavedu Umapathy Shanmugam<sup>1</sup>, Arthi Madhu<sup>2</sup>, Ruta Shanmugan<sup>3</sup>, Rajagopalan Mariappan<sup>4</sup>, Balaji Swaminathan<sup>5</sup>, Rajasekaran Prem Nivas<sup>6</sup>

<sup>1</sup>Professor, <sup>2</sup>Post Graduate, <sup>3</sup>Head of the Department, <sup>4</sup>Professor, <sup>5</sup>Reader, <sup>6</sup>Lecturer  
Department of Otorhinolaryngology, Rajah Muthiah Medical College and Hospital (RMMCH), Chidambaram,  
Tamilnadu, India

### \*Corresponding author

Arthi Madhu

Email: [drarthi1203madhu@gmail.com](mailto:drarthi1203madhu@gmail.com)

---

**Abstract:** Isolated inflammatory involvement of the sphenoid sinus is a relatively uncommon entity. Acute sphenoidal sinusitis may present a problem of differential diagnosis in patients with visual disturbances and cranial neuropathies. We report an unusual case of orbital apex syndrome with isolated acute sphenoid sinusitis in a diabetic patient due to dehiscent superolateral wall of the sphenoid sinus.

**Keywords:** Acute sphenoid sinusitis, orbital apex syndrome, dehiscent sphenoid sinus

---

### INTRODUCTION:

Isolated acute sphenoid sinusitis is a rare clinical entity constituting approximately 3% of all sinusitis with potentially devastating clinical consequences, affecting mainly immunocompromised individuals [1]. Orbital apex syndrome is a recognized complication of acute sphenoidal sinusitis characterised by Loss of vision due to optic neuropathy, Ophthalmoplegia, Ptosis and Decreased corneal sensation [2].

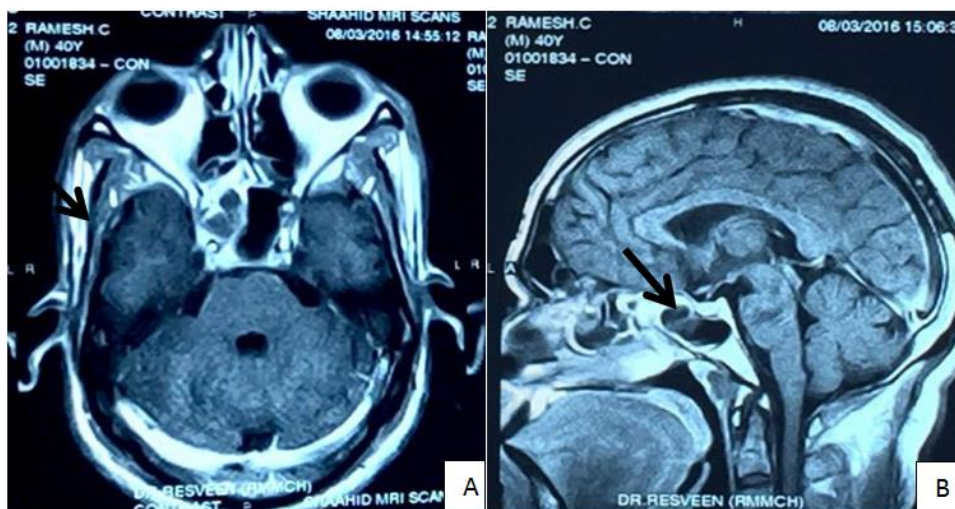
Acute sphenoid sinusitis is a frequently undiagnosed condition because of its nonspecific clinical presentation leading to permanent visual loss. Due to its poor prognosis, a high index of suspicion is necessary in making a prompt diagnosis and institute appropriate intervention. We report an unusual case of orbital apex syndrome due to Isolated Acute Sphenoid Sinusitis in a Diabetic patient due to dehiscent superolateral wall of the sphenoid sinus.

### CASE REPORT:

A 40 years old male, a known case of type 2 diabetes mellitus for the past 2 years on irregular treatment presented to the emergency department with

complaints of headache of one week duration followed by rapidly progressive vision loss and diplopia in the right eye of two days duration. History of one episode of generalized seizures and vomiting was present.

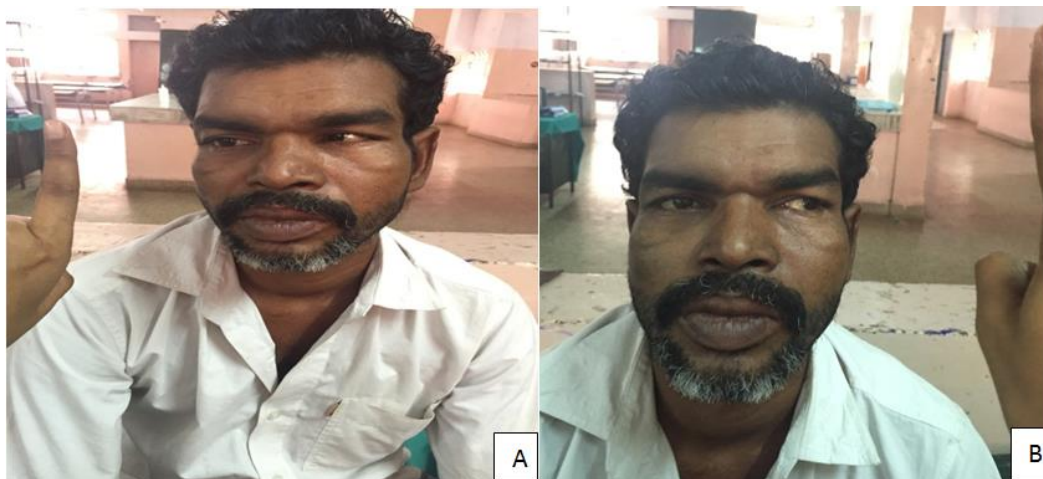On ophthalmic examination, fundus appeared normal. Visual acuity of right eye showed no perception of light with relative afferent pupillary defect. There was restricted eye movements of the right eye on adduction, abduction, elevation and depression due to involvement of oculomotor nerve, trochlear nerve, and abducent nerve. Visual acuity of left eye was 6/6 with pupil reacting normally to light. Laboratory investigations showed random blood sugar of 259 mg/dl, HbA1c was 7.5%, HIV was negative. Other lab parameters were normal. MRI brain showed focal T2/FLAIR cortical hyperintensity with diffusion restriction of right middle frontal gyrus possibly due to acute infarct. MRI brain with contrast showed features of right sphenoidal sinusitis with dehiscent right superolateral wall of sphenoid sinus leading to spread of inflammation to optic canal and orbital apex resulting in optic neuritis and possibly subacute infarct in right middle frontal gyrus.



**Fig 1(A) & (B) pointed in black arrow MRI brain shows right sphenoid sinusitis with orbital apex involvement.**

Patient was treated with inj. Methyl prednisolone IV, inj. pipzo IV, and subcutaneous inj. Human Actrapid. In view of headache, vomiting,

seizures and MRI showing features of subacute infarct of right middle frontal gyrus impending intracranial complication was anticipated here.



**Fig 2: shows restriction of right eye movements (A) on abduction, (B) on adduction**

**DISCUSSION:**

Sphenoid sinus develops in the body of sphenoid bone and it is situated at the junction of anterior and middle cranial fossa. Onset of initial pneumatization of the sphenoid bone varies from 6 months to 4 years and reaches its final form by the age of 12 – 14 years. The sphenoid sinus pneumatization of the pterygoid plates, basiocciput, greater and lesser wing of sphenoid brings it in close relation to vessels and cranial nerves of skull base [3].

Sphenoid sinus communicates with superior nasal meatus by means of a small ostium of 0.5 -4mm , although located unfavourably 10 – 20 mm above the sinus floor [4] this sinus has a good mucociliary clearance. Sphenoid sinus is in close relation to several vital structures like pituitary gland above, apex of the orbit, cranial nerves (II -VI), internal carotid artery and cavernous sinuses laterally [5]. Understanding the

relationship between the intracanalicular optic nerve and posterior group of sinuses is of paramount importance.

There are four types of optic nerve relations with the posterior sinuses. Type 1 (76%) when the nerve runs along the side wall of the sphenoid sinus without producing any indentation on the sinus wall. Type 2 (15%) same as type 1 but causing indentation in the wall of the sinus. Type 3 (6%) when the nerve runs through the sphenoid sinus. Type 4 (3%) when the nerve pass immediately adjacent to the sphenoid sinus and the posterior ethmoid. Type 2 and 3 optic nerve are more prone to get involved in coexistent sphenoid sinus pathology.

Sphenoid sinus is one of the most neglected sinus, with few mucous secreting cells and is associated with fewer drainage problems and hence less incidence

of sphenoid sinusitis. Acute sphenoid sinusitis can lead to orbital apex syndrome, blindness, cavernous sinus thrombosis, cranial nerve palsies (most commonly abducent nerve) [6], meningitis, epidural abscess, subdural abscess and cerebral infarction.

Isolated sphenoid sinusitis causing orbital apex syndrome is a very rare occurrence with the most common presentation being headache followed by visual disturbances. It is common in immunodeficient individuals with diabetes mellitus, alcoholism and on steroid therapy [7, 8]. Orbital apex syndrome involves damage to oculomotor nerve, trochlear nerve, abducent nerve and ophthalmic division of trigeminal nerve in addition to optic nerve dysfunction [9].

The incidence of visual loss in isolated sphenoid sinus disease is 12% of inflammatory cases and 60% of neoplastic cases. There are various theories of visual compromise (a) direct spread of the sinus infection and inflammation to the optic nerve through dehiscent optic canal ;(b) compressive optic neuropathy due to expansile or mass lesion in posterior ethmoid and sphenoid sinus; (C) vasculitis with thromboangitis of the optic nerve ;(d) bacteremia's resulting from the passage of infection through the mucosa of the sinus.

In our case visual loss was due to spread of inflammation to orbital apex due to dehiscent superolateral wall of the sphenoid sinus. Patients with severe symptoms of acute sphenoid sinusitis are treated with intravenous antibiotics and methylprednisolone. Emergency endoscopic sphenoidotomy is the best surgical approach which can result in reversal of vision loss. Permanent blindness is reported in 10% of patients with acute sphenoiditis. Poor prognosis may be due to delayed presentation, preexisting lateral sphenoid bony dehiscence, advanced tissue invasion, inappropriate use of corticosteroids and possible misdiagnosis. Hence otolaryngologist must have a thorough knowledge of the anatomy, radiology and clinical spectrum of sphenoid sinus disease to evaluate and manage these patients properly. Although this case was primarily treated by general physician and ophthalmologist as optic neuritis, ENT assistance was sought in view of the worsening unilateral visual symptoms and positive finding in sphenoid sinus on MRI.

#### CONCLUSION:

Sphenoid sinus disease must be contemplated as a possible diagnosis in all cases of retrobulbar neuritis. This case highlights the diagnostic challenge of sphenoid sinusitis with orbital apex syndrome and the importance of effective early collaboration and combined management between general physician, otorhinolaryngologist and ophthalmologist to achieve best outcomes in this often grave disease.

#### REFERENCES:

1. Verma RK, Panda NK. Bilateral Blindness Due to Acute Isolated Sphenoid Sinusitis-Is It Reversible? A Case Report. *Journal of Medicine*. 2014 Oct 21; 15(2):146-8.
2. Cho SH, Jin BJ, Lee YS, Paik SS, Ko MK, Yi HJ. Orbital apex syndrome in a patient with sphenoid fungal balls. *Clinical and experimental otorhinolaryngology*. 2009 Mar 26; 2(1):52-4.
3. Budu V, Mogoantă CA, Fănuță B, Bulescu I. The anatomical relations of the sphenoid sinus and their implications in sphenoid endoscopic surgery. *Rom J Morphol Embryol*. 2013 Jan 1; 54(1):13-6.
4. Rajiniganth MG, Usha R Kim, Mahesh Kumar. Coexistent optic neuritis and isolated acute sphenoid sinusitis. *An International Journal*, 2009 Sep-dec; 2(3):47-50.
5. Lee DH, Yoon TM, Lee JK, Joo YE, Park KH, Lim SC. Invasive fungal sinusitis of the sphenoid sinus. *Clinical and experimental otorhinolaryngology*. 2014 Sep; 7(3):181.
6. Ceylan K, Kizilkaya Z, Emir H, Samim E. An Unusual Presentation for 6th Nerve Palsy: isolated Chronic Sphenoid Sinusitis and Bilateral Abducens Palsy. *The Internet Journal of Otorhinolaryngology*. 2006; 6(1).
7. Singh H, Kandel R, Nisar S, Das CJ, Dey AB. An unexpected cause of orbital apex syndrome in an immune-competent elderly male. *Oxford Medical Case Reports*. 2014 Sep 1; 2014(6):115-7.
8. Thanikachalam Subramanian, Rajesh Singh, Karunanidhi Manikam, Jagadeeswaran Vadivel Udayakumran, Neeta Pal, Namrata Pal And Govind Pal. Orbital Apex Syndrome in a patient with Sphenoethmoidal Fungal Sinusitis. *J clin case Rep* (2015); 5:566.
9. Yeh S, Foroozan R. Orbital apex syndrome. *Current opinion in ophthalmology*. 2004 Dec 1; 15(6):490-8.