

Granulomatous mastitis masquerading as breast carcinoma

Dr Sumiti Gupta, Dr Megha Kathuria, Dr Rajnish Kalra, Dr Meenu Gill, Dr Padam Parmar, Dr Rajeev Sen

Department of Pathology, Pt. BD Sharma PGIMS, Rohtak, Haryana, INDIA

*Corresponding author

Dr. Megha Kathuria

Email: mkathuria27@gmail.com

Abstract: Granulomatous mastitis is a rare inflammatory disease of the breast with no known etiology. It presents most commonly with a palpable mass and erythematous skin. Often, the initial diagnosis offered clinically is breast malignancy. A definitive diagnosis can be attained with meticulous histopathological examination and microbiological investigation. We report a case of 60 year woman who presented with lump breast. A thorough histopathological and other investigations helped to arrive at the diagnosis of granulomatous mastitis and thus, prevented a major invasive surgery.

Keywords: Mastitis, granulomatous

INTRODUCTION

Granulomatous mastitis (GM) is a rare chronic inflammatory disease of the breast of unknown etiology. It can mimic breast cancer both clinically and radiologically[1]. The most common initial presentation is a palpable mass with erythematous skin changes. Other clinical symptoms include pain, sterile abscesses, fistula and nipple retraction[2]. Regional lymphadenopathy may be found in up to 15% of cases. In more than 50% of the reported cases, the initial diagnosis considered is malignant or suspicious for breast carcinoma[3]. GM is a benign condition and is important to be considered as a diagnosis to avoid invasive surgery. We report here a case of granulomatous mastitis in an elderly postmenopausal woman.

CASE REPORT

A 60-year woman presented with a 3-month history of lump in her right breast associated with pain and not responding to antibiotics. The patient had no family history of breast cancer, previous use of oral contraceptives, any recent breast trauma. There was no previous history of tuberculosis and fever. Blood investigations, including complete hemogram and ESR, were within normal limits.

On clinical examination the lump was 3 x 2.5 cm in size, firm to hard in consistency, partially mobile

in lower outer quadrant of right breast. There was no associated nipple discharge or skin sinus. No axillary lymph nodes were palpable. Mammography report showed microcalcification and ultrasound findings were suggestive of malignancy.

Fine needle aspiration cytology (FNAC) was done which yielded blood mixed aspirate. The smears were moderately cellular comprising groups, sheets and papillary clusters of ductal epithelial cells revealing moderate atypia along with inflammatory cells, multinucleated giant cells and epithelioid cell granulomas. The background showed amorphous debris, stripped nuclei and RBCs. The FNA smears were suggestive of granulomatous inflammation with moderate atypia in ductal epithelial cells. However, ZiehlNeelsen staining with 20% H₂SO₄ for acid fast bacilli was negative. A surgical biopsy was advised. (Figure 1,2)

Biopsy revealed aggregates of epithelioid histiocytes, ill-defined epithelioid granulomas, multinucleate giant cells, surrounded by inflammatory infiltrate consisting of lymphocytes and plasma cells along with granulation tissue fragments. ZiehlNeelsen stain for acid fast bacilli was negative. (Figure 3). Hence, a final diagnosis of granulomatous mastitis was considered.

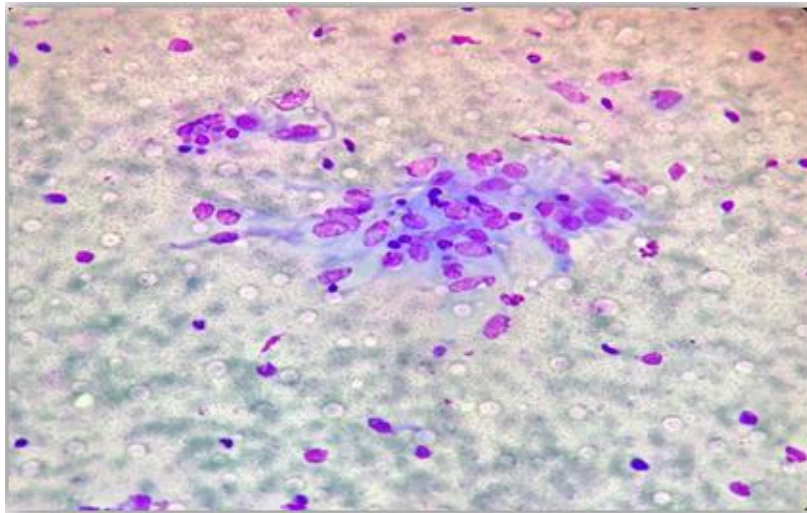


Fig-1: FNA lump breast showing papillary cluster of ductal epithelial cells with moderate atypia (Leishman, 400x)

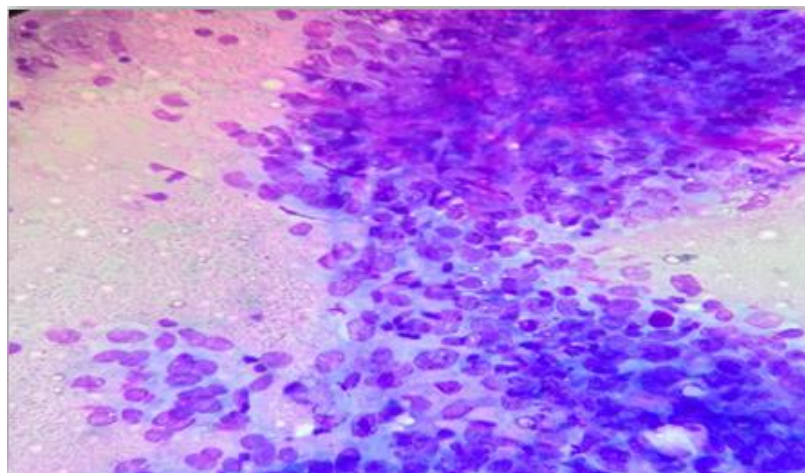


Fig-2: FNA lump breast showing epithelioid cell granuloma (Leishman, 400x)

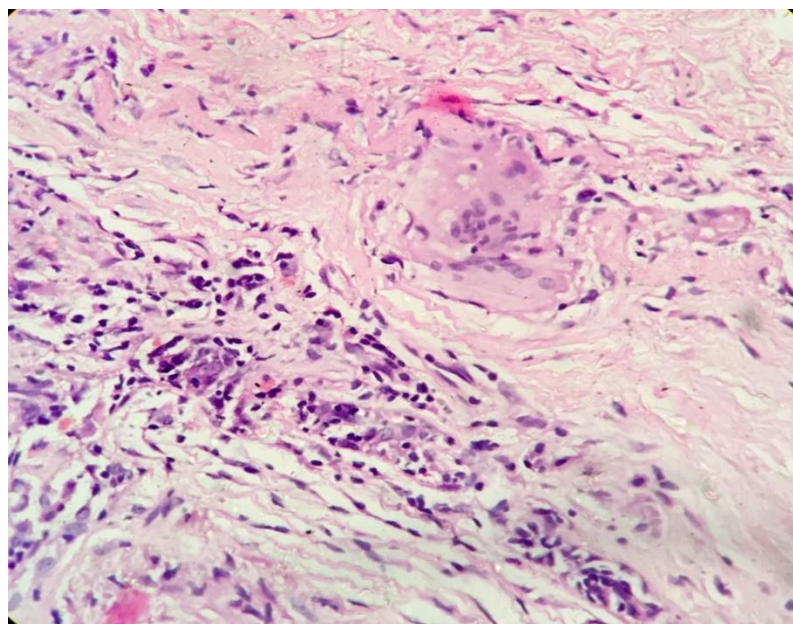


Fig-3a: HE stained section shows breast tissue along with epithelioid cell granuloma (400x)

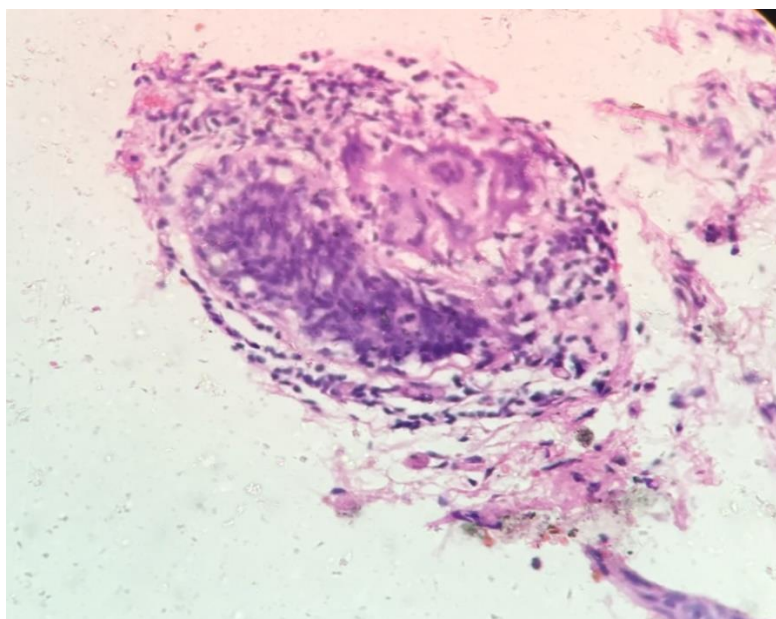


Fig-3b: HE stained section shows breast tissue along with epithelioid cell granuloma (400x)

DISCUSSION

Idiopathic Chronic Granulomatous mastitis is an uncommon benign breast lesion. It was first described by Kessler and Woolloch[4]. The disease usually is found in women of reproductive age. It may be associated with lactation or may occur in the postpartum period[5]. It most commonly affects women of age group 22 - 42 years. However, cases have been reported in perimenopausal and postmenopausal age group as well[6,7,8].

Idiopathic Granulomatous mastitis is a rare, chronic, noncaseating, granulomatous lobulitis. It mimics breast cancer clinically as well as radiologically. Hence, frequently mistaken for a malignancy, especially if the regional lymph nodes are enlarged[9]. It is known for its worrisome clinical presentation as a hard breast lump. The etiology in most of the cases is idiopathic, and has to be distinguished from the specific granulomatous diseases like tuberculosis, sarcoidosis, and Wegener's granulomatosis.

GM is a disease that involves the breast in an isolated fashion. Its mechanism of development includes ductal epithelial damage, transition of luminal secretions into lobular connective tissue, local inflammation followed by macrophage and lymphocyte migration, and then local granulomatous inflammatory response. Some of the trigger factors include pregnancy, lactation, hyperprolactinemia, oral contraceptive use, local trauma to the breast, alpha-1 antitrypsin deficiency, local irritants, smoking, diabetes mellitus etc[10].

GM most commonly presents as a unilateral breast mass, which in most patients is fixed, immobile and non-tender. On mammography, it is found to give

an asymmetric increase in density. The main differential diagnosis, therefore, is carcinoma breast[7]. The lesion could be located in any quadrant of the breast except the subareolar region. Axillary lymph nodes usually are not enlarged[2].

The cytological features of GM are characterized by aggregates of epithelioid histiocytes, multinucleate giant cells, lymphocytes, plasma cells and neutrophils[11]. A definite diagnosis is secured on histopathological examination. Histology shows epithelioid and multinucleated giant cell granulomas which is limited to the mammary lobules with microabscesses[12]. Combined cytological features seen in aspiration material with histopathological examination led us to favor the diagnosis of GM.

Surgery has been the mainstay of treatment but medical management has been reported with patients put on oral prednisolone once an infective etiology has been excluded. In patients undergoing surgery delayed wound healing, cosmetic problems and recurrence of the disease may complicate the post-operative period. In patients with recurrence after biopsy or delayed wound healing, reexcision and a short therapy of high-dose steroids can be efficient[3].

CONCLUSION

Granulomatous mastitis can mimic breast carcinoma both clinically and radiologically. Cytological diagnosis is difficult due to lack of specific features. A definite diagnosis depends on histopathological examination and exclusion by microbiological investigations. An awareness of this entity is required by the pathologist to avoid any major invasive surgery.

DECLARATION

The authors have no disclosures.

CONFLICTS OF INTEREST

None

REFERENCES

1. Diesing D, Axt-Flidner R, Hornung D, Weiss JM, Diedrich K, Friedrich M. Granulomatous mastitis. Arch Gynecol Obstet. 2004;269:233-6.
2. Pistolesi CA, Trapano RD, Girardi V, Costanzo E, Poce ID, Simonetti G. An unusual case of bilateral granulomatous mastitis. Case Reports in Radiology. 2013; <http://dx.doi.org/10.1155/2013/694697>
3. Bakaris S, Yuksel M, Ciragil P, AtahanGüven M, Ezberci F, Bulbuloglu E. Granulomatous mastitis including breast tuberculosis and idiopathic lobular granulomatous mastitis. Can J Surg. 2006;49:427-30.
4. Kessler E, Woolloch Y. Granulomatous mastitis: a lesion clinically simulating carcinoma. Am J ClinPathol 1972;58:642-6.
5. Tse GMK, Poon CSP, Law BKB, Pang LM, Chu WCW, Ma TKF. Fine needle aspiration cytology of granulomatous mastitis. J ClinPathol. 2003;56:519-21.
6. Lai EC, Chan WC, Ma TK, Tang AP, Poon CS, et al. The role of conservative treatment in idiopathic granulomatous mastitis. Breast J. 2005;11:454-6.
7. Rubin G, Meerkotter DA. Idiopathic granulomatous mastitis. SA journal of radiology. 2011:4-5.
8. Sakurai T, Oura S, Tanino H, Yoshimasu T, Kokawa Y, Kinoshita T, Okamura Y. A case of granulomatous mastitis mimicking breast carcinoma. Breast Cancer. 2002;9(3):265-8.
9. Fletcher A, Magrath IM, Riddll RH, Talbot IC. Granulomatous mastitis: a report of seven cases. J ClinPathol 1982;35:941-5.
10. Schelfout K, Tjalma WA., Cooremans ID, Coeman DC, Colpaert CG, Buytaert PM. Observations of an idiopathic granulomatous mastitis. ur J ObstetGynaecolReprod Biol. 2001;97:260-2.
11. Heer R, Shrimankar J, Griffith CD (2003) Granulomatous mastitis can mimic breast cancer on clinical, radiological or cytological examination: a cautionary tale. Breast 12: 283-6.
12. Miranda J, Marina L, LakymeP, Alexandre P, Leydiane L. Granulomatous mastitis- A rare disease that mimic breast cancer. SIS Journal. 2012;3:1.