

Optical coherence tomography findings in a patient with transplant-associated thrombotic microangiopathy

Shinji Makino

Department of Ophthalmology, Jichi Medical University, Shimotsuke, Tochigi 329-0498, Japan

***Corresponding author**

Shinji Makino

Email: makichan@jichi.ac.jp

Abstract: A 36-year-old man was referred to the ophthalmology unit for blurring of vision in both eyes. A diagnosis of acute lymphoblastic leukemia was made in the patient at the age of 35 years. Treatment with combined chemotherapy achieved a complete remission. The patient received an allogeneic bone marrow transplant from an HLA-identical donor. On examination, his best-corrected visual acuity was 0.3 in the right eye and 0.04 in the left eye. Retinal examination revealed multiple cotton wool spots and superficial hemorrhages around the optic discs of both eyes with serous retinal detachment. Optical coherence tomography of the macular area confirmed the presence of serous retinal detachment we diagnosed the condition as a Purtscher-like retinopathy caused by transplant-associated thrombotic microangiopathy. We suggest that it is worthwhile to examine the eyes of patients with suspected transplant-associated thrombotic microangiopathy to aid the diagnosis.

Keywords: Transplant-associated thrombotic microangiopathy, Purtscher-like retinopathy, Optical coherence tomography

INTRODUCTION

Hematopoietic stem cell transplantation has been commonly used as a potentially curative option for treating various hematological malignancies [1]. However, it may cause serious complications of various systems, including the hemostatic system [1]. Hematopoietic stem cell transplantation-related thrombotic complications are classified into the following four groups: venous thromboembolic events, catheter-induced thrombosis, transplant-associated thrombotic microangiopathy, and sinusoidal obstruction syndrome or veno-occlusive disease [1]. Transplant-associated thrombotic microangiopathy is a type of thrombotic microangiopathy, which also includes conditions such as hemolytic uremic syndrome and thrombotic thrombocytopenic purpura [1-6].

Various ophthalmic features have been described in patients with thrombotic thrombocytopenic purpura [7-10], but reports describing ophthalmic features with transplant-associated thrombotic microangiopathy are extremely rare [11-13]. Herein, we report a case of transplant-associated thrombotic microangiopathy in a 36-year-old man.

CASE REPORT

A 36-year-old man was referred to the ophthalmology unit for blurring of vision in both eyes.

A diagnosis of acute lymphoblastic leukemia was made in the patient at the age of 35 years. Treatment with combined chemotherapy achieved a complete remission. The patient received an allogeneic bone marrow transplant from an HLA-identical donor. Cyclosporine and short-term methotrexate were administered to prevent the development of graft-versus-host disease. Successful engraftment was achieved, and the patient did not develop any signs of acute or chronic graft-versus-host disease. Six months after bone marrow transplant, the patient experienced blurred vision. The patient exhibited hemolytic anemia with red cell fragmentation, thrombocytopenia, elevated lactate dehydrogenase level, and renal impairment. Thus, he was highly suspected of having developed transplant-associated thrombotic microangiopathy. On examination, his best-corrected visual acuity was 0.3 in the right eye and 0.04 in the left eye. Slit-lamp biomicroscopy of the anterior segment and ocular pressure were normal in both eyes. Retinal examination revealed multiple cotton wool spots and superficial hemorrhages around the optic discs of both eyes with serous retinal detachment (Figure 1A, B). Optical coherence tomography of the macular area confirmed the presence of serous retinal detachment (Figure 2A, B).

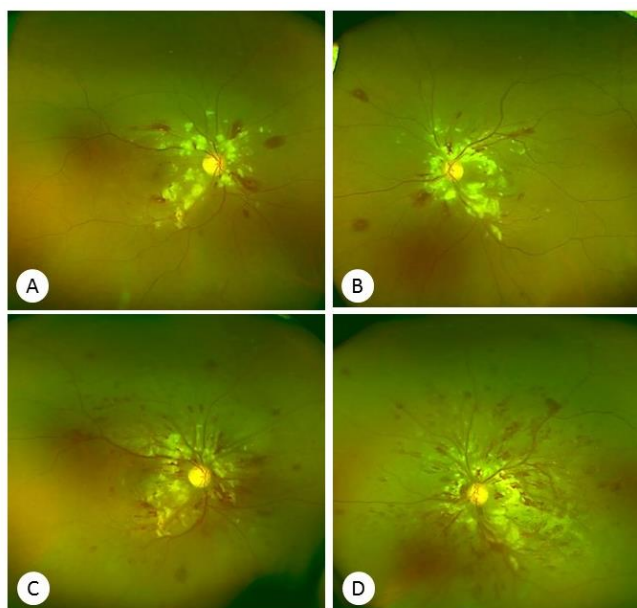


Fig 1: Ultra-wide field imaging of the right (A, C) and left (B, D) eyes revealing cotton wool spots and retinal hemorrhages with macular edema. (A, B: at the initial visit; C, D: 2 weeks later)

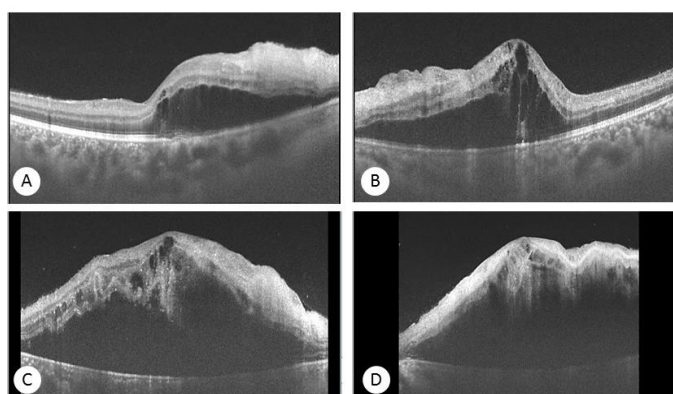


Fig 2: Optical coherence tomographic images of the right (A, C) and left (B, D) eyes revealing marked serous retinal detachment in both eyes. (A, B: at the initial visit; C, D: 2 weeks later)

Therefore, we diagnosed the condition as a Purtscher-like retinopathy with serous retinal detachment caused by transplant-associated thrombotic microangiopathy. Although intensive treatment including plasma exchange, multiple transfusions of fresh frozen plasma were administered together with eculizumab, the fundoscopic findings deteriorated rapidly (Figure 1C, D and Figure 2C, D), and his visual acuity was simultaneously declined to hand motion in both eyes. One month after the initial visit, his visual acuity was no light perception in both eyes. Retinal examination demonstrated marked serous retinal detachment with retinal hemorrhages and soft exudates (fundus photography could not be performed because of the patient’s extremely poor general condition). The patient died three days after the final examination.

DISCUSSION

Transplant-associated thrombotic microangiopathy represents a life-threatening complication following hematopoietic stem cell transplantation [1-6]. It

presents with thrombocytopenia, hemolysis, acute renal failure, mental status changes, and involvement of other organs, as seen in other thrombotic microangiopathies. In general, organ injury is caused by the release of inflammatory cytokines that activates platelets and coagulation factors, which leads to thrombosis and fibrin deposition [1]. The mortality rate reaches up to 100% if no treatment is administered [1]. Monitoring of blood pressure, hemogram findings, and lactate dehydrogenase levels is essential. Transplant-associated thrombotic microangiopathy may lead to significant morbidity and mortality in the post-hematopoietic stem cell transplantation setting and require prompt diagnosis, supportive care, and appropriate treatment.

This report presents a case of Purtscher-like retinopathy with serous retinal detachment. The term “Purtscher retinopathy” implies a traumatic etiology, whereas the term “Purtscher-like retinopathy” suggests non-traumatic causes [14]. Leukoembolization as a cause of embolic retinal occlusion has been proposed as

a potential pathogenic mechanism in Purtscher-like retinopathy [14-16]. Ramos de Carvalho *et al.*; [15] reported a case of Purtscher-like retinopathy secondary to atypical hemolytic uremic syndrome. Nautiyal *et al.*; [16] reported a case of Purtscher-like retinopathy in a patient with multiple myeloma. In the present case, retinal examination demonstrated intraretinal hemorrhages, cotton-wool spots, and serous retinal detachment, which were presumably attributable to multiple thromboses of retinal microvessels. To the best of our knowledge, this is the second documented case of Purtscher-like retinopathy in a patient with transplant-associated thrombotic microangiopathy.

CONCLUSIONS

Although our findings were based on a single case, Purtscher-like retinopathy with serous retinal detachment can be one of the most important presentations of transplant-associated thrombotic microangiopathy. In general, early diagnosis of transplant-associated thrombotic microangiopathy is considered to be difficult. We suggest that it is worthwhile to examine the eyes of patients with suspected transplant-associated thrombotic microangiopathy to aid the diagnosis.

DISCLOSURE

The authors declare no conflict of interest.

REFERENCES

1. Sahin U, Atilla PA, Atilla E, Toprak SK, Demirer T. An overview of hematopoietic stem cell transplantation related thrombotic complications. *Critical reviews in oncology/hematology*. 2016 Nov 30; 107:149-55.
2. Gavriilaki E, Sakellari I, Anagnostopoulos A, Brodsky RA. Transplant-associated thrombotic microangiopathy: opening Pandora's box. *Bone Marrow Transplantation*. 2017 Mar 13.
3. Jodele S, Zhang K, Zou F, Laskin B, Dandoy CE, Myers KC, Lane A, Meller J, Medvedovic M, Chen J, Davies SM. The genetic fingerprint of susceptibility for transplant-associated thrombotic microangiopathy. *Blood*. 2016 Feb 25; 127(8):989-96.
4. Rosenthal J. Hematopoietic cell transplantation-associated thrombotic microangiopathy: a review of pathophysiology, diagnosis, and treatment. *Journal of Blood Medicine*. 2016; 7:181.
5. Reynolds JC, Agodoa LY, Yuan CM, Abbott KC. Thrombotic microangiopathy after renal transplantation in the United States. *American journal of kidney diseases*. 2003 Nov 30; 42(5):1058-68.
6. Noris M, Remuzzi G. Atypical hemolytic-uremic syndrome. *New England Journal of Medicine*. 2009 Oct 22; 361(17):1676-87.
7. Titah C, Abisror N, Buffet M, Coppo P. Bilateral serous detachment of retina: an unusual mode of revelation of thrombotic thrombocytopenic purpura of favorable outcome with plasma exchange. *Graefes Archive for Clinical and Experimental Ophthalmology*. 2014 Jan 1; 252(1):181-3.
8. Tajunisah I, Patel DK, Subrayan V. Purtscher retinopathy as an initial presentation of thrombotic thrombocytopenic purpura. *Journal of thrombosis and thrombolysis*. 2010 Jul 1; 30(1):112-3.
9. Ong T, Nolan W, Jagger J. Purtscher-like retinopathy as an initial presentation of thrombotic thrombocytopenic purpura: a case report. *Eye*. 2005 Mar 1; 19(3):359-61.
10. Bobbio-Pallavicini E, Porta C, Brocchieri A, Saporiti A, Tacconi F. Ocular involvement in acute thrombotic thrombocytopenic purpura. *HAEMATOLOGICA-PAVIA THEN ROMA*. 1995 Jan 1;80:194-.
11. Coskuncan NM, Jabs DA, Dunn JP, Haller JA, Green WR, Vogelsang GB, Santos GW. The eye in bone marrow transplantation: VI. Retinal complications. *Archives of ophthalmology*. 1994 Mar 1; 112(3):372-9.
12. Nakai K, Tajima K, Kishimoto Y, Katsura K, Kawamura M, Yamamoto Y, Hanada M, Zen K, Amakawa R, Fujimoto M, Fukuhara S. Bone marrow transplantation-associated thrombotic microangiopathy manifested by visual disturbance. [Rinsho ketsueki] *The Japanese journal of clinical hematology*. 2000 Jan; 41(1):25-31.
13. Mohsin N, Nooyi C, Jha A, Budruddin M, Kamble P, Khalil M, Pakkyarra A, Mohammed E, Ahmed H, Daar A. Retinal Injury as an Early Manifestation of Posttransplant Thrombotic Microangiopathy: Recovery With Plasma Exchanges and Conversion to Sirolimus—Case Report and Review of the Literature. In *Transplantation proceedings 2007 May 31 (Vol. 39, No. 4, pp. 1272-1275)*. Elsevier.
14. Agrawal A, McKibbin MA. Purtscher's and Purtscher-like retinopathies: a review. *Survey of ophthalmology*. 2006 Apr 30; 51(2):129-36.
15. de Carvalho JR, Schlingemann RO, Oranje M, Bemelman FJ, van Schooneveld MJ. Reversal of threatening blindness after initiation of eculizumab in Purtscher-like retinopathy secondary to atypical hemolytic uremic syndrome. *International Ophthalmology*: 1-9.
16. Nautiyal A, Amescua G, Jameson A, Gradowski JF, Hong F, Doft B. Sudden loss of vision: Purtscher retinopathy in multiple myeloma. *Canadian Medical Association Journal*. 2009 Dec 8; 181(12):E277.