

Unilateral Condylar Hyperplasia with Progressive Facial Asymmetry: A Case Report

Rana Divya^{1*}, Narula Arjun²

¹Senior Resident, Department of Dentistry, Sawai Man Singh Medical College & Hospital, Jaipur, Rajasthan, India

²Senior Resident, Department of Radiodiagnosis, PGIMER, Chandigarh, India

*Corresponding author

Rana Divya

Article History

Received: 04.09.2017

Accepted: 09.09.2017

Published: 30.09.2017

DOI:

10.36347/sjmcr.2017.v05i09.019



Abstract: Condylar hyperplasia of mandible is overdevelopment of condyle, unilaterally or bilaterally, because of excessive cellular growth of one condylar part of the mandible, leading to facial asymmetry, mandibular deviation, malocclusion and articular dysfunction.

Keywords: Facial asymmetry, unilateral Condylar hyperplasia, UCH.

INTRODUCTION

Condylar hyperplasia (CH) is a rare malformation, of non-neoplastic origin, causing change in size and morphology of one of the two mandibular condyles [1]. The enlargement of condyle is usually unilateral and generally observed in patients between 10 and 30 years of age [2].

Unilateral condylar hyperplasia is generally characterized by facial asymmetry, mandibular deviation and enlargement of condyle. The elongation of the condylar neck in turn leads to unilateral elongation of face on the affected side with deviation of the chin to the contra lateral side, malocclusion and articular dysfunction causing TMJ problems. The facial asymmetry during the growth age may lead to slanting of occlusion while posterior open bite becomes conspicuous after completion of growth [3].

Unilateral condylar hyperplasia must be differentiated from other states of overdevelopment like hemifacial hypertrophy, unilateral macrognathia, laterognathia, and tumors like Chondroma and osteochondroma [3].

The disorder is self-limiting, but as long as it remains active, the asymmetry progresses together with the associated occlusal changes [4]. The etiology of the unilateral hyperplasia of the condyle is still under discussion and varies from case to case. As per the literature, there are several obvious causes of mandibular asymmetry: local circulatory problems, endocrine disturbances, traumatic lesions and arthrosis are considered to be etiologic factors of this pathology [2, 4].

CASE REPORT

A 22-year-old male patient reported with the complaint of gradually developing asymmetry of the right side of the face for past 1 year (Figures 1 and 2). There was no history of trauma, any systemic diseases, infection, or surgery of the face and jaws. Dental history revealed RCT and crown placement, one year back in 46 tooth.

His history revealed developing asymmetry of the right side of the face along with inefficient chewing which he had noticed himself. Mandibular deviation toward the left side and overgrowth were noticed over a period of 1 year which was progressive in nature and progressed slowly and reached its present proportion. Patient also complained about deviation on mouth opening towards the left along with occasional joint sounds, but did not have any difficulty in opening the mouth and mouth opening was adequate.

On clinical examination, facial asymmetry was evident with elongation of lower half of right side of the face as compared with the left side and a significant deviation of chin to the contralateral side and slight downward tilt in lip line toward the right side. The fullness of the face on the right side and flattening on left side was seen. (Figure-1) No pain or tenderness was elicited in the temporomandibular region on palpation, but occasional clicking sounds were noted on repeated examination.

Intraoral examination revealed slight shift of the mandibular midline toward the left side (Figure-3), angles class III molar relation on the right, edge to edge bite in relation to central and lateral incisors and crossbite on the left (contralateral) side starting from the

canine region. Fractured restoration in 16, crown in 26 and 46 were also noted.

Panoramic view (Figure 4), revealed symmetrical condylar enlargement of the right side as compared to the left side and elongated condylar neck along with slight backward tilting of the left condylar head and neck. Tooth 18 was a microdont and 28, 38 and 48 were impacted. Tooth 16 was restored and 26, 46 were endodontically treated with crown prosthesis.

Computed tomography showed differences in the size of both condylar heads. The right condyle

measured 20mm in length as compared to left condyle which was 15mm in length. Also increase in width and elongation of the neck of the right condyle was seen. It was noted that antero-superior surface of the mandible was positioned against the posterior surface of the mandibular fossa which caused TMJ problems to the patient [Figures 5 and 6]. Clinical and radiographic findings were consistent with a diagnosis of unilateral CH of the right side.

In our case, the suggested plan of treatment was high condylectomy of the right condyle followed by a postsurgical orthodontic correction.

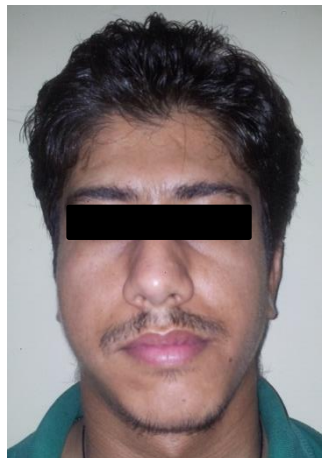

Fig-1: facial asymmetry with elongated right side of the face.

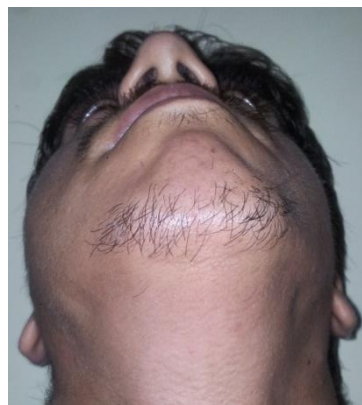

Fig-2: deviation of chin to the left side

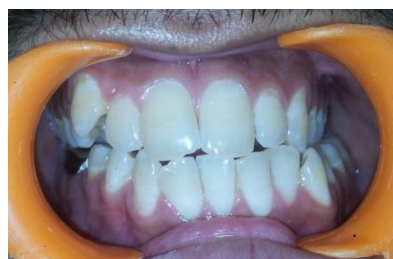

Fig-3: showing midline shift towards left and posterior crossbite

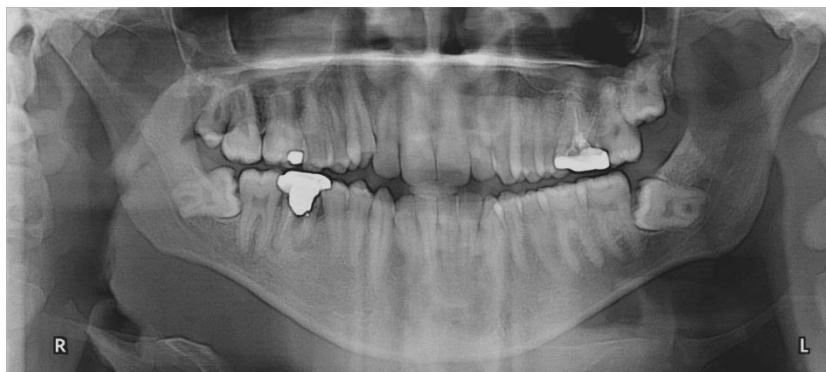


Fig-4: showing enlarged right condyle and elongated condylar neck

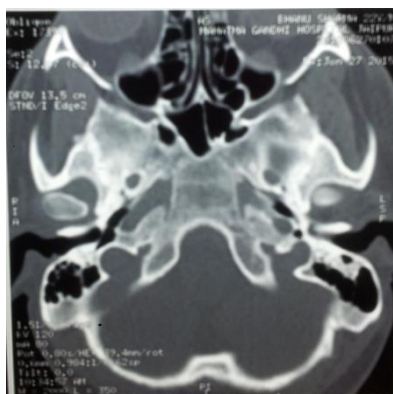


Fig-5: axial section showing enlarged right condyle

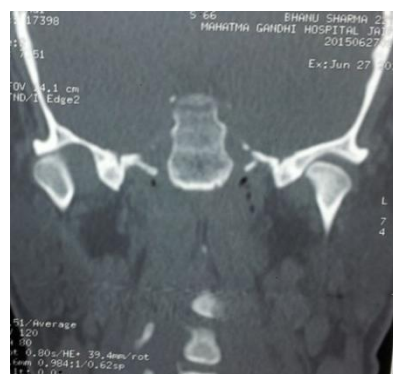

Fig-6: coronal section showing compensatory changes of unilateral right condylar hyperplasia as the condyle is posteriorly placed in the articular fossa

DISCUSSION

Condylar hyperplasia of the mandible is a clinical condition of over-development and growth because of excessive cellular growth of one condylar part of the mandible [1].

Unilateral condylar hyperplasia must be differentiated from other states of overdevelopment like hemifacial hypertrophy which is characteristic of unilateral enlargement and three dimensional growth of all hard and soft tissues of face, unilateral macrognathia which shows unilateral mandibular hypertrophy, which is a three dimensional enlargement of mandible, including both condyles, ramus and ends at midline of symphysis and laterognathia causing asymmetrical prognathism where both condyles are equal in size, and

Chondroma and Osteochondroma which may also produce similar symptoms and signs, but they grow more rapidly and may cause even greater asymmetric condylar enlargement [3, 5].

There are several documented causes of mandibular asymmetry such as trauma with fracture, tumors, and congenital anomalies. However, additional factors like hormonal influences, hypervascularity, heredity, infection or trauma may also stimulate this excess growth of condyle. In many cases, however, the cause of mandibular asymmetry leading to facial deformity remains unclear on clinical examination [1, 3]. In the present case also, no evident cause of UCH was found.

Major characteristics of unilateral condylar hyperplasia are deviation of the chin and of the lower dental midline to the opposite side, contralateral crossbite and ipsilateral molar relationship Class III [4-6]. Radiographically, the condyle may appear relatively normal but symmetrically enlarged, or it may be altered in shape (conical, spherical, elongated and lobulated). The condyle may also appear more radiopaque because of additional bone present. A morphologic variation like elongation of the condylar head and neck may be seen [3, 7]. In the present case, clinical picture majorly matched with the usual clinical findings of UCH. Radiographically, symmetrical condylar enlargement of the right side was seen as compared to the left side. Also, elongation of condylar neck along with slight backward tilting of the left condylar head and neck was evident, due to which, antero superior surface of the mandible was positioned against the posterior surface of the mandibular fossa which caused TMJ problems to the patient.

Histological examination of the mandibular head in cases of UCH reveals signs of growth. It generally shows overactivity in the articular cartilage, along with increase in thickness of the proliferative zone, the fibro-cartilagenous zone becomes hypertrophic, endochondreal bone formation takes place, while the articular zone remains remarkably intact [1, 2].

Diganosis is made by clinical and radiographic examinations. Approximately 98% of facial growth gets completed by 15 years of age in females and between 17 and 18 years of age in males. During growth phase, mandible grows from Condylion which is the most postero-superior copoint of mandibular condyle to Point B which is located in the largest concavity of the chin symphysis, at a speed of 1.6mm/year in females and 2.2mm/year in males. Accelerated growth may indicate active mandibular condyle hyperplasia [8]. Bone scintigraphy with single photon emission computerized tomography (SPECT) of the TMJ is an efficient diagnostic tool in detecting mandibular condylar hyperplasia [9, 10], but is generally not used due to high cost and unavailability of the modality. It helps in determining which side is affected, whether there is an abnormal condylar growth center or whether there is generalized mandibular growth, and finally, it is apparent whether or not the hyperplasia is still active or if it has become stable. However, it may be inconclusive in case of young patients and with slow growing hyperplasia, or may give false positive results in cases of inflammation, infection, post traumatic regeneration and malignant processes [4, 9, 10].

Treatment depends on the age, degree of deformity, hypofunction and aesthetic needs of the patient [11]. The basic considerations in the management of facial asymmetry secondary to condylar hyperplasia should include control of the growth

process to allow overall balanced facial development, which can be achieved by high condylectomy or condylar shave in actively growing cases [12] and in cases such as chondroma, osteoma, or other neoplasm in which a definite tissue diagnosis is required. If noticed in puberty while still growing, condylectomy alone may suffice [13]. If seen later, when compensatory growth has occurred, a need of condylectomy and osteotomies often of mandible and maxilla to restore facial symmetry and normal occlusion is required [14].

CONCLUSION

Unilateral condylar hyperplasia is one of the rare condition which results from increased activity of the condylar growth center which can cause considerable inconvenience and clinical problems to patients. Hence, early diagnosis and management is must. Careful and precise history, clinical and advanced radiographic imaging will usually reveal the true nature of the condition. As this condition can cause challenges in diagnosing, it has to be carefully differentiated with other similar conditions for planning and initiating the proper treatment modality for both functional activity and for aesthetic appearance.

REFERENCES

1. Neville BW, Damm DD, Allen CM, Bouquot J, Neville B. Hematologic disorders. Oral and maxillofacial pathology. 2009;2:526-7.
2. Matteson SR, Proffit WR, Terry BC, Staab EV, Burkes EJ. Bone scanning with 99m technetium phosphate to assess condylar hyperplasia: Report of two cases. Oral Surg Oral Med Oral Patho, 1985; 60: 356-67.
3. White and Pharoah. Textbook of Oral Radiology, 6th edition. Maryland: Mosby; 2007; 481
4. Slootweg PJ, Müller H. Condylar hyperplasia. A clinico-pathological analysis of 22 cases. J Maxillofac Surg. 1986;14:209-14.
5. Joondeph DR. Mysteries of asymmetries. Am J Orthod Dentofacial Orthop, 2000 May; 117(5):577-79.
6. D Mehrotra, S Dhasmana, M Kamboj, G Gambhir. Condylar hyperplasia and facial asymmetry. Report of five cases. J Maxillofac Oral Surg, 2011;10:50-56.
7. Mutoh Y, Ohashi Y, Uchiyama N, Teradak K, Hanada K, Sasaki F. Three dimensional analysis of condylar hyperplasia with computed tomography. J Craniomaxillofac Surg. 1991;19:49-55
8. Wolford LM, Morales-Ryan CA, García-Morales P, Perez D. Surgical management of mandibular condylar hyperplasia type 1. Proc (Bayl Univ Med Cent). 2009;22(4):321-29.
9. Saridin CP, Rajmakers PG, Al Shamma S, Tuinzing DB, Becking AG. Comparison of different analytical methods used for analyzing SPECT scans of patients with unilateral condylar

- hyperactivity. *Int J Oral Maxillofac Surg.* 2009;38(9):942-46.
10. Hodder SC, Rees JI, Oliver TB, Facey PE, Sugar AW. SPECT bone scintigraphy in the diagnosis and management of mandibular condylar hyperplasia. *Br J Oral Maxillofac Surg.* 2000;38(2):87-93.
 11. Crank S, Gray S, Sidebottom AJ. Condylar hyperplasia—Review of treatment outcomes and suggested pathway for management. *British Journal of Oral and Maxillofacial Surgery.* 2007 Oct 31;45(7):e60-1.
 12. Feldmann G, Linder-Aronson S, Rindler A, Söderström A. Orthodontic and surgical treatment of unilateral condylar hyperplasia during growth—a case report. *The European Journal of Orthodontics.* 1991 Apr 1;13(2):143-8.
 13. Wolford LM, Mehra P, Reiche-Fischel O, Morales-Ryan CA, García-Morales P. Efficacy of high condylectomy for management of condylar hyperplasia. *American journal of orthodontics and dentofacial orthopedics.* 2002 Feb 28;121(2):136-51.
 14. Wolford LM. Concomitant temporomandibular joint and orthognathic surgery. *Journal of oral and maxillofacial surgery.* 2003 Oct 1;61(10):1198-204.