

## Indolent Corneal Ulcers Revealing a Congenital Insensitivity to Pain with Anhidrosis

Leila Soltani, Houada ahammou, Ibtissam Hajji, Abdeljalil Moutaouakil

Ophthalmology Department CHU Mohamed VI Marrakech

**\*Corresponding author**

*Soltani Leila*

**Article History**

*Received: 25.10.2017*

*Accepted: 08.11.2017*

*Published: 30.11.2017*

**DOI:**

10.36347/sjmcr.2017.v05i11.002



**Abstract:** Congenital insensitivity to pain and anhidrosis (CIPA) or hereditary sensory and autonomic neuropathy (HSAN) type IV is a rare autosomal recessive disorder. It is one of the rare hereditary sensory autonomic neuropathies. The ophthalmological manifestations of this syndrome include the absence of corneal sensation, leads to corneal ulcers and opacities. Patients with hereditary sensory and autonomic neuropathies are rarely seen in pediatric ophthalmology practices. We describe the case of a boy with CIPA revealed by a self-inflicted eye trauma. We suspect congenital corneal insensitivity as part of CIPA as the boy had an history compatible with pain insensitivity involving at least another trigeminal branch which is the mandibular nerve. Normal development of visual function is expected in patients with CIPA without corneal opacities. Care for dry eye, prevention of corneal infection, and daily observation of the ocular surface are crucial for maintaining good visual function in CIPA patients. The aim of reporting this case is to draw the attention of clinicians to this rare syndrome that may give vital and functional complications. The diagnosis can be easily evoking with a certain number of clinical signs without using expensive tests. Rapid diagnosis, evaluation and appropriate management can prevent the complications of corneal anesthesia and the loss of visual function in patients diagnosed with CIPA.

**Keywords:** Congenital insensitivity, anhidrosis, autonomic neuropathies

### INTRODUCTION

Congenital insensitivity to pain and anhidrosis (CIPA) or hereditary sensory and autonomic neuropathy (HSAN) type IV is one of the rare hereditary sensory autonomic neuropathies [1]. First described by Gillespie *et al.* in 1960 [2] and so categorized by Dyck and Ohta in 1975 [3]. The incidence has been estimated to be one in 25,000 with no predilection toward sex and race [4].

Patients with CIPA may suffer from numerous painless traumas. The ocular manifestations of this syndrome include the absence of corneal sensation, which leads to corneal ulcers [5]. These patients have anhidrosis, causing attacks of fever of unknown origin, which may lead to death from hyperpyrexia. This report aims to describe a case of a boy with CIPA characteristics revealed by a self-inflicted corneal ulcer.

### CASE REPORT

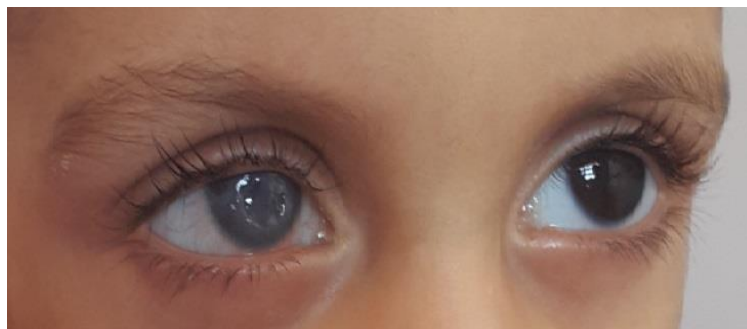We report the case of a 13 months boy who was presented for a red eye since two weeks. The family history revealed no familial or hereditary disease. Parents reported that the child never seemed to perspire; they observed several episodes of unexplained fever, premature spontaneous loss of a number of teeth.

Examination of the right eye revealed a central corneal ulcer (Figure1), the anterior chamber was calm. The left eye showed no anomaly, fundus examination was normal.

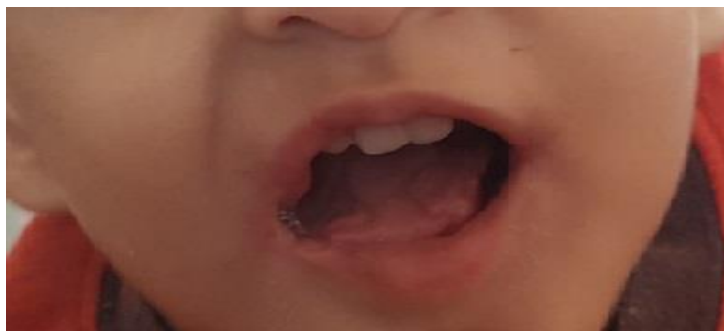
Corneal sensation was absent both on the ulcerated right eye and on the apparently normal left eye. A self-inflicted corneal abrasion was suspected, as he was seen to be putting his fingers into both eyes. A Schirmer test could not be completed, but 5-6mm of the paper appeared wet in less than a minute.

The intraoral examination revealed ulcers on the side of the tongue and buccal mucosa (Figure2). The hands and fingers also showed signs of biting (Figure3). A general examination showed a cutaneous xerosis with anhidrosis, absent pain and temperature sensation with preserved touch. Neurophysiological tests were normal.

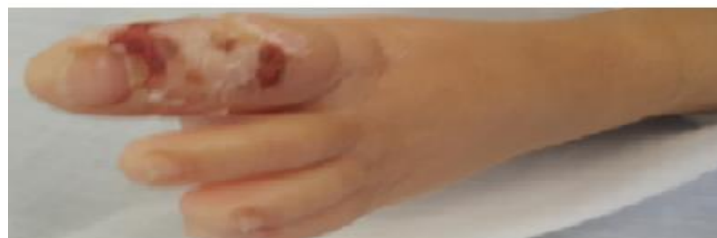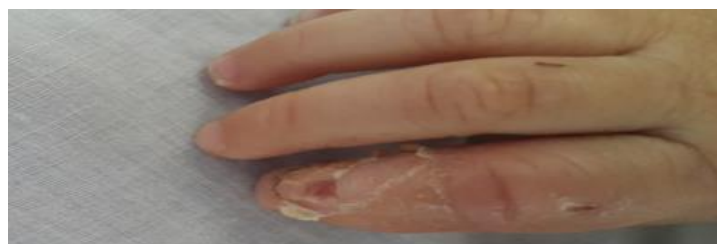
An intense lubrication regimen was instituted, but the ulcer failed to respond to topical treatment. After 2 weeks a therapeutic lens was set and a regular follow-up confirmed progressive improvement. The child needed several courses of parenteral antibiotics and debridement of one of his toes because of infection and necrosis. Three months after presentation there was a central residual corneal opacity in the right eye.



**Fig-1: central corneal ulcer on the right eye**



**Fig-2: ulcers on the side of the tongue and buccal mucosa.**



**Fig-3: signs of biting on fingers and toes.**

## DISCUSSION

In our case the absence of distress despite significant corneal damage, oriented us to suspect congenital corneal insensitivity as part of CIPA. A history compatible with pain insensitivity involving at least another trigeminal branch which is the mandibular nerve, as demonstrated by teeth being pulled out and ulcers on the side of the tongue and buccal mucosa, as well as peripheral nerves, as shown by the automutilation of limbs, also supported that possibility.

The ocular involvement is the initial symptom in CIPA in 33% of cases, leading to accurate diagnosis by the ophthalmologist [6]. Due to extensive discrepancies in the clinical picture, the diagnosis of CIPA usually can be based on the clinical presentation,

pharmacological test (intradermic reaction to histamine) and neuropathological exam. Detection of mutations on the NTRK1 gene represents as the last diagnostic step [4].

## CONCLUSION

Our case represents a rare syndrome of pronounced neurologic manifestations, with ocular abnormalities. Any young patient displaying an early corneal opacification, ulceration, with poor corneal sensation should be suspected of having CIPA. Accurate initial diagnosis and proper management are paramount to prevent visual loss due to long-term complications of corneal anesthesia.

## REFERENCES

1. A Safari, AA Khaledi, M Vojdani. Congenital Insensitivity to Pain with Anhidrosis (CIPA): A Case Report. *Iran Red Crescent Med J*. 2011; 13(2):134-138
2. A Haworth, D Ellison, H Thomas. Hereditary sensory and autonomic neuropathy with anhidrosis (type IV). *J R Soc Med* 1998;91:84-86.
3. PJ Dyck. Neuronal atrophy and degeneration predominantly affecting peripheral sensory neurones. In: Dyck PJ, Thomas PK, Lambert EH, eds. *Peripheral Neuropathy*. Philadelphia: WB Saunders. 1975:791-824.
4. K Ravichandra, C Kandregula, S Koya, D Lakhotia. Congenital Insensitivity to Pain and Anhydrosis: Diagnostic and Therapeutic Dilemmas revisited. *Int J Clin Pediatr Dent* 2015;8(1):75-81
5. RYagev , J Levy , Z Shorer , Lifshitz. Congenital insensitivity to pain with anhidrosis: ocular and systemic manifestations. *Am J Ophthalmol*. 1999;127(3):322-6.
6. S Amano, S Fokukoa. Ocular Manifestations of Congenital Insensitivity to Pain With Anhidrosis. *Am J Ophthalmol* 2006;141:472-477.