

Isolated and Displaced Fracture of the Posterior Angle of the Acromion in a Cyclist: Case Report

Mohamed BEN-AISSI*, Redouane HANI, Moncef BOUFETTAL, Mohamed Saleh BERRADA

Faculty of medicine of Rabat, Avenue Mohamed Belarbi El Alaoui B.P.6203 10000, Rabat.

*Corresponding author

Mohamed BEN-AISSI

Article History

Received: 01.11.2017

Accepted: 10.11.2017

Published: 30.11.2017

DOI:

10.36347/sjmcr.2017.v05i11.005



Abstract: Acromial fractures are a rare occurrence, very few cases of displaced isolated fractures of the acromion requiring surgical treatment have been reported. We report a case of isolated and displaced fracture of the acromion, happened at a cycle racer. The operative indication was formal because of the reduction of subacromial space. The fracture healing was completed without causing subacromial impingement. We recommend early surgical treatment for displaced acromion fractures with reduction of subacromial space.

Keywords: Acromial fractures, subacromial impingement, surgical treatment

INTRODUCTION

Fractures interesting the acromion are extremely rare; they represent less than 1 % of all skeletal fractures [1,2]. They are usually combined with other lesions of the shoulder girdle. Most of these fractures are not displaced [1,3,4]. For the moment, there is not consensus specific and widely accepted as for therapeutic behaviour and method of fixing of these fractures [5,6]. We report a case of isolated and displaced fracture of the acromion, happened at a cyclist racer.

CASE PRESENTATION

Mister A.M., 32-year-old, right-hander, amateur cycle racer, presented as a result of a bike fall with reception on the left shoulder stump, a pain located by this shoulder. Clinical examination found a slight edema of the stump of the shoulder, without cutaneous lesion. The abduction of the left arm was possible in the plan of the scapula, whereas retropulsion was impossible. There was no problem of rotation or of adduction.

The radiography of the shoulder, supplemented by a scanner, revealed an isolated and displaced fracture of the posterior angle of the acromion with reduction in subacromial space. The displaced fragment measured 4,5 cm and was part of the insertion of the deltoid muscle. There was no associated traumatic lesion of the scapular belt.

Under general anaesthesia, and after installation in position half sat, the fracture of the acromion was approached by an incision in shoulder pad. The subacromial space and the the rotator cuff were assessed across the fracture line. There was a reduction of the subacromial space, and the rotator cuff was undamaged. After reduction of the displaced fragment, fixing was maintained by 2 cannulated screws of 4,5 mm in diameter, 40 mm and 35 mm in length.

The 2 screws were directed perpendicular to the fracture line without reaching the acromio-clavicular joint or the subacromial space. This osteosynthesis was monitored by the image intensifier, and the binding was judged to be stable.

The postoperative radiographic examination confirmed the perfect reduction of the fracture line and the complete restoration of the height of the subacromial space. The upper left limb was immobilized in a scarf. Pendular movements were initiated the day after the operation before authorizing the patient's exit. The patient started a passive rehabilitation after 3 weeks while active rehabilitation was authorized from the 6th week. 3 months after the operation, the shoulder became painless and the consolidation was obtained allowing the patient to resume his sports activities completely, especially cycling.

After a 2-year follow-up, the shoulder is painless, and its mobility is preserved, with antépulsion at 170 °, abduction at 160 °, external rotation at 65 ° and internal rotation at 45 °. The constant score of the shoulder was at 92. On the radiography of control, no signs of conflict under acromial were noted.

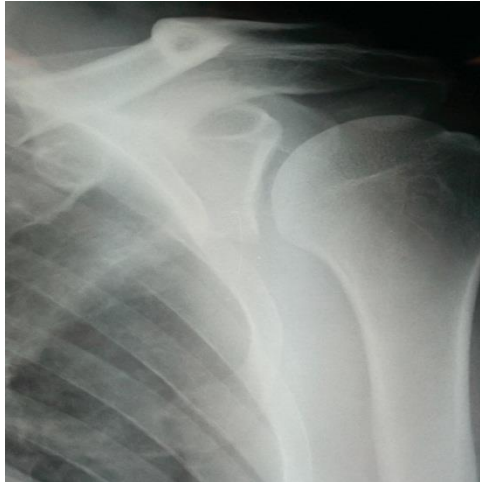

Fig-1: Preoperative shoulder x-ray.

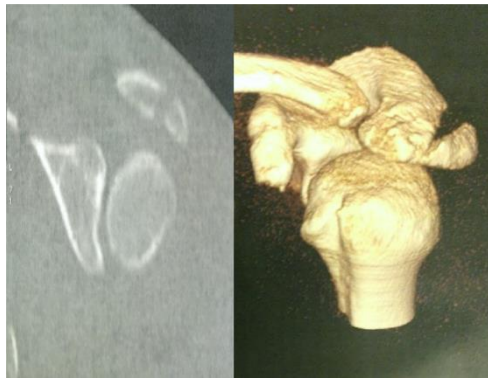

Fig-2: CT Scan shows displaced fracture of posterior angle of acromion process.

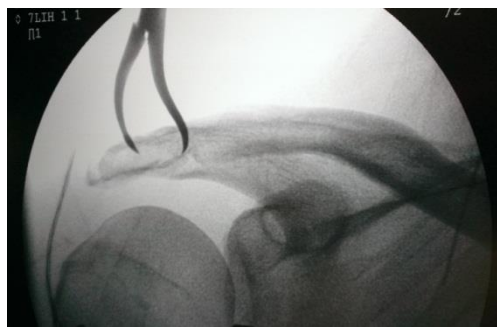


Fig-3: Surgical reduction of the displaced fragment.

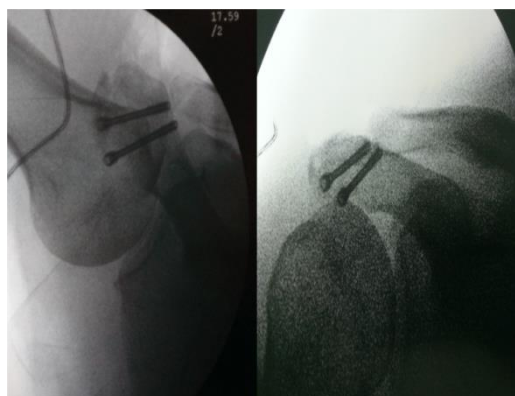


Fig-4: Osteosynthesis by two cannulated screws.

DISCUSSION

The acromion is a bony apophysis of form triangular and flattened, extending the scapula in the top of and except the scapulaire prickle. Fractures interesting the acromion are extremely rare and generally combined with other lesions of the shoulder girdle combined; particularly the fractures of the clavicle and those of the scapula [1,2]. The isolated and displaced fractures of the acromion remain an exception; the literature reports only a few cases, and these can be divided into 2 groups: fractures that result from a direct and significant force, and non direct stress fractures [7,8].

Most cases of fracture of the acromion who were published in literature happened on the occasion of an accident of the public highway; principally accidents of motorbike. Sports accidents procreating such lesions are rare; sports most accused being sports shooting [1,9]. The attack of the scapulaire belt is frequent after fall of the bike, it is principally represented by the fracture of the clavicle and the acromio-claviculaire luxation. Very rare cases of fracture isolated from the acromion happening following a fall of bike were described in literature.

On anatomic-pathological plan, the fractures of the acromion are classified by Kuhn [10] according to the degree of displacement in 3 types; in type 1 the fragment is minimally displaced, in type 2 the fragment is displaced but without reduction of the subacromial space, while in type 3 displacement cause a reduction of this space. In our case, the fracture is classified as type 3 according to Kuhn.

Most cases of os acromial fracture become symptomatic after age 40, though younger individuals have been described. These patients can present with symptoms of impingement, a rotator cuff tear, or focal pain. They are often confused with acromioclavicular separations, causing them to be diagnosed late. It is assumed that motion at the nonunion site which is accentuated by the downward pull [11,12].

Kuhn suggested surgical treatment for the fractures of type 3 that cause reduction of the subacromial space, the symptomatic stress fractures of and the painful nonunions. According to Hill [13], a symptomatic nonunion, a subacromial impingement, a displacement of more than 1 cm, opened fractures and a break of the superior suspensory complex of the shoulder, require a surgical treatment.

Different methods of fixation have been reported and individualization of the operative approach to the particular situation is required [5]. Kirschner wires in the older literature have now been replaced by screws and small plates across the acromion. Anterior-posterior screws in a lag technique are successful when a single fracture and limited comminution are present

[14,15]. Use of cannulated screws and placing wires through the cannulation and then over the superior surface of the acromion in a tension-band-like fashion is advocated by some to improve healing rates [6,16,17]. When several fracture lines and/or comminution exists small plates are needed. The advent of multiple methods demonstrates not only the lack of consensus on the best method but also the variability in the presentations of an os acromiale [1].

CONCLUSIONS

Acromial fractures are usually combined with other lesions of the shoulder girdle. Isolated displaced fractures of the acromion are clearly the exception to the rule and have been published only in case reports. The fracture of acromion can be treated with good results with early surgical treatment and proper fixation.

Consent

The patient has given their informed consent for the case to be published.

Competing interests

The authors declare no competing interest.

Authors' contributions

All authors have read and agreed to the final version of this manuscript and have equally contributed to its content and to the management of the manuscript.

REFERENCES

1. Nissen CW. The acromion: Fractures and Os acromiale. *Operative Techniques in Sports Medicine*. 2004 Jan 31;12(1):32-4.
2. *Operative Techniques in Sports Medicine*, Vol 12, No 1 (January), 2004: pp 32-34.
3. Liberson F. Os acromiale-a contested anomaly. *Jbjs*. 1937 Jul 1;19(3):683-9.
4. Goss TP. The scapula: coracoid, acromial and avulsion fractures. *Am J Orthop* 1996;25:106-15.
5. Ogawa K, Naniwa T. Fractures of the acromion and the lateral scapular spine. *J Shoulder Elbow Surg* 1997;8:544-8.
6. Çiçekli Ö, Akar A, Topçu HN. Displaced acromion fracture: A rare injury, case report. *Int J Surg Case Rep*. 2017 Sep 1;39:313-316.
7. Russo R, Vernaglia Lombardi L, Giudice G, Ciccarelli M. Arthroscopic treatment of isolated fracture of the posterolateral angle of the acromion. *Arthroscopy*. 2007 Jul;23(7):798.e1-3. Epub 2006 Nov 22.
8. Goodrich A, Crosland E, Pye J. Acromion fractures associated with posterior shoulder dislocation. *J Orthop Trauma* 1998;12: 521-522.
9. Benton J, Nelson C: Avulsion of the coracoid process in the athlete. *J Bone Joint Surg Am* 53-A:356-358, 1971.

10. Kuhn JE, Blasier RB, Carpenter JE. Fractures of the acromion process: a proposed classification system. *Journal of orthopaedic trauma*. 1994 Feb 1;8(1):6-13.
11. Bigliani LU, Barrallet JA, Brittis D, Self EB, Flatow EL. The surgical treatment of an unfused acromial epiphysis in association with a tear of the rotator cuff: a review of 41 cases. *J Shoulder Elbow Surg*. 1993;2:24.
12. Boehm TD, Matzer M, Brazda D, Gohlke FE. Os acromiale associated with tear of the rotator cuff treated operatively. *Bone & Joint Journal*. 2003 May 1;85(4):545-9.
13. Hill BW, Jacobson AR, Anavian J, Cole PA. Surgical management of coracoid fractures: technical tricks and clinical experience. *Journal of orthopaedic trauma*. 2014 May 1;28(5):e114-22.
14. Nasab SA. Isolated displaced fracture of the acromion: a rare case report and the consequence of treatment by open reduction and pin fixation. *Archives of trauma research*. 2013;1(4):184.
15. Peckett WR, Gunther SB, Harper GD, Hughes JS, Sonnabend DH. Internal fixation of symptomatic os acromiale: a series of twenty-six cases. *Journal of shoulder and elbow surgery*. 2004 Aug 31;13(4):381-5.
16. Sup Kim D, seung Yoon Y, hyun Kang D. Comparison of early fixation and delayed reconstruction after displacement in previously nondisplaced acromion fractures. *Orthopedics*. 2010 Jun 1;33(6):392-.
17. Mardy A, Mechchat A, El Ghazi A, El Idrissi M, Shimi M, El Ibrahim A, El Mrini A. Open fracture of the acromion associated with a supraspinatus tendon rupture: an exceptional case report. *The Pan African medical journal*. 2014;19.