

Solitary Kaposi's sarcoma in the Oral Cavity of an HIV-Negative Patient: A Rare Case Report

Amani Aroua, Radhia Ben Ali, Abdellatif Chokri, Jamil Selmi.

Oral surgery department, University dental clinic, Monastir, Tunisia

*Corresponding author

Amani Aroua

Article History

Received: 01.11.2017

Accepted: 07.11.2017

Published: 30.11.2017

DOI:

10.36347/sjmcr.2017.v05i11.007



Abstract: Traditionally, classic kaposi's sarcoma (KS) lesions have a general distribution, often involving the skin of the feet and legs, and to a lesser extent, that of the hands, arms, and trunk. Oral involvement is a rare manifestation. Initial oral involvement is an even rarer occurrence. We report an unusual case of classic KS presenting only in the oral cavity of a patient HIV negatif. The patient presents an oral KS lesion on the maxillary gingiva, with no other signs of the condition in any other region of the body. Clinicians and pathologists should be aware of the typical clinical, gross, and histologic features of KS. Moreover, we would like to emphasize that oral KS may affect patients without the Acquired Immune Deficiency Syndrome (AIDS) or exposure to immunosuppression. The awareness of oral classic KS as a diagnostic possibility is important in the work-up of vascular lesions in the oral cavity of non-immunosuppressed individuals.

Keywords: Kaposi sarcoma, oral cavity, maxillary gingiva, HIV, HHV8

INTRODUCTION

Kaposi's sarcoma (KS) is a multicentric neoplasm arising from cells of both vascular and lymphatic endothelium and is characterized for proliferation of spindle cells, neoangiogenesis, inflammation and edema [1]. It was first described by Moriz Kaposi in 1872 [2, 3]. It's the most common neoplasm in patients with AIDS [4]. Surveillance data indicate that Kaposi's sarcoma is roughly 20 times more likely to develop in patients with AIDS [5].

The KS can be subdivided into four types: classic, endemic, iatrogenic and HIV-associated (HIV-KS) [6- 9]. The main clinical manifestations appear in the form of macules, plaques and nodules may involve skin, lower extremities, oral cavity and visceral organs. Oral involvement is a rare manifestation. Initial oral involvement, whether associated with posterior generalization of lesions or existing as the sole presentation of the condition, is an even rarer occurrence [6].

The first documented case of primary oral classic KS was described by Feit in 1928 [10]. Few similar cases with primary involvement have been reported with few of them described a physical examination to confirm the absence of dermal lesions [11-16]. The aim of this article is to report an unusual case of classic KS presenting in the oral cavity of non-immunosuppressed individuals. This patient presents a primary oral KS lesion on the maxillary gingiva, with no other signs of the condition in any other region of the body.

CASE REPORT

A 31 year-old man with a 3 month history characterized by the progressive appearance of red

sessile nodule on the gingival mucosa opposite the site of the 14 extracted. The lesion was asymptomatic, non-ulcerated, reddish-purple, firm, exophytic growth, and measuring 2 cm in its larger diameter (Fig1). No other similar lesions in any other region of the body were detected. Panoramic radiograph showed no bone lesion (Fig2).

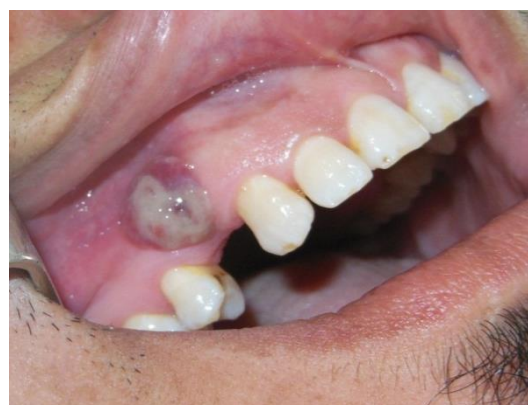

Fig- 1: red sessile nodule on the gingival mucosa opposite the site of the 14 extracted

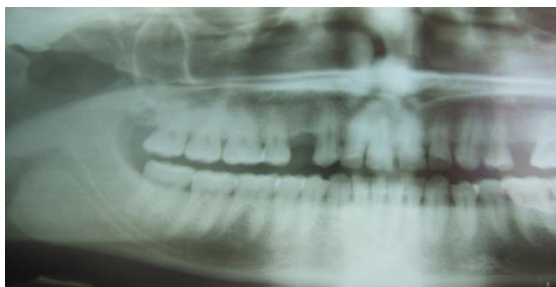

Fig- 2: Panoramic radiograph: no bone lesion

A biopsy excision of the lesion was performed (Fig 3 and 4).

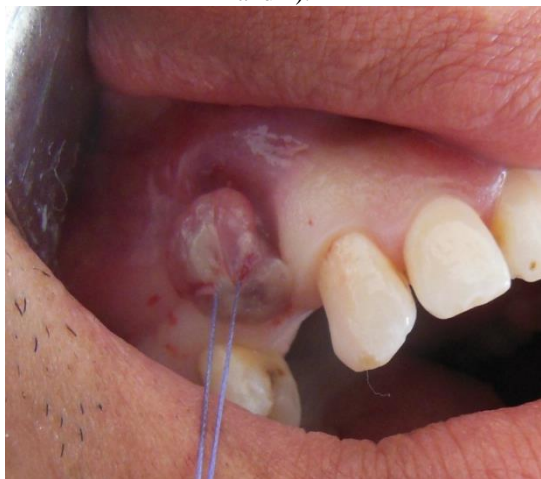

Fig-3: biopsy excision of the lesion

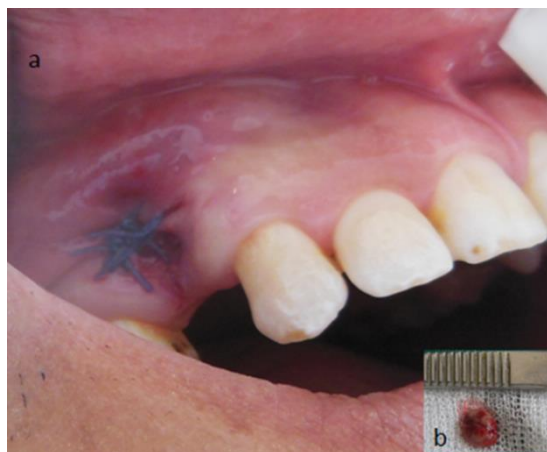


Fig- 4: a: surgical site; b: specimens

Histopathological examination showed a nodular and exophytic lesion of the submucosa. The cells tumor exhibit spindle cell ill-defined fascicles with some intervening thin-walled vessels, extravasation of red blood cells and haemosiderin collections. In between, there were found slit-like vessels containing erythrocytes. The stroma consists of dense connective tissue exhibiting collagen fibers randomly arranged and showing intense vascularization. Mitoses cell were found (Fig5). Immunohistochemistry was positive for herpes virus type 8 (HHV-8) (Fig 6). There was no past medical history of sexually transmitted diseases. The patient was HIV-negative, confirmed by the enzyme-

linked immunosorbent assay (ELISA), and there was no associated immunosuppression. Routine blood tests, renal and liver function tests were within normal limits. Based on the fibroscopy, no other similar lesions in the gastrointestinal tract were found.

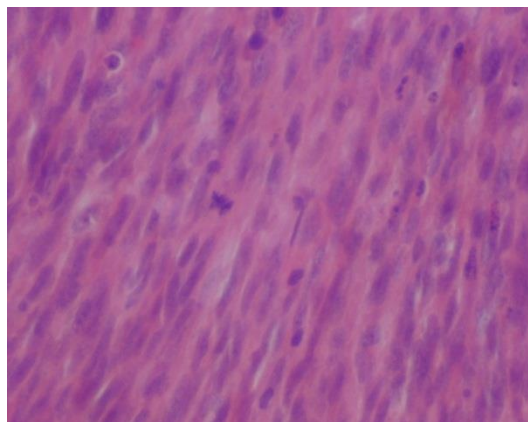


Fig- 5: Mitosis cell

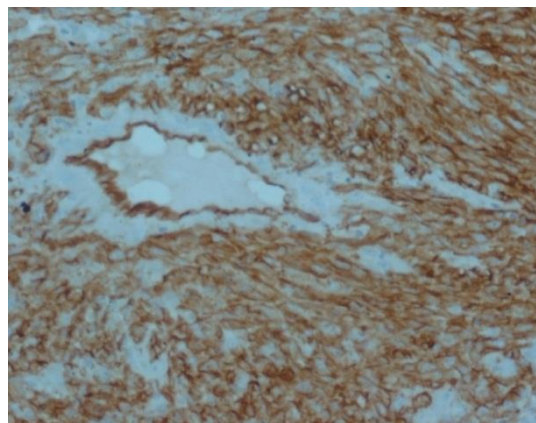


Fig- 6: Positive HHV-8 nuclear staining of the oral lesion

The definitive diagnosis was KS-HHV8. The patient did not receive any other treatment besides surgical excision of the tumor.

After three years, no recurrence has been described (fig 7).

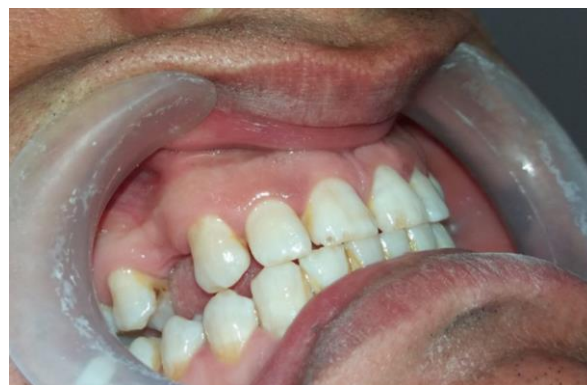

Fig-7: Control after 3 years

DISCUSSION

Kaposi's sarcoma is a malignant neoplasm of vascular origin. It occurs mainly among immunodeficient individuals, thus it is the most common neoplasm among HIV-positive patients [17]. Its pathogenesis is complex and has not been fully clarified [18].

KS is traditionally separated into four different types: classic, which primarily affects elderly men of Mediterranean and eastern European origin; endemic, which is common in parts of Africa; epidemic or AIDS-associated; and transplantation-associated [19].

KS-associated herpesvirus or human herpesvirus-8 (HHV- 8) was detected in a KS lesion in 1994, by Chang *et al.* [20]. Since then, HHV-8 DNA has been detected in all four variants of KS [6, 21].

In general, the most frequent site of involvement is the skin followed by the aerodigestive tract. The gastrointestinal system can be affected by multicentric lesions observed from oral cavity, oropharynx and esophagus to the perianal area, including organs like pancreas, liver and other organs like, lungs and tests [22].

Oral KS most frequently affects the hard palate, the gingival tissues and the dorsum of the tongue. SK can invade bone and create tooth mobility when involves it the palate or gingival [23]. The lesions are either single or multifocal, initially present as bluish-purple to red macules that progress to a papulo-nodular form, and eventually to large exophytic masses [7, 24].

The SK is the malignancy most often associated with HIV infection because of its propensity to develop in HIV-positive individuals [6, 23]. Many authors reported that patients with lesions of the oral mucosa had a higher death rate than those with exclusively cutaneous manifestations of the disease [12].

Definitive diagnosis of KS is made through a biopsy. The clinical differential diagnoses of KS include bacillary angiomatosis, pyogenic granuloma, oral nevus, lymphoma, oral hemangiomas or other benign vascular proliferations. However, these entities are easily ruled out on histologic examination. Kaposi form hemangioendothelioma and angiosarcoma are the most troublesome entities in the histologic differential diagnosis of KS [6].

The choice of the treatment options must be evaluated in terms of the specific needs of the patients such the type of KS, the disease stage, the progression pattern, the lesion location and size and immune status [21].

A variety of therapeutic options exist, including surgical excision, surgical ablation, intralesional interferon alpha-2 β , local or extended field radiotherapy, and chemotherapy. As KS may involve every tissue of the human body, the surgical approach is limited to diagnostic biopsy or even removal of small tumors, and it is considered palliative. For patients with rapid evolution, chemotherapy is recommended [25].

In the presented case the surgical removal was the treatment options used. After three years without evidence of recurrence, the patient remains under follow up.

CONCLUSION

The oral cavity may be the only or first site of KS, and therefore, becomes important in the diagnosis. Exams of the oral cavity should be done regularly in immunosuppressed patients, since a variable number of lesions can manifest initially in this site. Clinicians and pathologists should be aware of the typical clinical, gross, and histologic features of KS. Moreover, we would like to emphasize that oral KS may affect patients without AIDS or exposure to immunosuppression.

REFERENCES

1. Barnes L. Pathology and genetics of head and neck tumours: IARC; 2005.
2. Kaposi M. Idiopathisches multiples pigmentsarkom der haut. *Arch Dermatol Syph.* 1872;4:265-73.
3. Oji C, Chukwunke F. Clinical evaluation of Kaposi sarcoma in HIV/AIDS patients with orofacial lesions in Enugu, Nigeria. *Journal of Oral and Maxillofacial Surgery.* 2008;66(7):1362-5.
4. Beral V, Peterman TA, Berkelman R, Jaffe H. Kaposi's sarcoma among persons with AIDS: a sexually transmitted infection? *The Lancet.* 1990;335(8682):123-8.
5. Archibald CP, Schechter MT, Le TN, Craib KJ, Montaner JS, O'shaughnessy MV. Evidence for a sexually transmitted cofactor for AIDS-related Kaposi's sarcoma in a cohort of homosexual men. *Epidemiology.* 1992:203-9.
6. Mohanna S, Bravo F, Ferrufino JC, Sanchez J, Gotuzzo E. Classic Kaposi s sarcoma presenting in the oral cavity of two HIV-negative Quechua patients. *Medicina Oral, Patología Oral y Cirugía Bucal (Internet).* 2007;12(5):365-8.
7. Feller L, Wood NH, Lemmer J. HIV-associated Kaposi sarcoma: pathogenic mechanisms. *Oral Surgery, Oral Medicine, Oral Pathology, Oral Radiology, and Endodontology.* 2007;104(4):521-9.
8. Papagatsia Z, Jones J, Morgan P, Tappuni AR. Oral Kaposi sarcoma: a case of immune reconstitution inflammatory syndrome. *Oral Surgery, Oral Medicine, Oral Pathology, Oral Radiology, and Endodontology.* 2009;108(1):70-5.

9. Wang X, Wang X, Liang D, Lan K, Guo W, Ren G. Classic Kaposi's sarcoma in Han Chinese and useful tools for differential diagnosis. *Oral oncology*. 2010;46(9):654-6.
10. Feit H. Sarcoma (Kaposi). *Arch Derm Syphilol*. 1928;18:611-2.
11. Beckstead J. Oral presentation of Kaposi's sarcoma in a patient without severe immunodeficiency. *Archives of pathology & laboratory medicine*. 1992;116(5):543-5.
12. Fisher J, Ostfeld E. Kaposi sarcoma of the base of the tongue. *J Laryngol Otol*. 1980;94:663-8.
13. Howland W, Armbrrecht E, Miller J. Oral manifestations of multiple idiopathic hemorrhagic sarcoma of Kaposi: report of two cases. *Journal of oral surgery (American Dental Association: 1965)*. 1966;24(5):445-9.
14. Levin H. Kaposi's sarcoma of the hard and soft palate; report of a case with a five-year follow-up. *Oral surgery, oral medicine, and oral pathology*. 1957;10(5):522-31.
15. Markopoulos A, Papanayotou P, Trigonidis G. Kaposi's sarcoma of the oral cavity. *Quintessence international*. 1994;25(6).
16. Searles GE, Markman S, Yazdi HM. Primary oral Kaposi's sarcoma of the hard palate. *Journal of the American Academy of Dermatology*. 1990;23(3):518-9.
17. Fatahzadeh M, Schwartz RA. Oral Kaposi's sarcoma: a review and update. *International journal of dermatology*. 2013;52(6):666-72.
18. Moraes Md, Vasconcelos MG, Vasconcelos RG, Cabral R, Gomes IL, Queiroz LMGd. Solitary Kaposi's sarcoma in retromolar region of an HIV positive patient: case report. *Jornal Brasileiro de Patologia e Medicina Laboratorial*. 2012;48(1):45-9.
19. Moore PS. The emergence of Kaposi's sarcoma-associated herpesvirus (Human Herpesvirus 8). *Mass Medical Soc*; 2000.
20. Chang Y, Cesarman E, Pessin MS, Lee F, Culpepper J, Knowles DM, et al. Identification of herpesvirus-like DNA sequences in AIDS-associated Kaposi's sarcoma. *Science-AAAS-Weekly Paper Edition*. 1994;266(5192):1865-9.
21. Wamburu G, Masenga E, Moshi E, Schmid-Grendelmeier P, Kempf W, Orfanos C. HIV-associated and non-HIV associated types of Kaposi's sarcoma in an African population in Tanzania. Status of immune suppression and HHV-8 seroprevalence. *European Journal of Dermatology*. 2006;16(6):677-82.
22. Martellotta F, Berretta M, Vaccher E, Schioppa O, Zanet E, Tirelli U. AIDS-related Kaposi's sarcoma: state of the art and therapeutic strategies. *Current HIV research*. 2009;7(6):634-8.
23. Shetty K. Management of oral Kaposi's sarcoma lesions on HIV-positive patient using highly active antiretroviral therapy: Case report and a review of the literature. *Oral Oncology Extra*. 2005;41(9):226-9.
24. Vieira F, Somerville J, Kennedy KL. *AIDS & Clinical*. 2014.
25. Ablashi DV, Chatlynne LG, Whitman Jr JE, Cesarman E. Spectrum of Kaposi's sarcoma-associated herpesvirus, or human herpesvirus 8, diseases. *Clinical Microbiology Reviews*. 2002;15(3):439-64.