

Alobar Holoprosencephaly: about 2 cases and review of the literature

Lebbar K¹, Tapa E¹, Fichtali K², Benhessou M³, Bouhya S³

¹Resident doctor, ²Associate Professor, ³Head of service

Abderrahim Harrouchi Maternity Department of Ibn Rochd Hospital of Casablanca Morocco

*Corresponding author

Dr TAPA Elisa

Article History

Received: 04.11.2017

Accepted: 22.11.2017

Published: 30.11.2017

DOI:

10.36347/sjmcr.2017.v05i11.014



Abstract: Holoprosencephaly is a rare brain abnormality resulting from an incomplete cleavage of the primitive prosencephalon of forebrain during early embryogenesis. It includes a series of rare complex and heterogenesis disorders. Alobar form is associated with an extremely poor fetal prognosis. Here we report two cases of alobar holoprosencephaly diagnosed at the third trimester. Causes, diagnosis and management of holoprosencephaly are discussed referring to literature.

Keywords: Holoprosencephaly, heterogenesis disorders, dysfunction

INTRODUCTION

Holoprosencephaly (HPE) is a structural anomaly of the brain in which there is failed or incomplete separation of the forebrain early in gestation, and the most common forebrain defect in humans [1], with a prevalence of 1:250 in embryos and approximately 1:10,000 among live-born infants [2]. Classic HPE encompasses a continuum of brain malformations including (in order of decreasing severity): alobar, semilobar, lobar, and middle interhemispheric variant type HPE [3]. Other central nervous system abnormalities not specific to HPE may also occur. HPE is accompanied by a spectrum of characteristic craniofacial anomalies in approximately 80% of individuals with HPE. Seizures and pituitary dysfunction are common. Most affected fetuses do not survive; severely affected children typically do not survive beyond early infancy [4].

Imaging of the brain by CT scan or (preferably) MRI confirms the diagnosis of HPE, may define the anatomic subtype, and identifies associated CNS anomalies [3]. Approximately 25%-50% of individuals with HPE have a numeric or structural chromosome abnormality detectable by chromosome analysis [5]. Treatment of manifestations by a multidisciplinary team when possible.

MATERIAL AND METHODS

In the Abderrahim Harrouchi Maternity Department of Ibn Rochd Hospital of Casablanca, two cases of holoprosencephaly (HPE) in its alobar form were reported, giving rise to two live newborns of males who died within one hour of life.

Case 1

Mrs R. M, 25 years old, married, with no concept of consanguinity, no particular pathological antecedents, second gesture, second mother, mother of a living child, vaginal delivery, male, aged one and a half, having a good psychomotor development and without malformation or abnormal development, presented in our structure, at 34 weeks of amenorrhea (SA) and three days for premature delivery of a poorly followed pregnancy (performing a single obstetrical ultrasound in the first trimester). The patient had good fasting glucose

and an unprotected profile against toxoplasmosis and rubella.

The general examination found a patient normotended, normocardic, eupneic, in good general state. The obstetrical examination found a uterine height was 32 cm with regular fetal heart sounds at 138 BPM. At the vaginal touch, the parturient was in the active phase of the work with a cervix erased, and dilated to 4 cm, the presentation was cephalic and the membranes were intact. Obstetrical ultrasound performed at admission revealed a single cerebral ventricular cavity filling the entire cranial box with a laminated cerebral parenchyma with fusion of the thalamus, with presence opposite the root of the nose of a cystic formation measuring 46 * 30 mm (Fig. 1), evoking the alobar HPE. The biparietal diameter measures 117 mm (Fig. 2 and 3). The rest of the biometrics corresponded to the theoretical term.

A prophylactic caesarean section was performed for feto-pelvic disproportion that allowed the extraction of a new male, Apgar 4/10 the first minute and 2/10 the fifth minute.

Examination of the newborn reveals an axial hypotonia, a bulging anterior fontanel with a head

circumference at 47 cm (+4 DS) and highlighted facial malformations like hypertelorism and presence opposite the right orbit of two cerebral pelvic formations superimposed, compressing the root and the wing of the

nose as well as a shortened chin and low implanted ears. The newborn is declared dead after 15 minutes of life (fig 4).

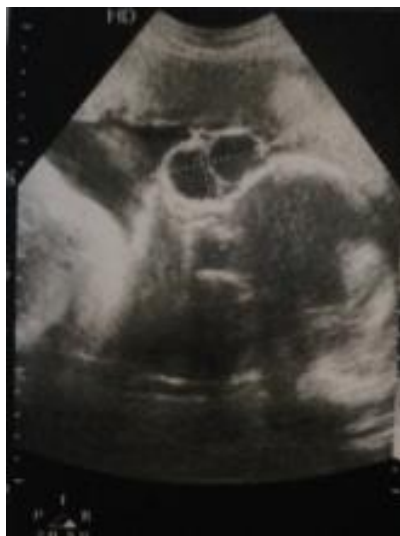

Fig-1: Ultrasound appearance of the cystic formation next to the root of the nose

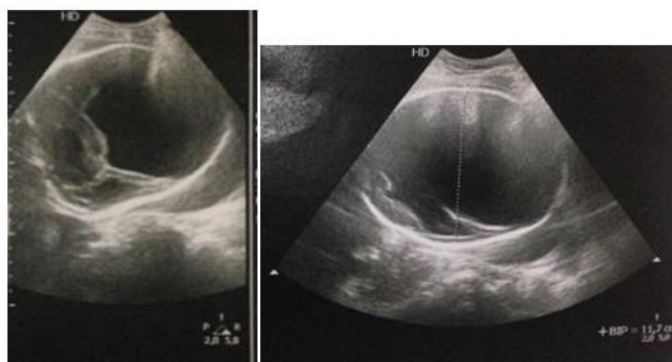


Fig-2, 3: ultrasound images showing a single cerebral ventricular cavity filling the whole cranial box with a laminated parenchyma associated with thalamus fusion, measuring the biparietal diameter at 11.7 cm

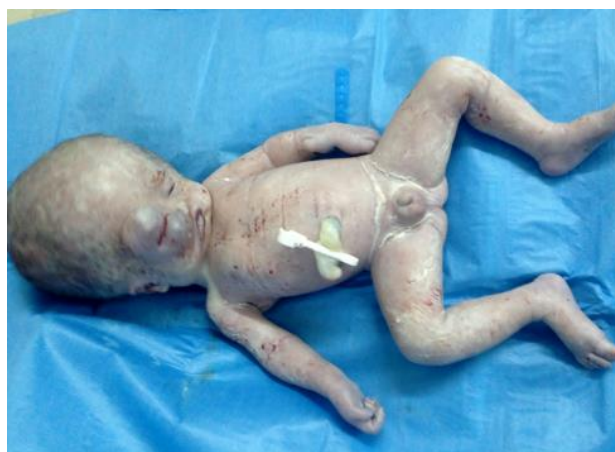

Fig-4: facial malformations

Case 2

Mrs. F. B, 35 years old, third gesture, third mother, mother of two children born vaginally aged 8 years and 3 years, having a normal psychomotor

development. This is a patient with a link of consanguinity second degree with her husband and pathological history of diabetes type II for 2 years poorly followed and no treatment during pregnancy.

The patient was admitted to obstetric emergencies at Ibn Rochd University Hospital in Casablanca for the management of a threat of premature delivery on an allegedly ill-attended pregnancy at 8 months

Clinical examination revealed uterine contractions present at two uterine contractions per 10 minutes, normal and regular fetal heart sounds at 128 Bpm, and uterine height at 33 cm and at the vaginal

level a cervix erased at 30% and dilated at 2 cm. The presentation was cephalic and the membranes were intact. Obstetrical ultrasound demonstrated a hydramnios with a Chamberlain index at 11 cm, as well as signs of alveolar HPE, namely a microcranium, a single ventricular cavity and a thalamus fusion (Figure 5). The fasting glucose level was 1.58 g / l. The serologies of toxoplasmosis and rubella showed residual immunity.

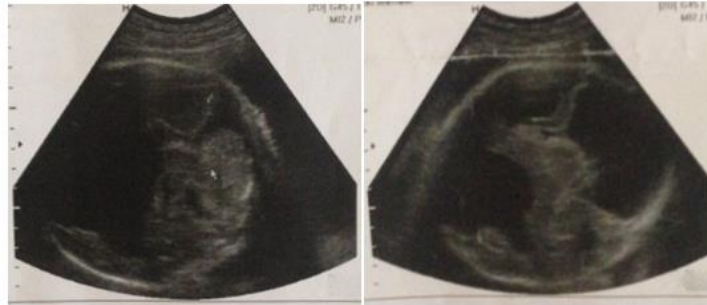

Fig-5: alobar holoprosencephaly (HPE), the most severe form of HPE. Characterized by an enlarged midline monoventricle (holoventricle) with fusion of the frontal lobes and the midline gray matter structures

The patient gave birth to a low birth weight of 2950 g, which was rapidly fatal. As part of an etiological assessment, a karyotype was performed on the umbilical cord blood revealing trisomy 18. Clinical examination revealed facial malformative abnormalities

including proboscis, rudimentary and retracted eyelids and microstomia. It was a synovial rhinocephalic cyclops according to the Stoll and Maraud classification (Figure 6, 7).

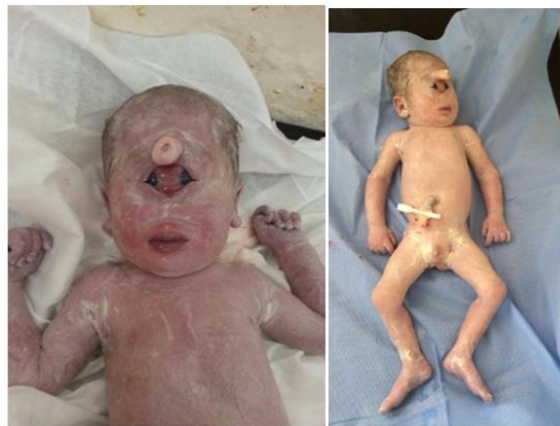

Fig-6, 7: Fetal face: presence of a proboscis above a single orbit with two eyeballs

DISCUSSION

Holoprosencephaly (HPE), the most common malformation of the forebrain in humans, is a structural anomaly of the brain resulting from failed or incomplete forebrain division in the third to fourth weeks of gestation. The forebrain (prosencephalon) incompletely cleaves into right and left hemispheres, deep brain structures, and the olfactory and optic bulbs and tracts [1, 6].

The Types of HPE [3] identified in a continuum of brain malformations have traditionally been divided into the following types (in decreasing order of severity):

- Alobar HPE, the most severe, in which there is a single “monoventricle” and no separation of the cerebral hemispheres
- Semilobar HPE, in which the left and right frontal and parietal lobes are fused and the interhemispheric fissure is only present posteriorly
- Lobar HPE, in which most of the right and left cerebral hemispheres and lateral ventricles are separated but the frontal lobes, most rostral aspect of the telencephalon, are fused, especially ventrally

- Middle interhemispheric fusion variant (MIHF), in which the posterior frontal and parietal lobes fail to separate [7].

A spectrum of craniofacial anomalies accompanies HPE in approximately 80% of affected individuals. The spectrum of facial anomalies begins with cyclopia (single eye or partially divided eye in single orbit), the most severe presentation, common clinical features in individuals without obvious findings such as cyclopia (the case in our observation number 2), synophthalmia, or a proboscis include microcephaly (although hydrocephalus can result in macrocephaly), closely spaced eyes (hypotelorism), depressed nasal bridge, single maxillary central incisor, and cleft lip and/or palate. Malformations of the nose include complete absence, agenesis of the nasal cartilage, and proboscis (flat nose with a single central nostril without nasal bones) [8]. Palatal anomalies include various midline and lateral clefts, midline palatal ridge, bifid uvula, high-arched palate, and absence of the superior labial frenulum [9]. A single maxillary central incisor may be present; although a nonspecific finding, it is a distinctive microform in autosomal dominant HPE.

Causes of Holoprosencephaly

Different causes of holoprosencephaly are found in the literature. We can mention among others:

Environmental Causes

The most common teratogen in humans known to cause holoprosencephaly (HPE) is maternal diabetes mellitus. Infants of diabetic mothers have a 1% risk (a 200-fold increase) for HPE. Other teratogens, including alcohol and retinoic acid, have been associated with HPE in animal models, although their significance in humans is not established [10]. In our case 2, poorly monitored type 2 diabetes was a risk factor for fetal malformations including holoprosencephaly. More recently, cholesterol-lowering agents (i.e., statins) have been associated with HPE.

Heritable Causes

Approximately 25%-50% of individuals with HPE have a chromosome abnormality. Numeric chromosome abnormalities include trisomy 13, trisomy 18, and triploidy[11]. Structural chromosome abnormalities associated with HPE have been reported in virtually all chromosomes, but the most frequent (in descending order) are deletions or duplications involving various regions of 13q. Those with HPE and a normal karyotype cannot be distinguished from those with an abnormal karyotype on the basis of craniofacial abnormality or subtype of HPE [5].

Establishing the Diagnosis

Imaging of the brain by CT scan or MRI confirms the diagnosis of HPE, defines the clinical subtype, and identifies associated CNS anomalies [3].

HPE is most frequently diagnosed during the newborn period when abnormal facial findings and/or neurologic presentation prompt further evaluation. Often HPE is first identified on prenatal ultrasound examination

Evaluation Strategy

Identification of the cause of holoprosencephaly (HPE) aids in establishing prognosis and mode of inheritance for genetic counseling. To help establish the cause of HPE, the work-up for an individual with HPE includes the following:

- Prenatal history to identify possible environmental causes
- Physical examination to identify findings that could establish the diagnosis of monogenic syndromic HPE
- A detailed family history with emphasis on pregnancy loss, neonatal deaths, and relatives with abnormal craniofacial findings and/or developmental delay to determine if monogenic nonsyndromic HPE is a consideration
- Focused examination of the parents to identify microforms of HPE
- Genetic testing

Clinical manifestations commonly observed in children with HPE include the following:

- Developmental delay: The degree of delay is variable, correlating with the severity of the brain malformation, but tends to be severe.
- Seizures, hydrocephalus, hypothalamic and brain stem dysfunction
- Pituitary dysfunction is manifest by partial or complete panhypopituitarism with abnormal function of any or all of the anterior and/or posterior pituitary hormones, though central diabetes insipidus is by far the most common finding in persons with non-chromosomal, nonsyndromic HPE [9, 12].
- Short stature and failure to thrive are common, especially in more severely affected children. Growth hormone deficiency and/or chromosome anomalies
- Feeding difficulties may be a major problem in children with HPE. At least part of the difficulty may derive from axial hypotonia, poor suck as a result of neurologic complications, lethargy, seizures and their effects, side effects of medications, and lack of interest.

A common misperception is that children with HPE do not survive beyond early infancy. While this is the case for the most severely affected children, a significant proportion of more mildly affected children (as well as some severely affected children) survive past age 12 months. Among affected individuals with a normal karyotype, an inverse relationship exists

between the severity of the facial phenotype and length of survival.

- Infants with cyclopia or ethmocephaly generally do not survive beyond age one week.
- Approximately 50% of children with alobar HPE die before age four to five months and 20% live past the first year of life [13].

Almost all survivors have apparently normal vision and hearing; they smile and demonstrate memory [13].

Treatment of Manifestations

Treatment for HPE varies according to the brain malformations and associated anomalies. Most affected children benefit from a multidisciplinary team approach with clinicians very familiar with HPE.

- Hormone replacement therapy
- Antiepileptic drugs can help decrease the frequency and intensity of seizures.
- Feeding difficulties and failure to thrive may be managed with gastrostomy tube placement. Thickening of feeds and upright positioning after feeding may be helpful to alleviate gastroesophageal reflux. To achieve the best growth in the child with HPE, the quality of the feeds is more important than the quantity.
- Accommodations for oral feeding with cleft lip and/or palate may require specific nipples, cups, and parental training.
- Placement of a ventriculo-peritoneal shunt may be necessary in children with HPE and hydrocephalus.
- In older children, surgical repair of cleft lip and/or palate may be indicated.
- For children with cleft lip and/or palate, referral to a specialized cleft or craniofacial clinic is recommended.
- Onset of new neurologic findings or deterioration warrant evaluation for seizures and/or hydrocephalus and/or shunt malfunction. Such evaluation would include vital sign monitoring, neurologic examination, EEG, and MRI.
- A major aspect of treatment is support and counseling of the parents [14].

Surveillance

Height, weight, and head circumference should be measured during health maintenance evaluations. Evaluation for endocrine deficiencies should be undertaken at appropriate intervals and during health maintenance visits.

CONCLUSION

Holoprosencephaly, although rare, must be recognized and diagnosed. If the alobar forms are fatal, the minor forms can benefit from a medical or of a ventricular derivation. Antenatal screening is indicated

in case of pregnancy after a history of holoprosencephaly: fetal ultrasound and possible karyotype.

REFERENCES

1. Dubourg C, Bendavid C, Pasquier L, Henry C, Odent S, David V. Holoprosencephaly. *Orphanet J Rare Dis.* 2007;2:8.
2. Leoncini E, Baranello G. Frequency of holoprosencephaly in the International Clearinghouse Birth Defects Surveillance Systems: Searching for population variations. *Birth Defects Res A Clin Mol Teratol.* 2008;82:585–91.
3. Hahn JS, Barnes PD. Neuroimaging advances in holoprosencephaly: refining the spectrum of the midline malformation. *Am J Med Genet Part C Semin Med Genet.* 2010;154C:120–32.
4. Rubinstein D, Cajade-Law AG, Youngman V. The development of the corpus callosum in semilobar and lobar holoprosencephaly. *Pediatr Radiol.* 1996;26:839–44.
5. Olsen CL, Hughes JP, Youngblood LG. Epidemiology of holoprosencephaly and phenotypic characteristics of affected children: New York State, 1984-1989. *Am J Med Genet.* 1997;73:217–26.
6. Gropman AL, Muenke M. Holoprosencephaly. In: Cassidy SB, Allanson JE, eds. *Management of Genetic Syndromes.* New York, NY: Wiley-Liss, Inc; 2005:279-96.
7. Barkovich AJ, Quint DJ. Middle interhemispheric fusion: an unusual variant of holoprosencephaly. *AJNR Am J Neuroradiol.* 1993;14:431–40.
8. Hennekam R, Van Noort G, de la Fuente FA, Norbruis OF. Agenesis of the nasal septal cartilage: another sign in autosomal dominant holoprosencephaly. *American Journal of Medical Genetics Part A.* 1991 Apr 1;39(1):121-2.
9. Solomon BD, Lachawan F, Mercier S. Mutations in ZIC2 in Human Holoprosencephaly: description of a novel ZIC2-specific phenotype and comprehensive analysis of 157 individuals. *J Med Genet.* 2010a;47:513–24.
10. Johnson CY, Rasmussen SA. Non-genetic risk factors for holoprosencephaly. *Am J Med Genet C Semin Med Genet.* 2010;154C:73–85.
11. Solomon BD, Rosenbaum KN, Meck JM. Holoprosencephaly due to numeric chromosome abnormalities. *Am J Med Genet C Semin Med Genet.* 2010c;154C:146–8.
12. Lachawan F, Solomon BD, Roessler. Clinical spectrum of SIX3-associated mutations in holoprosencephaly: correlation between genotype, phenotype and function. *J Med Genet.* 2009;46:389–98.
13. Barr M Jr, Cohen MM Jr. Holoprosencephaly survival and performance. *Am J Med Genet.* 1999;89:116–20.

14. Mercier S, Dubourg C, Belleguic M. Genetic counseling and “molecular” prenatal diagnosis of holoprosencephaly (HPE). *Am J Med Genet C Semin Med Genet.* 2010;154C:191–6.