

MRKH Syndrome with Situs Inversus Totalis- A Rare Case Report

Dr. Marufa Bilkish¹, Prof (Dr). Pranab Kumar Biswas², Dr. Sandhya Das³, Dr. Sk Ashik Uzzaman⁴, Dr. Manosi Santra⁵, Dr. Soumen Patra⁶

^{1,5,6} Junior Resident, Dept of Obst. & Gynaecology, Calcutta National Medical College, Kolkata

² Professor, Dept of Obst. & Gynaecology, Calcutta National Medical College, Kolkata

³ Assistant professor, Dept of Obst. & Gynaecology, Calcutta National Medical College, Kolkata

⁴ Junior Resident, Dept. Of Psychiatry R.G. Kar Medical College, Kolkata

*Corresponding author

Dr. Marufa Bilkish

Article History

Received: 22.11.2017

Accepted: 27.11.2017

Published: 30.11.2017

DOI:

10.36347/sjmcr.2017.v05i11.032



Abstract: The Mayer-Rokitansky-Küster-Hauser (MRKH) syndrome is characterized by congenital Müllerian duct aplasia of the uterus and the upper part (2/3) of the vagina in women showing normal development of secondary sexual characteristics and a normal 46XX karyotype. Situs inversus is a rare congenital anomaly characterized by the transposition of the abdominal organs, viscera and vasculature. When associated with dextrocardia it is known as situs inversus totalis. Here we report a case of 35 year old lady presented with primary amenorrhea and absence of upper vaginal orifice with normal secondary sexual characteristics. After laparoscopy, hormonal assay and karyotyping she was diagnosed as MRKH syndrome. On Ultrasound abdomen we found all the abdominal viscera were located just opposite, associated with right sided renal agenesis and on chest x-ray there was dextrocardia i.e. situs inversus totalis.

Keywords: Mayer-Rokitansky-Küster-Hauser (MRKH) syndrome, Situs Inversus Totalis, Congenital Abnormalities

INTRODUCTION

Mayer-Rokitansky-Küster-Hauser syndrome (MRKH) is an uncommon gynecological condition, with an incidence of one in 4000–5000 female births [1,2], and is the second most frequent cause of primary amenorrhea after gonadal dysgenesis [3]. It accounts approximately 10% of cases of primary amenorrhea. This disorder is a form of Müllerian agenesis characterized by vaginal atresia, and uterine/tubal abnormalities which may include absence or hypoplasia of the uterus and Fallopian tubes but functional ovaries. The patients karyotype is 46XX with normal secondary sexual characteristics, as the ovaries are present and functional, but menstruation is absent [4].

There are variants of MRKH syndrome with varied clinical presentations. It is primarily related to the reproductive system and includes vaginal agenesis with variable müllerian duct abnormalities accompanied in some cases by renal, skeletal and auditory abnormalities. One variant of MRKH is MURCS (Müllerian Renal Cervico thoracic Somite), involves uterovaginal hypoplasia or aplasia, renal, bone and cardiac malformations [1-3].

Situs inversus is a rare congenital anomaly and characterized by the transposition of the abdominal organs, viscera and vasculature. Generally, this condition is an autosomal recessive genetic condition. Its incidence in the population of only 0.001 to 0.01 [5,6] with a male-to-female ratio of 3:2 [7].

The exact etiology is unknown but Autosomal recessive and X-linked inheritance has been reported. It may or may not be associated with dextrocardia, also

known as situs inversus totalis [5, 6]. It generally discovered incidentally, often when a radiographic assessment of a patient is undertaken, particularly to investigate blunt abdominal trauma or infection.

Situs inversus occurs more commonly with dextrocardia [8]. A 3%-5% incidence of congenital heart disease is observed in situs inversus with dextrocardia, usually with transposition of the great vessels. Of these patients, 80% have a right-sided aortic arch. Situs inversus with levocardia is rare [9] and it is almost always associated with congenital heart disease [10,11].

CASE REPORT

A 35 years old lady P₀₊₀ Muslim married but separated came from rural area of South 24 parganas, West Bengal presented at gynaecology OPD of CNMC with the chief complaints of primary amenorrhea and unable to perform sexual activity due to absence of vaginal orifice.

On physical examination height 5'1", average built, well developed secondary sexual characteristics and compatible with her chronological age (Fig: 1). On gynecological examination clitoris, labia majora and minora, urethra are normal, lower vagina admitting tip of finger and upper vagina absent. Speculum examination couldn't be performed.

She was asymptomatic with no significant past medical history. On systemic examination her apex beat located on the 5th right intercostal space. The chest radiograph confirmed dextrocardia and also revealed the gastric air bubble on the right (Fig-2), which was suggestive of situs inversus totalis. She had scoliosis since her childhood. Echocardiography reveals normal great vessel relation and mirror image dextrocardia.

On hormonal assay FSH, LH, prolactin & thyroid function tests are within normal limits. Ultrasonography revealed a left sided liver and gall bladder, Common bile duct, portal vein with a right sided spleen. No definite uterus like structure noted behind urinary bladder. Ovaries like structures seen in both sides of pelvis. Right sided renal agenesis noted. Karyotyping shows 46XX, determining the diagnosis of Mayer-Rokitansky-Kuster-Hauser syndrome type II (MURCS). On laparoscopic examination bilateral healthy ovaries present along with part of fallopian tube, round ligament and mullerian tubercle (Fig 3). No uterus cervix or vaginal orifice seen. Patient wants surgical correction of vagina (neovaginoplasty).



Fig 1 : Shows normal physical stature in a patient of MRKH Syndrome with situs inversus totalis.

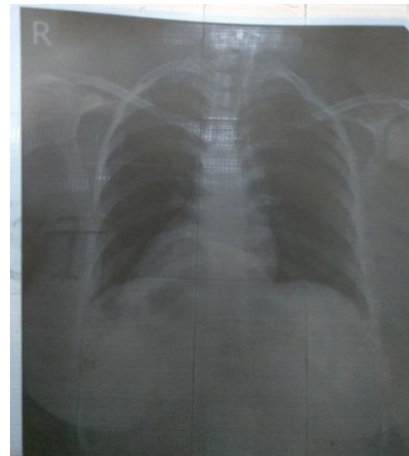


Fig 2: Chest X-ray PA view shows dextrocardia, right sided fundal gas shadow with R/L superimposed breast shadow.

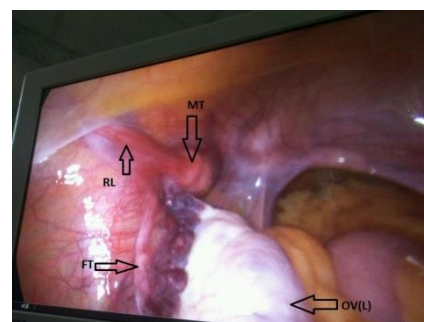


Fig 3: Shows laparoscopic findings of left sided ovary(OV), part of fallopian tube(FT), Mullerian tubercle(MT) & Round ligament(RL) on the left pelvic

DISCUSSION

There may be various forms of Müllerian duct abnormalities, ranging from small anatomical variations to total aplasia. The most common cause of abnormalities is the Mayer-Rokitansky-Kuster-Hauser syndrome (MRKH). It affects up to 90% of women with vaginal agenesis [12, 13].

One variant of MRKH is MURCS, involves uterovaginal hypoplasia or aplasia, renal, bone and cardiac malformations[1-3]. Renal malformations include: unilateral agenesis, horseshoe kidney, renal hypoplasia, ectopic kidneys and hydronephrosis. Bone malformations occur particularly in the vertebrae, most commonly with vertebral fusion (particularly cervical vertebrae), Klippel-Feil syndrome and scoliosis. Cardiac alterations and digital alterations such as syndactyly and polydactyly are rarer than those previously mentioned [1]. This particular patient had right sided renal agenesis and scoliosis with core features of MRKH syndrome. Interestingly the patient also had situs inversus totalis. The normal development of the female reproductive tract depends on the interaction between genetic, hormonal and environmental factors for the differentiation of the Müllerian and Wolfian ducts, and the urogenital sinus [1-3]. Changing these factors can result in a wide spectrum of abnormalities of the reproductive tract, including imperforate hymen, vaginal agenesis or

atresia, incomplete fusion of the Müllerian ducts and Müllerian aplasia [1-4].

The Müllerian and Wolffian ducts are essential for the development of the female and male reproductive system, respectively. The mullerian ducts mature to become fallopian tubes, uterus, cervix and upper two thirds of the vagina (lower third is derived from the urogenital sinus), while the Wolffian duct degenerates [12, 14]. The Urogenital sinus and Mullerian ducts, of which the female reproductive system is composed, are conjoined via the mullerian tubercle. The presence of the Mullerian Inhibiting Factor (MIF) or anti-mullerian hormone is the driving force behind maturation of the mullerian ducts to become the above mentioned portions of the female reproductive system. Developmental abnormalities, such as uterine and vaginal agenesis or the duplication of the uterus and vagina are preceded by any disruption in the production of MIF [13]. Laparoscopy is useful in these situations as it favors a minimally invasive surgical approach in diagnostics and treatment [15].

CONCLUSION

Congenital malformations of female genitalia are often a challenge for doctors, requiring a great knowledge of embryonic development of the genital tract due to the wide variety of possible diagnoses. The diagnosis and treatment of MRKH syndrome is difficult. Considering the varying presentation of MRKH and numerous treatment options are there and each case be individualized. Situs inversus totalis is a very rare congenital condition. As per our knowledge no previous study or case report on association between this two conditions, especially in Indian scenario. More research needed on this background.

REFERENCES

1. Morcel K, Camborieux L. Mayer-Rokitansky-Kuster-Hauser (MRKH) syndrome. *Orphanet J Rare Dis.* 2007;2:13.
2. Sultan C, Biason-Lauber A, Philibert P. Mayer-Rokitansky-Kuster-Hauser syndrome: recent clinical and genetic findings. *Gynecol Endocrinol.* 2009;25:8-11.
3. Fedele L, Bianchi S, Tozzi L, Borruto F, Vignali M. A new laparoscopic procedure for creation of a neovagina in Mayer-Rokitansky-Kuster-Hauser syndrome. *Fertility and sterility.* 1996 Nov 30;66(5):854-7. Sem KK, Kapoor A. Mayer-Rokitansky-Kuster-Hauser syndrome. *Ind J Radiol Imag.* 2006;16: 805-7. Nelson MJ, Pesola GR. Left lower quadrant pain of unusual cause. *J Emerg Med* 2001; 20: 241-5.
4. Kassi A, Kouassi J, Souaga K, Koffi E, Kassanyou S. Appendicite aiguë sur situs inversus: une forme topographique à ne pas méconnaître à propos d'un cas. *Médecine d'Afrique noire.* 2004; 51:429-31.
5. Huang SM, Yao CC, Tsai TP, Hsu GW. Acute appendicitis in situs inversus totalis. *J Am Coll Surg*2008; 207: 954.
6. Maldjian PD, Saric M. Approach to dextrocardia in adults: review. *AJR Am J Roentgenol* 2007; 188: S39-49.
7. Gindes L, Hegesh J, Barkai G, and Jacobson JM, Achiron R. Isolated levocardia: prenatal diagnosis, clinical importance, and literature review. *J Ultrasound Med* 2007; 26: 361-5.
8. Douglas YL, Jongbloed MR, den Hartog WC, Bartelings MM, Bogers AJ, Ebels T, DeRuiter MC, Gittenberger-de Groot AC. Pulmonary vein and atrial wall pathology in human total anomalous pulmonary venous connection. *International journal of cardiology.* 2009 May 29; 134(3):302-12.
9. Fung TY, Chan DL, Leung TN, Leung TY, Lau TK. Dextrocardia in pregnancy: 20 years' experience. *J Reprod Med* 2006; 51: 573-7.
10. Guerrier D, Pellerin I, Pasquier L, Mouchel T. The Mayer-Rokitansky-Küster-Hauser syndrome (congenital absence of uterus and vagina)-phenotypic manifestations and genetic approaches. *Journal of negative results in biomedicine.* 2006 Dec; 5(1):1.
11. Dornelas M, Arruda F, Sant'Anna L, Netto G, Souza R, Machado D, Correa M, Dornelas M. Reconstrução vaginal pelo retalho neurovascular podendo crural na Síndrome de Rokitansky. *Revista Brasileira de Cirurgia Plástica.* 2001 Jan 1; 25(3):525-31.
12. Da Cunha GB, de Alencastro JB, Ferreira MS, Alves CL, da Silveira PM. Neovagina por Videolaparoscopia na Síndrome de Mayer-Rokitansky-Kuster-Hauser.
13. Golash V. Laparoscopic management of acute appendicitis in situs inversus. *Journal of minimal access surgery.* 2006 Dec;2(4):220.