

## A Rare Case of Spontaneous Splenic Hydatid Cyst Rupture

O. Jbara<sup>1\*</sup>, H. Tabakh<sup>1</sup>, N. Touil<sup>1</sup>, A. Siwane<sup>1</sup>, O. Kacimi<sup>1</sup>, N. Chikhaoui<sup>1</sup>

<sup>1</sup>Service de Radiologie Des Urgences, CHU Ibn Rochd, 1, Rue des Hôpitaux, Casablanca, Morocco

DOI: [10.36347/sjmcr.2023.v11i04.067](https://doi.org/10.36347/sjmcr.2023.v11i04.067)

| Received: 12.02.2023 | Accepted: 18.03.2023 | Published: 25.04.2023

\*Corresponding author: O. Jbara

Service de Radiologie Des Urgences, CHU Ibn Rochd, 1, Rue des Hôpitaux, Casablanca, Morocco

### Abstract

### Case Report

Hydatid disease is a parasitic infection characterized by the formation of cysts in the organs. The liver and the lungs are most often affected. Cysticercosis of the spleen is rare, accounting for less than 8% of all cases of cysticercosis in humans. Generally, hepatic and splenic localizations coexist. The clinical signs and symptoms of a splenic cyst depend on its size, its relationship to the surrounding organs, and complications. One of the complications of splenic hydatid cysts is spontaneous rupture of the cyst after trauma or following an increase in intracystic pressure. A ruptured splenic hydatid cyst in the abdominal cavity, as in our case, can lead to complications such as peritoneal irritation, urticaria, anaphylaxis and death, requiring both prompt surgical intervention and careful postoperative care. In our case study, we will present a case of spontaneous rupture of a splenic hydatid cyst in the abdominal cavity.

**Keywords:** Hydatid Cyst, Spleen, Rupture.

Copyright © 2023 The Author(s): This is an open-access article distributed under the terms of the Creative Commons Attribution 4.0 International License (CC BY-NC 4.0) which permits unrestricted use, distribution, and reproduction in any medium for non-commercial use provided the original author and source are credited.

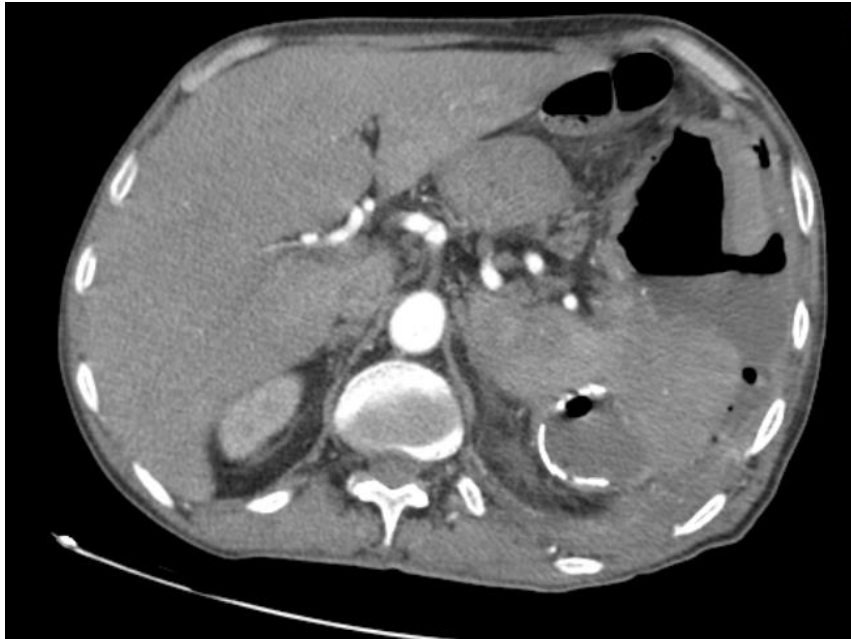## INTRODUCTION

Cystic echinococcosis is an infection that is still a serious problem in endemic regions, especially in the Middle and Far East and in the Mediterranean basin. It is a parasitic infestation caused by the larval stage of *Echinococcus granulosus* [1]. Hydatid cysts can develop in any organ of the body, but most commonly in the liver and lungs rarely in other organs such as the spleen [2, 3]. The clinical signs and symptoms of hydatid cysts depend on their size, relationship to adjacent organs and complications. A common complication of hydatid disease is cyst rupture after trauma or spontaneous rupture due to increased intracystic pressure. Intra-abdominal rupture can lead to complications including signs of peritoneal irritation, urticaria, anaphylaxis and death. Therefore, rupture of a hydatid cyst requires both emergency surgery and careful postoperative care. In this study, we present a case of spontaneous intraperitoneal rupture of a splenic KH.

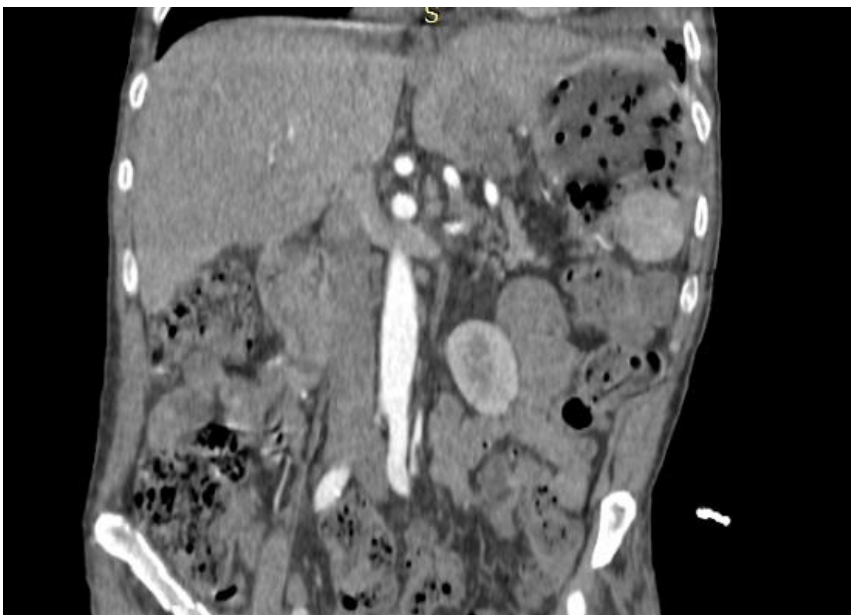
## CASE PRESENTATION

A 61-year-old patient, admitted for severe abdominal pain with signs suggestive of anaphylactic

shock, such as tachycardia, hypotension and generalized erythema. The patient was managed in the intensive care unit. An abdominal CT scan was ordered, which revealed a ruptured calcified splenic wall cyst in the abdominal cavity (Figure 1 & 2). The patient was urgently transferred to the operating room undergoing emergency surgery. During the surgical exploration, a perforated splenic cystic lesion with calcified margins was found with a large number of daughter vesicles released into the abdominal cavity associated with a large peritoneal effusion. A total excision of the cyst and the spleen was performed. The operation was completed by the placement of two drains, one in the splenic cavity and the other in the pelvic cavity, preceded by lavage of the entire abdominal cavity with 12 liters of saline. The intubated patient was transferred postoperatively to the intensive care unit. Despite effective cardiopulmonary resuscitation, the patient, whose general clinical condition deteriorated, died on the second day of postoperative follow-up. Histopathological examination of the surgical specimen showed the lamellar membrane of the hydatid cyst surrounded by fibrosis and a mononuclear inflammatory infiltrate containing multinucleated giant cells.



**Figure 1: Axial contrast-enhanced CT image: Splenic hydatid cyst rupture; free air-fluid labeling seen within the cyst and peritoneal cavity**



**Figure 2: Coronal contrast-enhanced CT image: Splenic hydatid cyst rupture; free air-fluid labeling seen within the cyst and peritoneal cavity**

## DISCUSSION

Echinococcosis infection is the most common cause of liver cysts worldwide [3]. Splenic hydatid cysts usually coexist with hepatic (secondary) hydatid cysts. Splenic infestation usually occurs via the arterial route when the parasite has passed through two other filters: hepatic and pulmonary [4-6]. Hematopoietic stem cells can also develop by retrograde spread from the liver to the spleen via the hepatic and splenic portal veins in patients with portal hypertension. The spleen can also be affected by rupture of a hydatid cyst in the peritoneal cavity [4, 6]. Hydatid cyst of the spleen is either asymptomatic or causes mild left abdominal pain

until complications arise. Perforation of a hydatid cyst into the peritoneum is a rare complication. Different incidence rates of rupture have been reported. The rate of hydatid cyst rupture in the peritoneum is between 1 and 8% in the literature. The intracystic pressure can increase to more than 50 cmH<sub>2</sub>O [7]. High intracystic pressure is a cause of cyst perforation [11]. In our case, the patient's cyst ruptured spontaneously and the main predisposing factors for perforation were young age and superficial location. Another risk factor is the diameter (> 10 cm) of the cyst [7].

The clinical signs and symptoms of hydatid cyst rupture are not always severe, and include

abdominal pain, nausea and vomiting. Hives and macular rashes on the skin may result from an allergic reaction to the cyst contents. Anaphylactic reactions and shock due to rupture of a hydatid cyst are well known serious complications in patients with hydatid disease [5, 6].

Ultrasound is noninvasive and widely used for the diagnosis of hydatid cyst and has acceptable specificity and sensitivity [7]. US and CT were the main diagnostic methods with a sensitivity of 85 and 100%, respectively, to identify hydatid cyst rupture [7]. Ultrasound findings for hydatid cyst rupture include detection of the cyst and identification of the area of inflammation. CT scan is useful and effective in determining the exact site of the cyst and its characteristics [6]. Diagnostic laparoscopy can also be used for the diagnosis of a perforated hydatid cyst.

The surgical methods used for the treatment of hydatid disease are radical (splenic resection) and conservative (deobstruction with various procedures for management of the residual cavity) [1, 7].

Each method has advantages and disadvantages. Cavity-related complications and recurrence are the main problems with conservative methods, but radical procedures have a higher operative risk than conservative procedures [1, 7]. Conservative methods are preferred in endemic areas.

Surgery of a ruptured cyst is more complex than that of non-perforated cysts. This is due to the nature of the ruptured hydatid cyst that requires emergency surgery and contamination of the intra-abdominal cavity with protoscoli. The goal of surgical treatment is to prevent complications, eliminate local disease and minimize morbidity, mortality and recurrence rates [5].

There are no studies on the most effective surgical approach for intraperitoneal hydatid cyst perforation. The morbidity and mortality associated with perforated hydatid cysts are higher than those associated with nonperforated hydatid cysts [9]. Ruptured hydatid cysts require meticulous postoperative follow-up. Although patients with uncomplicated hydatid cysts are followed up with US examination and indirect hemagglutination tests, starting at 6 months after surgery and every 6 months and 1 to 2 years thereafter.

Perforated cysts are followed up at shorter intervals, and CT scanning is included in the recurrence detection procedures [5].

## CONCLUSION

Rupture of hydatid cysts in the peritoneal cavity should be included in the differential diagnosis of acute abdominal pain in endemic areas. Perforation in a young patient may be the first presentation of a hydatid cyst. The presence of multiple hydatid cysts may be a predisposing factor for perforation. Emergency surgery is the main treatment for hydatid cyst rupture, combined with postoperative medical treatment.

## BIBLIOGRAPHIE

1. Ousadden, A., Raiss, M., Hrrora, A., AitLaalim, S., Alaoui, M., Sabbah, F., ... & Ahallat, M. (2010). Kystes hydatiques de la rate: chirurgie radicale ou conservatrice?. *The Pan African Medical Journal*, 5(21).
2. Dirican, A., Yilmaz, M., Unal, B., Tatli, F., Piskin, T., & Kayaalp, C. (2010). Ruptured hydatid cysts into the peritoneum: a case series. *European journal of trauma and emergency surgery*, 36, 375-379.
3. Akbulut, S., Senol, A., Ekin, A., Bakir, S., Bayan, K., & Dursun, M. (2010). Primary retroperitoneal hydatid cyst: report of 2 cases and review of 41 published cases. *International surgery*, 95(3), 189-196.
4. Malik, A. A., ul Bari, S., Younis, M., Wani, K. A., & Rather, A. A. (2011). Primary splenic hydatidosis. *Indian Journal of Gastroenterology*, 30, 175-177.
5. Derici, H., Tansug, T., Reyhan, E., Bozdog, A. D., & Nazli, O. (2006). Acute intraperitoneal rupture of hydatid cysts. *World journal of surgery*, 30, 1879-1883.
6. Čulafić, Đ. M., Kerkez, M. D., Mijač, D. D., Lekić, N. S., Ranković, V. I., Lekić, D. D., & Đorđević, Z. L. (2010). Spleen cystic echinococcosis: clinical manifestations and treatment. *Scandinavian journal of gastroenterology*, 45(2), 186-190.
7. Yalin, R., Aktan, A. Ö., Yeğen, C., & Döşlüoğlu, H. H. (1992). Significance of intracystic pressure in abdominal hydatid disease. *British journal of surgery*, 79(11), 1182-1183.