

Intraorbital Cavernous Hemangioma: Rare Cause of Exophthalmos

Y. Bouktib^{1*}, E. Abidine¹, B. Boutakioute¹, A. El Hajjami¹, F. Amenzouy¹, M. Ouali Idrissi¹, N. Cherif Idrissi El Guennouni¹

¹Service of Radiology, CHU Mohammed VI, Faculty of Medicine and Pharmacy, Cadi Ayyad University, Marrakech, Morocco

DOI: [10.36347/sjmcr.2023.v11i04.072](https://doi.org/10.36347/sjmcr.2023.v11i04.072)

| Received: 09.03.2023 | Accepted: 18.04.2023 | Published: 25.04.2023

*Corresponding author: Y. Bouktib

Service of Radiology, CHU Mohammed VI, Faculty of Medicine and Pharmacy, Cadi Ayyad University, Marrakech, Morocco

Abstract

Case Report

Introduction: Cavernous angiomas or hemangiomas of the orbit are rare vascular tumors. It is a tumor that evolves slowly and respects visual function and ocular motility for a long time. The diagnosis is easily confirmed by imaging which allows to localize perfectly the tumor in relation to the optic nerve and the oculomotor muscles and to dictate the surgical approach. We report a case of orbital cavernous hemangioma revealed by a unilateral exophthalmos occurring in a 56-year-old woman. **Case report:** The patient was a 56-year-old woman with a history of a left orbital tumor operated on 10 years ago. She presented 12 months prior to admission with progressive unilateral left exophthalmos with a homolateral decrease in visual acuity, without any other associated signs. The clinical examination on admission noted a left exophthalmos, irreducible, painless, pulsatile and non-blowing on auscultation without inflammatory signs opposite. Visual acuity was estimated at 6/10 at the OG level and fundus examination showed stage II papilledema on the left. Orbito-encephalic MRI showed an intra- and extra-conical left superior and medial orbital lesion process extended to the canthus, fairly well limited, measuring 40x30x16 mm, with heterogeneous signal, in hyposignal T1, hypersignal T2, seat of diffusion-restricted areas, heterogeneously enhanced after injection of PDC suggestive of a cavernous hemangioma. **Discussion et Conclusion:** Any exophthalmos, especially if it is painful and rapid in onset, should be investigated for an orbital tumor using appropriate imaging. The clinical and radiological picture is quite stereotyped; however, the current means of imaging allow a strong preoperative diagnostic presumption, especially with the advent of MRI, which remains the examination of choice in the exploration of tumor processes of the orbit. En bloc surgical excision represents the treatment of choice for cavernous angioma of the orbit; it generally guarantees satisfactory results both in terms of function and anatomy.

Keywords: Cavernous angiomas, vascular tumors, diagnosis, orbital cavernous hemangioma.

Copyright © 2023 The Author(s): This is an open-access article distributed under the terms of the Creative Commons Attribution 4.0 International License (CC BY-NC 4.0) which permits unrestricted use, distribution, and reproduction in any medium for non-commercial use provided the original author and source are credited.

INTRODUCTION

Cavernous angiomas or hemangiomas of the orbit are rare vascular tumors, representing between 4.5 and 7.4% of all primary and secondary orbital tumors. It is a slowly evolving tumor that respects visual function and ocular motility for a long time. It is well encapsulated and easy to remove surgically. Its name comes from "angios" and "kavernos" meaning respectively vessels and cavity. This perfectly describes the lesion, which is vascular in nature and formed of multiple blood cavities or "caverns" of varying sizes, separated from each other by thin walls. All these elements make the cavernous angioma of the orbit have a good functional and aesthetic prognosis, despite its usually retrobulbar location, most often intraconical, in an area of great anatomical complexity and difficult surgical approach.

We report a case of orbital cavernous hemangioma revealed by an exophthalmos occurring in a 56-year-old woman.

CASE REPORT

This was a 56-year-old woman, without any particular pathological history, who presented 12 months before her admission with unilateral left exophthalmos (Figure 1), of progressive onset with homolateral decrease in visual acuity, without any other associated signs.

On admission, the clinical examination found a conscious patient (GCS 15/15), with no sensory-motor neurological deficit. The ophthalmological examination noted a left exophthalmos, irreducible, painless, pulsatile and non blowing on auscultation without inflammatory signs opposite. Visual acuity was

estimated at 6/10 in the OG and 10/10 in the OD; ocular motility was preserved and fundus examination showed stage II papilledema on the left. The echocardiogram showed a fairly well-limited hypoechoic heterogeneous intra and extra conical orbital lesion formation vascularized by color Doppler with a low resistance arterial flow. Orbital-encephalic MRI showed an intra- and extraconical left superior and medial orbital lesion

process extended to the canthus, fairly well limited measuring 40x30x16 mm, heterogeneous signal, hyposignal T1, hypersignal T2, The lesion was heterogeneously enhanced after injection of the PDC and contained areas of T1 hypersignal that did not fade on the Fatsat sequence and areas of empty T2 signal (hemorrhagic foci or phleboliths) (Figure 2).

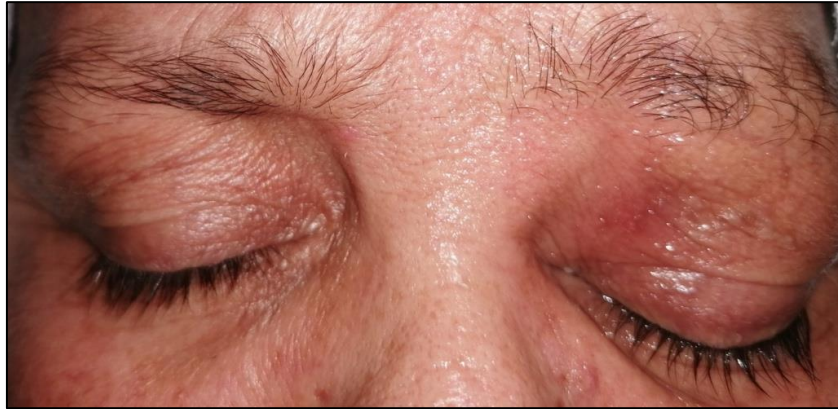

Figure 1: Left exophthalmos in the 56 year old patient

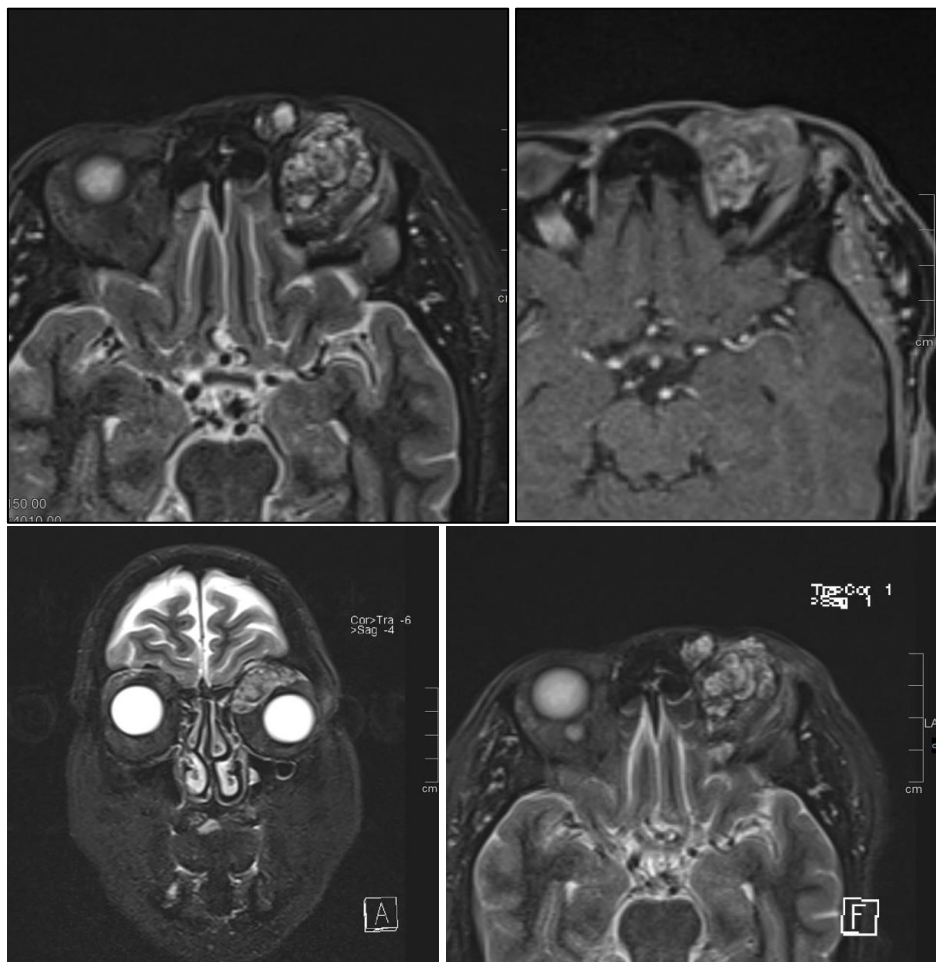


Figure 2: Intra and extra conical lesion process superior and medial left extended to the medial canthus in T1 hyposignal, T2 hypersignal with diffusion restriction seat of areas in signal void on T2* sequence intensely and heterogeneously enhanced after PDC injection in relation to phleboliths suggestive of orbital cavernous hemangioma

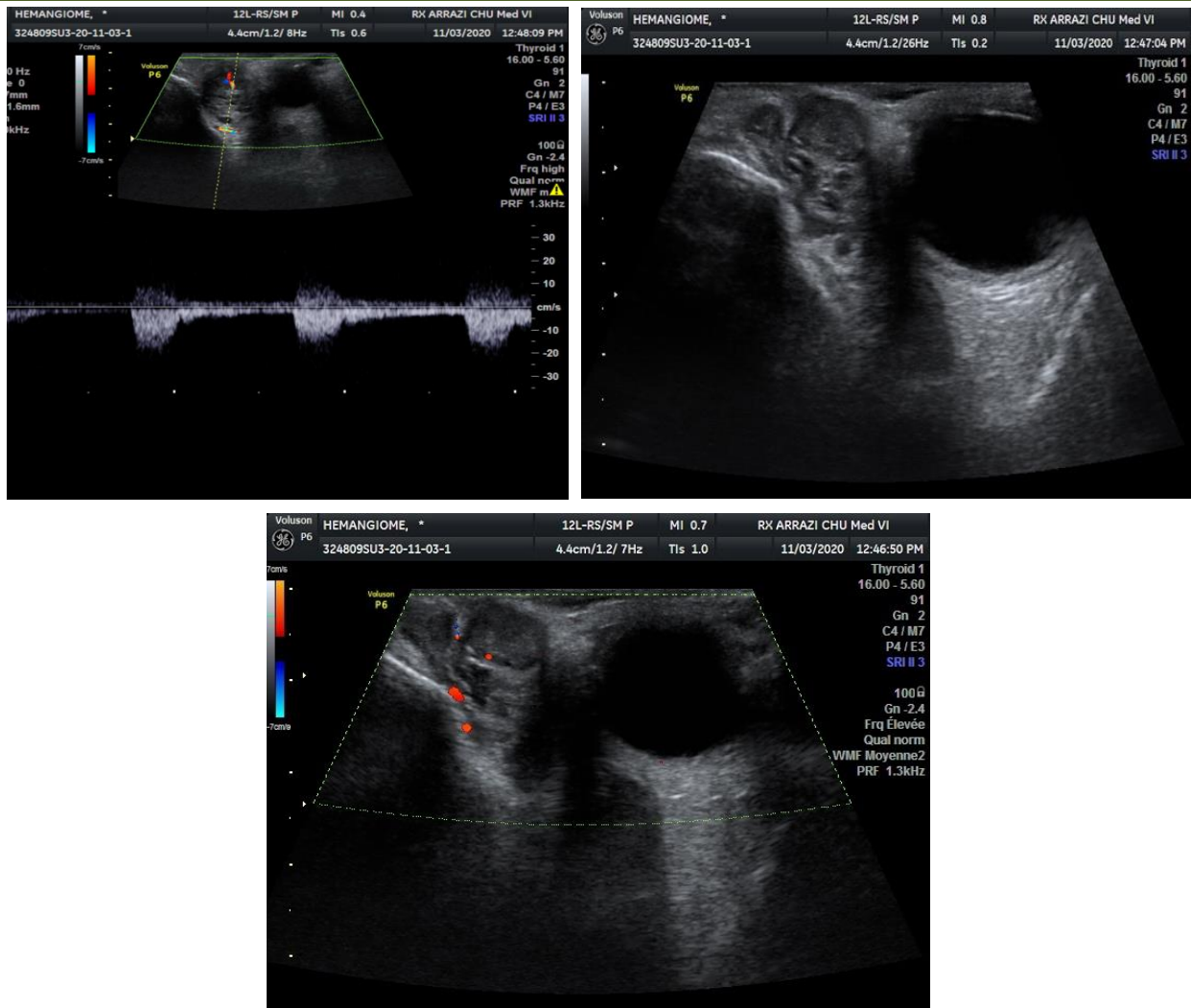


Figure 3: Heterogeneous hypoechoic intra and extra conical orbital lesion formation vascularized by color Doppler with a low resistance arterial flow

DISCUSSION

Hemangiomas are the most frequent benign tumors of the orbit, with a clear female preponderance; the average age of onset is between the 4th and 5th decade of life.

It is a congenital vascular malformation composed of blood lakes located in the intraconical space but which can develop in the extraconical and extraorbital space, most often deep and inaccessible to palpation. This benign tumor has no tendency to regress spontaneously, unlike capillary hemangiomas in children.

Imaging contributes strongly to the diagnosis.

On ultrasound:

Cavernous hemangioma is visible as a homogeneous, well-limited, hyperechoic mass. It shows large vascular spaces containing a slow flow well highlighted by color Doppler ultrasound.

On CT scan:

The lesion is well limited, encapsulated, hyperdense, enhancing slightly after injection, but less than adjacent muscles.

Magnetic resonance imaging:

It must evaluate the possible compressive impact, especially on the optic nerve. The lesion is oval, well limited, creating a "globe behind the globe" aspect. It appears isosignal to the muscles in T1-weighted sequence, strongly hypersignal in T2-weighted sequence, almost liquid, which is strongly suggestive of the diagnosis. Contrast is also characteristic, heterogeneous, giving a "blossoming apple tree" appearance that homogenizes at the late stage (5 minutes).

Surgical treatment is systematic beyond 25 mm in diameter, because of the mass effect on the surrounding structures, especially the optic nerve. Recurrences are exceptional and the risk of malignant transformation is nil.

CONCLUSION

Any exophthalmos, especially if it is painful and rapid in onset, should be investigated for an orbital tumor using appropriate imaging. The clinical and radiological picture is quite stereotyped; however, the current means of imaging allow a strong preoperative diagnostic presumption, especially with the advent of MRI, which remains the examination of choice in the exploration of tumor processes of the orbit. Surgical excision en bloc is the treatment of choice for cavernous angioma of the orbit; it generally guarantees satisfactory results both functionally and anatomically. Any exophthalmos, especially if it is painful and of rapid onset, should be investigated for an orbital tumor using appropriate imaging. The clinical and radiological picture is quite stereotyped; however, the current means of imaging allow a strong preoperative diagnostic presumption, especially with the advent of MRI, which remains the examination of choice in the exploration of tumor processes of the orbit. En bloc surgical excision represents the treatment of choice for cavernous angioma of the orbit; it generally guarantees satisfactory results both in terms of function and anatomy.

BIBLIOGRAPHY

- Héran, F., Lafitte, F., Berges, O., Koskas, P., Nau, E., & Savatovsky, J. (2013). Imaging of orbital lesions. *EMC - Radiology and medical imaging - musculoskeletal - neurological - maxillofacial*, 8(1), 1-27.
- Ducasse, A. (2015). Adult orbital tumors: from clinical signs to treatment. *EMC – Ophthalmology*, 12(2), 1-17.
- Ducasse A. (2016). Tumors of the adult orbit: classification. *EMC - EMC - Radiology and Medical Imaging - musculoskeletal - neurological - maxillofacial*, 11(2), 1-21.
- Desjardins, L. (2013). Tumors of the orbit in children. *EMC – Ophthalmology*, 10(4), 1-14.
- Monteiro, M. L. R., & Sampaio, C. M. (2002). Bilateral orbital involvement in Erdheim-Chester disease: case report. *Arquivos Brasileiros de Oftalmologia*, 65, 675-678.
- Netter, F. Atlas of human anatomy.
- Lemaître, S., Galatoire, O., Zmuda, M., Jacomet, P. V., Putterman, M., Berges, O., & Cassoux, N. (2016). Cassoux. Aneurysmal bone cyst: an exceptional involvement at the orbital level. *Journal Français d'Ophthalmologie*, 39(6), 498-505.
- Louati, H., Hedhli, M., Chebbi, A., Ben Hassine, L., Douira, W., Lahmar, L., Ayed, S., & Bellagha, I. Spontaneous orbital hematoma: about two cases. *Journal Français d'Ophthalmologie*, 35(7)(September 2012), 533.e1-533.e4
- Binatli, O., Yaman, O., Ozdemir, N., & Gokcol Erdogan, I. (2013). Pleomorphic Adenoma of Lacrimal Gland. *Journal of Surgical Case Reports*, 10, rjt089- rjt089.