

Leukemic Retinopathy: A Case Report

Mrad Khalil^{1*}, Robbana Lobna¹, Krichen Med Amine¹, Akennour Younes Serghini Louay¹, Abdallah El Hassan¹, Berraho Amina¹

¹Department of Ophthalmology B, Ibn Sina Hospital, University Mohamed V, Rabat, Morocco

DOI: [10.36347/sjmcr.2023.v11i04.073](https://doi.org/10.36347/sjmcr.2023.v11i04.073)

| Received: 04.02.2023 | Accepted: 25.03.2023 | Published: 28.04.2023

*Corresponding author: Mrad Khalil

Department of Ophthalmology B, Ibn Sina Hospital, University Mohamed V, Rabat, Morocco

Abstract

Case Report

Acute lymphoblastic leukemia is linked to the uncontrolled multiplication of lymphoblasts that invade the bone marrow. This can no longer function correctly and, in particular, ensure the production of normal blood cells, which leads to hyperviscosity, anemia and thrombocytosis, the cause of leukemic retinopathy. This case highlights the importance of recognizing this manifestation of leukemias due to its frequency in this pathology and which can, in certain cases, reveal the disease.

Keywords: lymphoblasts, hyperviscosity, thrombocytosis, leukemias.

Copyright © 2023 The Author(s): This is an open-access article distributed under the terms of the Creative Commons Attribution 4.0 International License (CC BY-NC 4.0) which permits unrestricted use, distribution, and reproduction in any medium for non-commercial use provided the original author and source are credited.

INTRODUCTION

Leukemias are a group of hematologic malignancies that originate from white blood cells (WBCs). These diseases are caused by acquired mutation of hematopoietic stem cells, leading to the replacement of normal bone marrow. Patients with this condition usually present with fatigue, fever, and bleeding. It has been found that up to 90% of patients experience ocular manifestations, affecting all parts of the eye, either before or during the disease course [1].

CASE REPORT

A 16 year old girl with a B-LAL diagnosis in 2021, currently undergoing chemotherapy (esphall protocol) and having received radiotherapy sessions (12 Gray in 8 fractions), presented to our ophthalmology department for a sudden decrease in visual acuity in both eyes over the past 3 days, No other ocular signs were associated. The patient underwent a complete bilateral and symmetrical ophthalmological examination, including OCT imaging and fundus photography. The initial examination revealed visual acuity of 'finger movement' in the right eye and 'counting fingers' in the left eye. Oculomotor, annex and anterior segment examination was normal in both eyes and the ocular tone was also normal. The fundus of the right eye showed an intravitreal hemorrhage preventing examination of the posterior pole. While the fundus of the left eye revealed diffuse retinal hemorrhages in the form of spots and flames in all four quadrants and the

posterior pole particularly marked along the temporal arcades, sparing the fovea, which was the site of dry exudates taking the form of a macular star. The retinal vessels were dilated and tortuous with a normal optic disc and a flat retina (Figure 1).

We decided to closely monitor the patient. One month later, the visual acuity was still at "counting fingers at the left eye" while it was at 4/10 at the left eye. The examination of the right eye fundus showed a clear regression of the intra-vitreous haemorrhage, revealing a retro-hyaloid haemorrhage in front of the posterior pole with exudates surrounding it (Figure 2), with a significant improvement in the left eye fundus which remains the source of a spot haemorrhage below the emergence of the upper temporal arcade and some few scattered haemorrhages, with persistence of macular exudates (Figure 3).

Three months after the first consultation, the visual acuity of the right eye was at 'counting fingers 1 meter' and 4/10 on the left eye. The fundus of the right eye showed the persistence of an intravitreal haemorrhage despite a clear regression, with diffuse cicatricial membranes, as well as a regression of the retro-hyaloid haemorrhage with retro-hyaloid deposits demonstrating the duration of the bleeding (Figure 4). The fundus of the left eye showed a clear improvement with a near normalisation of the fundus. The OCT of the left eye showed a retractile epiretinal membrane with signs of chronicity and panretinal atrophy more

Citation: Mrad Khalil, Robbana Lobna, Krichen Med Amine, Akennour Younes Serghini Louay, Abdallah El Hassan, Berraho Amina. Leukemic Retinopathy: A Case Report. Sch J Med Case Rep, 2023 Apr 11(4): 711-715.

pronounced in the foveolar region (Figure 6). The OCT of the left eye showed an interruption in the IS/OS line in the macular region with a decrease in retinal thickness (Figure 7).

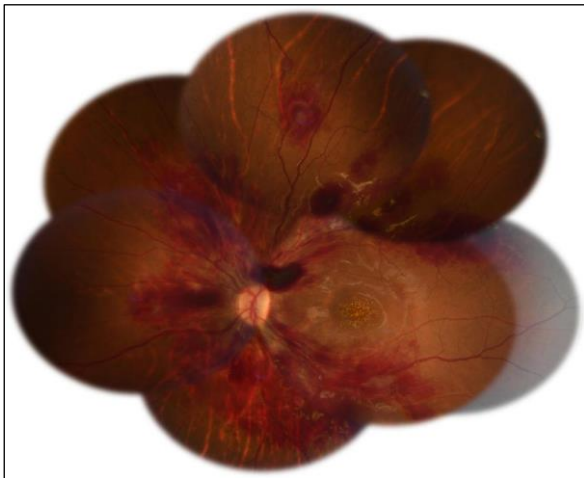


Figure 1: Fundus of the left eye

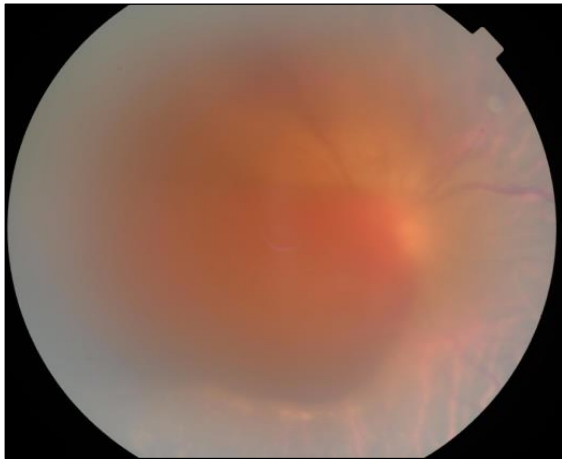


Figure 2: Posterior pole of the right eye

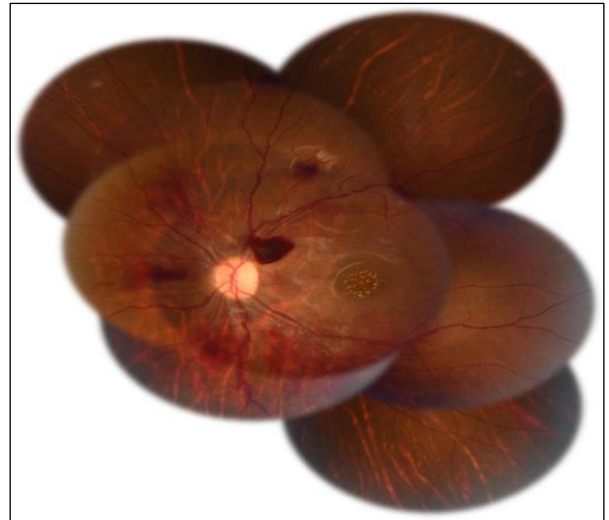


Figure 3: Fundus of the left eye

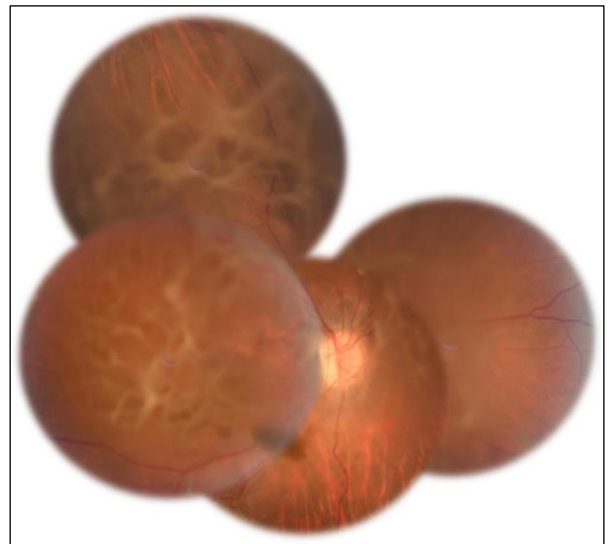


Figure 4: Fundus of the right eye after three months observation

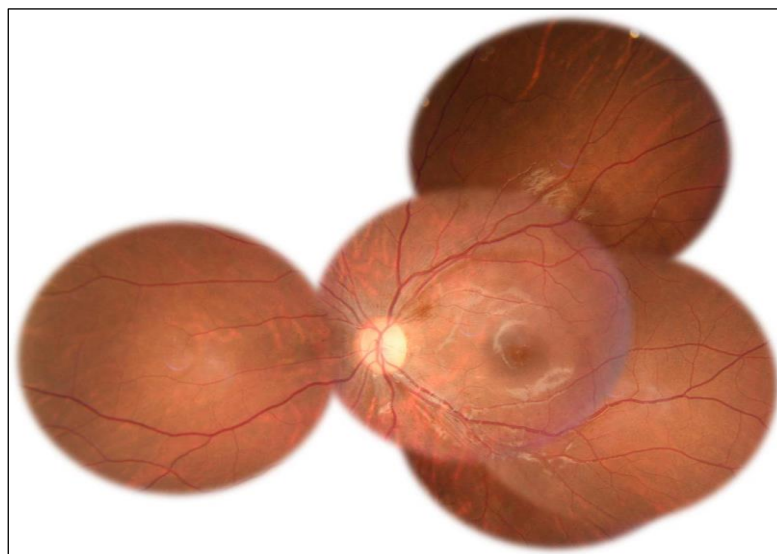


Figure 5: Fundus of the left eye after three months observation

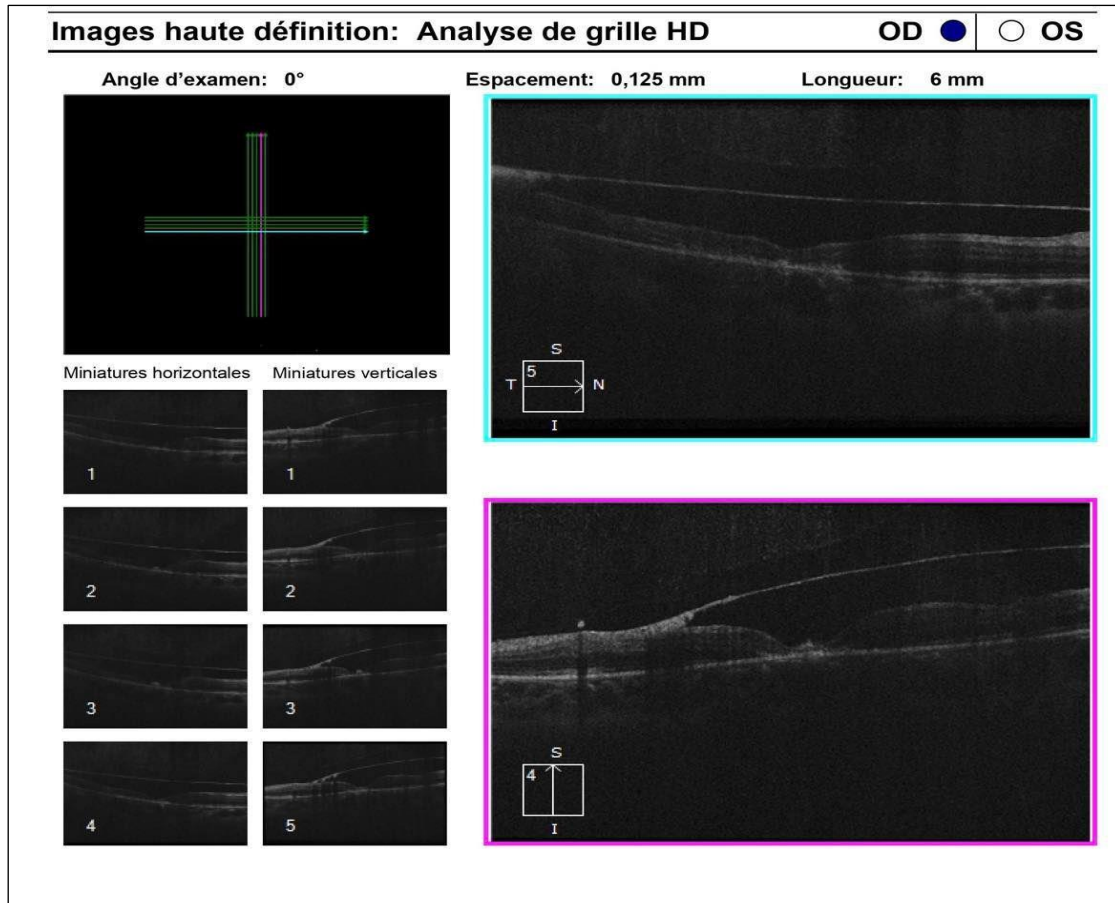
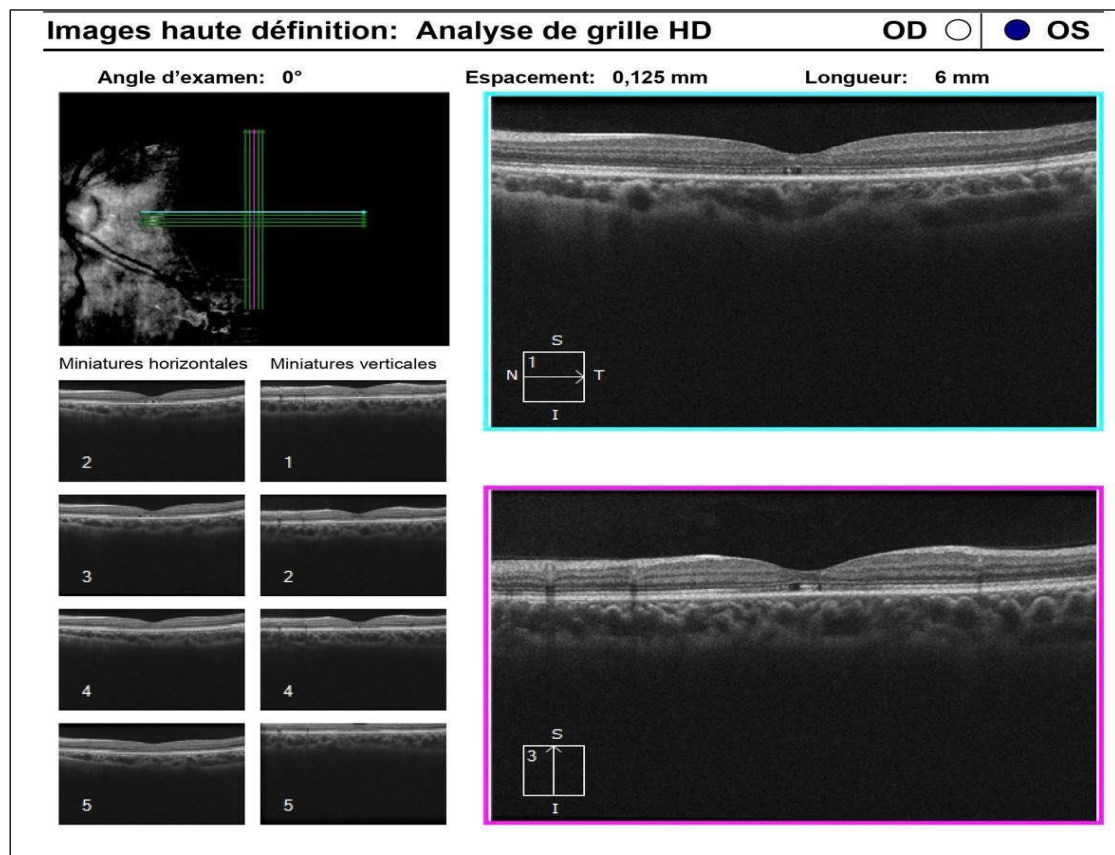


Figure 6: OCT of the right eye after three months observation



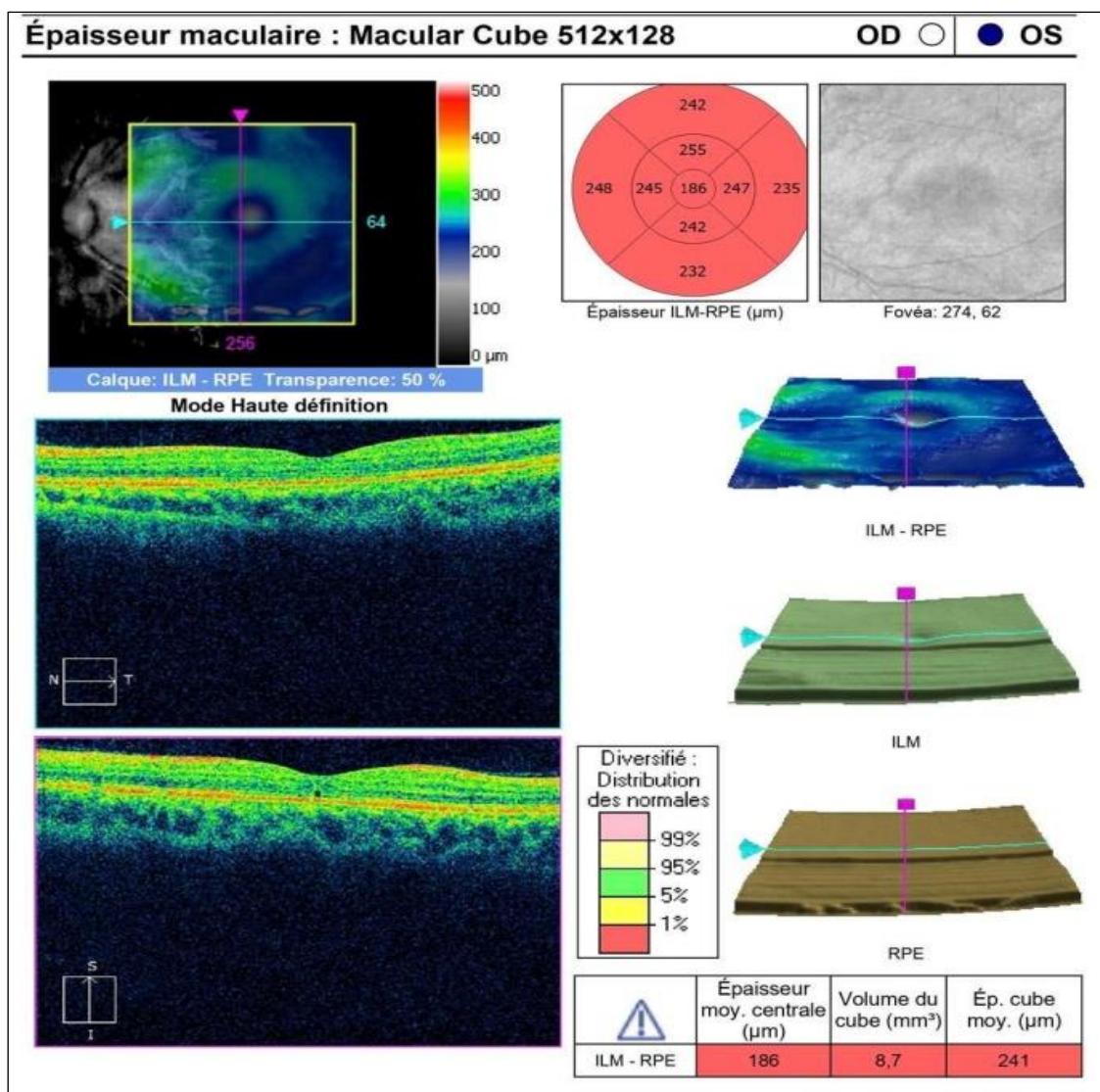


Figure 7: OCT of the left eye after three months observation

DISCUSSION

Understanding the association between leukemia and the eyes is crucial since the eye is the specific area where the disease's effects on blood vessels and neurons may be clearly seen. In 3.6% of patients with the disease conditions, ocular symptoms may potentially serve as the initial form of presentation of leukemia [2]. Ocular complications of leukemia are caused by vascular irregularities affecting the retina (intraretinal hemorrhages, Roth's spots), direct infiltration of the orbit and other tissues (optic nerve, iris, choroid,), or both [1, 3].

Retina is the ocular tissue most commonly affected by hematologic disturbances, with up to 70% of leukemia patients experiencing leukemic retinopathy at some point during the course of their illness [4, 5]. The term 'leukemic retinopathy' is used to describe the retinal manifestations of thrombocytopenia, hyperviscosity and anemia, rather than leukemic infiltration [6]. Leukemic retinopathy is a condition

seen in both acute and chronic leukemia, however it is more commonly observed in acute leukemia [8, 9]. The classic feature of retinopathy is dilated, tortuous retinal veins. These veins may have an irregular caliber and give a sausage-like appearance to the retinal vessels. Indeed, blood hyperviscosity due to major hyperleukocytosis can present as bilateral stasis retinopathy mimicking central retinal vein occlusion; it is related to the slowed circulation that predominantly affects the venous sector and to some degree of hyperviscosity; a true CRVO can then occur [6]. There is often evidence of perivascular infiltration by leukemic cells, referred to as retinal vascular sheathing. Hard exudates and cotton wool spots may be present, which can be indicative of nerve fiber layer infarcts or localized collections of leukemic cells [9]. However, the most obvious observations are the retinal hemorrhages, which are most typically located in the posterior pole at any layer, the hemorrhages can happen at all levels, and are commonly intraretinal, either round or flame-shaped, while it can also take the form of a boat-shaped hemorrhage in the subhyaloid space.

Rarely does this subhyaloid hemorrhage reach into the vitreous, leading to obscuration of observation of the posterior pole. Subretinal hemorrhages are rarely observed. There may be a white component in the intraretinal hemorrhage, which is typically a white dot in the middle of the hemorrhage. These white centers are made up of leukemic cells, capillary emboli, or cellular debris [7]. Moreover, retinal involvement can take the form of bilateral fleshy-pink macular lesions and bilateral foveal infiltrates [10, 11]. Leukemic retinopathy is usually observed when the patient is in relapse and it is believed that it is related to the severe and coexisting anemia [9-12]. It is not related to prognosis [13]. The retinopathy seen in leukemia is not pathognomonic of this disease. Besides it has been reported that symptomatic retinal hemorrhages in leukemia are associated with thrombocytopenia and anemia. These hemorrhages, including visually substantial central sub-ILM hemorrhages, typically heal on their own after a few months of underlying illness treatment [14].

CONCLUSION

This case highlights the importance of recognizing ophthalmic manifestations of acute leukemias, particularly leukemic retinopathy, which can mimic any other ischemic retinopathy, especially since ocular involvement may be indicative of the disease or may herald a relapse. Close collaboration between ophthalmologist and hematologist is essential in order to provide optimal care for the patient and improve their visual and, more importantly, their overall prognosis.

REFERENCES

- Kincaid, M. C., & Green, W. R. (1983). Ocular and orbital involvement in leukemia. *Survey of ophthalmology*, 27(4), 211-232.
- Chaudhuri, T., Roy, S., & Roy, P. (2013). Ischaemic optic neuropathy induced sudden blindness as an initial presentation of acute lymphoblastic leukemia. *Indian Journal of Medical and Paediatric Oncology*, 34(04), 335-336.
- Schachat, A. P. (1994). The leukaemias and lymphomas. Pp 873–890 in S. J. Ryan, ed. *Retina. Basic science and inherited retinal diseases*, Vol. 1, 2nd ed. Mosby, St. Louis.
- Talcott, K. E., Garg, R. J., & Garg, S. J. (2016). Ophthalmic manifestations of leukemia. *Current opinion in ophthalmology*, 27(6), 545-551. <https://doi.org/10.1097/ICU.000000000000309>.
- Sharma, T., Grewal, J., Gupta, S., & Murray, P. I. (2004). Ophthalmic manifestations of acute leukaemias: the ophthalmologist's role. *Eye*, 18(7), 663-672. <https://doi.org/10.1038/sj.eye.6701308>
- Ballantyne, A. J., & Michaelson, I. C. (1970). *Textbook of the fundus of the eye*. London UK: Livingston.
- Gass, J. D. M. (1974). *Differential Diagnosis of Intraocular Tumors; A Stereoscopic Presentation*. St. Louis: CV Mosby, 159-176.
- Younes, S., Abdellaoui, M., Zahir, F., Benatiya, I. A., & Tahri, H. (2015). Occlusion veineuse rétinienne et syndrome d'hyperviscosité. *Pan African Medical Journal*, 20(1). Doi:10.11604/pamj.2015.20.9.5098
- Holt, J. M., & Gordon-Smith, E. C. (1969). Retinal abnormalities in diseases of the blood. *The British journal of ophthalmology*, 53(3), 145-160.
- Finger, P. T., Pro, M. J., Schneider, S., Kurli, M., Shapira, I., & Hu, K. (2004). Visual recovery after radiation therapy for bilateral subfoveal acute myelogenous leukemia (AML). *American journal of ophthalmology*, 138(4), 659-662.
- Rudolph, G., Haritoglou, C., Schmid, I., Hochhaus, F., & Kampik, A. (2005). Visual loss as a first sign of adult-type chronic myeloid leukemia in a child. *American journal of ophthalmology*, 140(4), 750-751.
- Culler, A. M. (1951). Fundus changes in leukemia. *Transactions of the American Ophthalmological Society*, 49, 445-473.
- Mahneke, A., & Videboek, A. (1964). On changes in the optic fundus in leukaemia: aetiology, diagnostic and prognostic role. *Acta Ophthalmologica*, 42(1), 201-210.
- Liu, T. Y. A., Johnson, T. V., Barnett, B. P., & Scott, A. W. (2018). Evolution of leukemic retinal hemorrhages documented by spectral-domain oct and color fundus photography. *Ophthalmology Retina*, 2(5), 494-501.