

## GIST: A Rare Entity with Unusual Presentation

Ankur Gupta\*, Ashish Patel, Shahid Abbas, Ashish Mishra

Post Graduate, Department of medicine, Sri Aurobindo Medical College and post graduate institute, Indore, India

**\*Corresponding author**

Ankur Gupta

**Article History**

Received: 08.01.2018

Accepted: 17.01.2018

Published: 30.01.2018

**DOI:**

10.36347/sjmcr.2018.v06i01.009



**Abstract:** Gastrointestinal stromal tumors are uncommon non epithelial mesenchymal tumors arising from gastro intestinal tract; originating from the interstitial cells of Cajal. These tumors of gastrointestinal tract accounting less than 1% of all gastro intestinal neoplasms. Most commonly they occur in the stomach (60-70%), in the small intestine (25-35%), and in the esophagus, colon and rectum (10% or less). This report describes a case of a GIST arising from the stomach resulting in recurrent anaemia. Early detection of these tumors will results in increased number of successful curative surgical interventions which leads to good prognosis.

**Keywords:** GIST, anemia, upper gastrointestinal endoscopy.

**INTRODUCTION**

Gastrointestinal stromal tumors are uncommon non epithelial mesenchymal tumors arising from gastro intestinal tract; originating from the interstitial cells of Cajal. These tumors of gastrointestinal tract accounting less than 1% of all gastro intestinal neoplasms [1]. Most commonly they occur in the stomach (60-70%), in the small intestine (25-35%), and in the esophagus, colon and rectum (10% or less) [2]. This report describes a case of a GIST arising from the stomach resulting in recurrent anaemia.

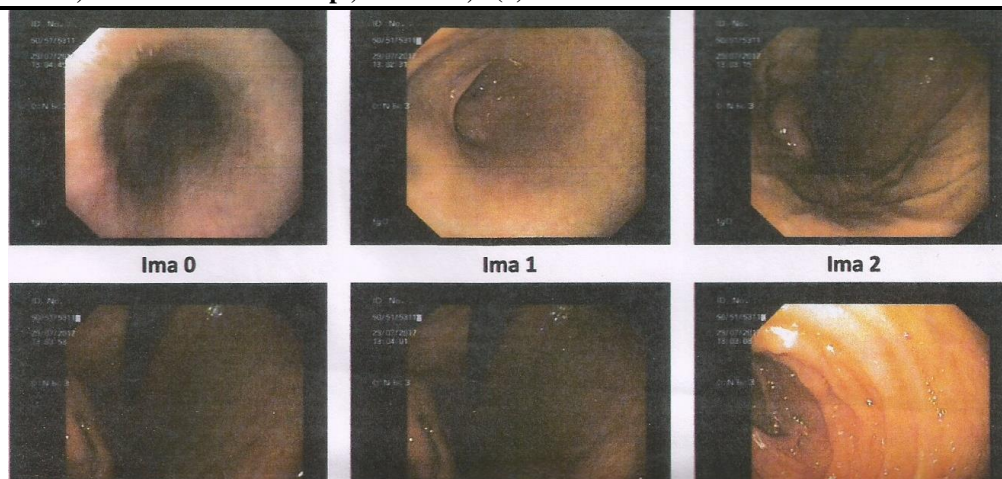
Early detection of these tumors will results in increased number of successful curative surgical interventions which leads to good prognosis.

**CASE PRESENTATION**

A 70 years old lady admitted with the history of generalized weakness and anaemia for two months. She gave history of occasional passage of black stool. There was no history of fever, cough, jaundice, haematemesis, haematuria or any bowel alteration. Her appetite was okay. There was no significant weight loss. Physical examination revealed severe anaemia.

Laboratory findings at admission were as follows: Hb 2 g/dL, ESR 20 mm in 1st hour, complete blood count was otherwise within normal limit,

peripheral blood film showed combined deficiency anemia, blood glucose was normal, liver function tests and renal function tests were normal. Urine routine and microscopy was normal. Stool examination was positive for occult blood but did not show any parasites. She had a normal chest X-ray. Ultrasonography of abdomen revealed absent uterus and fatty liver, otherwise normal study. She had been investigated in similar manner four to five times in last two months with six transfusions but diagnosis remained inconclusive. An upper GI endoscopy was done which showed large polypoidal submucosal lesion involving fundus of stomach with central umbilication suggesting gastrointestinal stromal tumor. (fig-1) 3 units of packed cells were transfused before surgery.



**Fig-1: Large polypoidal submucosal lesion involving fundus of stomach with central umbilication suggesting gastrointestinal stromal tumor**

On exploratory laparotomy, an ulcerated growth was found in the fundus of stomach. The growth with adequate margin was excised and prophylactic oesophagogastrostomy was performed. Postoperative period was uneventful and patient was discharged on 12<sup>th</sup> postoperative day. Histopathology report showed spindle cells arranged in whorls and bundles with prominent nucleus, numerous perinuclear vacuoles that indent nucleus. Immunohistochemical analysis could not be performed due to lack of facilities.

#### DISCUSSION

The main objective of our study is to emphasize on a rare gastro intestinal pathology which causes chronic anemia and to convince that it can be easily misdiagnosed even with extensive investigations. GISTs are a heterogeneous group of diseases that differ in frequency, clinical symptoms and pathologic behavior in patients. Incidence in population of Gastro Intestinal Stromal Tumors is about 2: 100000 [3]. GISTs are low-grade malignant tumors that may arise anywhere in the alimentary tract, and in the past, most of them were diagnosed as intestinal leiomyoma or leiomyosarcoma [4]. Recently, they have been classified as c-kit- or CD34-positive mesenchymal tumors based on immunohistochemical and electromicroscopic approaches [5]. The majority of patients present in the fifth to the seventh decade of life. Although a few studies show a male predominance (2:1)[6,7] most indicate no sex prediction [8-12]. However in our case patient is female.

Small lesions of less than 2 cm are rarely symptomatic and are usually benign, often having been detected incidentally during the investigation of non-specific symptoms. Symptomatic lesions have manifestations that depend on tumor size, growth pattern, and location. When tumors become larger, however, they may stimulate bleeding, abdominal pain, anaemia, abdominal distension or abdominal mass. In our case, the patient complained of recurrent anaemia

due to oozing of blood from overlying mucosal ulceration.

In GIST, there is abnormality in a gene called C-kit gene. This gene is found in all cells of the body. It leads to the formation of a protein called KIT and is usually inactive. In most GISTs the KIT is abnormal and active. This KIT (CD 117) acts as enzyme called tyrosine kinase which is important in the diagnosis and treatment of GIST[2]. Thus GIST can be diagnosed histologically and with immunohistochemistry. Immunohistochemistry CD34 and CD117 are reliable markers. CD117 is positive in 95% of the GISTs and CD34 in 60-80% of GISTs.

Tumors can be submucosal, intramural or subserosal and grossly solid or cystic. Histologically they show a spindle cell or epitheloid pattern [13]. Endoscopic examination characteristically reveals a smooth protrusion of bowel wall lined by intact mucosa, which may show signs of ulceration and or bleeding. Endoscopic ultrasonography (EUS) is a valuable imaging tool for this neoplasm.

The diagnosis of a stromal tumor is based on the demonstration of a hypoechoic mass that is contiguous with the fourth hypoechoic layer (muscularis propria) of the normal gut wall. CT and MRI can also aid in diagnosis to help in determining extent and spread of the disease. Prognostic factors for GISTs are tumor size, mitotic count, and extra gastrointestinal spread[13]. Accordingly they are graded as very low risk, low risk, intermediate risk, and high risk.

Surgery is the mainstay of the treatment. The 5 year survival rate after complete resection of GIST is approximately 50%[14]. Imatinib mesylate is a synthetic tyrosine kinase inhibitor which is shown to be effective in metastatic and inoperable GIST. Various larger trials have confirmed this finding and it is now

considered to be the drug of choice for metastatic and inoperable GIST[2]. Lymph node resection is not routinely performed because leiomyosarcoma does not spread via lymphatics. Recurrence of GIST is usual [15] The liver is the most common site of recurrence. Treatment options for recurrent and metastatic diseases have been limited. Clinical trials have shown that patients benefit from Imatinib therapy [16]

### CONCLUSION

GIST is a rare disease. It is a rare cause for chronic anemia as well. Failure to detect early will case poor prognosis of the patient due to aggressiveness of the disease. Therefore, advocacy and awareness is a must. It needs multidisciplinary approach to obtain successful outcome of the patient.

### REFERENCES

1. Cichoż-Lach H, Kasztelan-Szczerbińska B, Słomka M. Gastrointestinal stromal tumors: epidemiology, clinical picture, diagnosis, prognosis and treatment. *Polish Archives of Internal Medicine* 2008 Apr;118(4):216-21.
2. Whang EE, Ashely SW, Zinner MJ. Small intestine. In: Schwartz IS, Shires GT, Spencer FC (Editors). *Schwartz principles of surgery*, 8th edition. New York; McGraw-Hill Professional, 2004;1038-42.
3. Dhull AK, Kaushal V, Dhankhar R, Atri R, Singh H, Marwah N. The inside mystery of jejunal gastrointestinal stromal tumor: A rare case report and review of the literature. *Case reports in oncological medicine*. 2011 Jul 2;2011.
4. Pidhorechly I, Cheney RT, Lraybill WG, Gibbs JF. Gastrointestinal stromal tumors: Current diagnosis, biologic behavior, and management. *Ann Surg Oncol* 2000;7:705–12
5. Mazur MT, Clark HB. Gastric stromal tumors. Reappraisal of histogenesis. *Am J Surg Pathol* 1983; 7:507–19
6. Conlon KC, Casper ES, Brennan MF. Primary gastrointestinal sarcomas: analysis of prognostic variables. *Ann Surg Oncol* 1995; 2:26 –31.
7. He LJ, Wang BS, Chen CC. Smooth muscle tumours of the digestive tract: report of 160 cases. *Br J Surg* 1988; 75:184–6.
8. Spiliotis J, Scopa CD, Kyriakopoulou D, Pitsis A. Smooth muscle tumors of the gastrointestinal tract: a 10 year experience. *Eur J Surg Oncol* 1992; 17:580–4.
9. Ng E-H, Pollack RE, Romshdahl MM. Prognostic implications of patterns of failure for gastrointestinal leiomyosarcomas. *Cancer* 1991;69:1334–41.
10. Shiu MH, Farr GH, Papachristou DN, Hajdu SI. Myosarcomas of the stomach: natural history, prognostic factors and management. *Cancer* 1982; 49:177–187.
11. Chou FF, Eng HL, Sheen-Chen SM. Smooth muscle tumors of the gastrointestinal tract: analysis of prognostic factors. *Surgery* 1996; 119:171–7.
12. Evans HL. Smooth muscle tumors of the gastrointestinal tract: a study of 56 cases for a minimum of 10 years. *Cancer* 1985; 56:2242–50.
13. Miettien M, Sarlomo-Rikala M, Lasota J. Gastrointestinal stromal tumors. *Ann Chir Gynaecol* 1998;87:278-81
14. Connolly EM, Gaffney E, Reynolds JV. Gastrointestinal stromal tumors. *Br J Surg* 2003;90:1178-86.
15. DeMatteo RP, Lewis JJ, Leung D, Mudan SS, Woodruff JM, Brennan MF. Two hundred gastrointestinal stromal tumors: recurrence patterns and prognostic factors for survival. *Annals of surgery*. 2000 Jan;231(1):51.
16. Demetri GD, Von Mehren M, Blanke CD, Van den Abbeele AD, Eisenberg B, Roberts PJ, Heinrich MC, Tuveson DA, Singer S, Janicek M, Fletcher JA. Efficacy and safety of imatinib mesylate in advanced gastrointestinal stromal tumors. *New England Journal of Medicine*. 2002 Aug 15;347(7):472-80.