

Phenytoin Induced Parkinsonism: A Case Study

Das V*, Benjamin B

Clinical Pharmacist, Apollo Main Hospital, Chennai, India

*Corresponding author: Das V

| Received: 24.12.2018 | Accepted: 04.01.2019 | Published: 30.01.2019

DOI: 10.21276/sajp.2019.8.1.4

Abstract

Case Report

A seizure is a paroxysmal event due to abnormal excessive or synchronous neuronal activity in the brain. Epilepsy is a condition in which the patient has recurrent seizure due to a chronic, underlying process. Parkinsonism is the second common neurodegenerative disorder followed by Alzheimer's disease. The Diagnostic and Statistical Manual of Mental Disorders, fifth edition (DSM-V). Defines Drug Induced Parkinsonism (DIP) as the presence of resting tremor, muscular rigidity, akinesia or bradykinesia developing within few weeks of starting or raising the dose of medication or after reducing the dose of antiparkinsonian agent. A male patient of age 75 years was admitted with complaints of generalized weakness and mild fever for 2 days. While assessing the patient, it was found that the patient has the history of complex partial seizures and is on phenytoin. The drug blood level which was more than the therapeutic level of the drug and the radiologic finding reinforce the findings. The adverse effect was confirmed using Narango's Algorithm and WHO-UMC Causality system. Even though the radiological findings are still persisting, the clinical symptoms have been relieving with the stoppage of drug.

Keywords: Epilepsy, Bradykinesia, Parkinsonism.

Copyright © 2019: This is an open-access article distributed under the terms of the Creative Commons Attribution license which permits unrestricted use, distribution, and reproduction in any medium for non-commercial use (NonCommercial, or CC-BY-NC) provided the original author and source are credited.

INTRODUCTION

A seizure is a paroxysmal event due to abnormal excessive or synchronous neuronal activity in the brain. Epilepsy is a condition in which the patient has recurrent seizure due to a chronic, underlying process. The incidence of epilepsy is 0.3- 0.5% in different populations throughout the world, and the prevalence of the epilepsy has been estimated at 5-10 persons per 1000 [1]. Parkinsonism is the second common neurodegenerative disorder followed by Alzheimer's disease. It is estimated that 5 million person in world and 1million in US suffer from this[1]. The Diagnostic and Statistical Manual of Mental Disorders, fifth edition (DSM-V). Defines Drug Induced Parkinsonism as the presence of resting tremor, muscular rigidity, akinesia or bradykinesia developing within few weeks of starting or raising the dose of medication or after reducing the dose of antiparkinsonian agent. The movement disorder induced by anti-epileptic drugs is frequently of the hyperkinetic variety and Parkinsonism is occurring rarely [7].

CASE PRESENTATION

A 75 year old male patient was admitted with generalized weakness and mild fever for 2 days. History of progressive slowness in Activity of Daily Living (ADL) ~3 months, increased in last 2 days. While asking to the patient it was found that he had history of

skin rash 2 week back and history of hard black stools for 4 days. However the patient did not have history of convulsion, loss of consciousness for past 1year. While asking to the patient it was found that he has known case of type II diabetes mellitus and hypertension for past 14 years. And history of Tuberculoma on Left frontal lobe treated with ATT in 2014 old and diagnosed as complex partial seizures since 2017. Past medication history shows that patient was on Tab. Levetiracetam 500mg twice daily, Tab. Lacosamide 50mg twice daily, Tab. Phenytoin 100mg twice daily and Tab. Benadon 40mg.

Physical examination such as Temperature 98.4°F, Pulse rate 80/min and Blood Pressure 130/80 mm of Hg. Hypomimia is present. Respiratory system shows normal vesicular heart sounds and the functional evaluation shows patient is dependable to do all activities. Central Nervous System evaluation shows the patient is conscious, hypomania, Saccades - Vertical and horizontal slow bradykinesia on appendicular region, stance ataxia, left plantar flexion, neck supple and postural tremor on both hands. Eye examination shows Extra Ocular Movements (EOM) are normal, pupils equal, round, reactive to light (PERLL) and Power - 4+/5, 4+/5 & 4+/5, 4+/5.

Ultrasound whole abdomen showed Grade I fatty liver and increased bilateral renal cortical echoes, left renal simple cyst, diffuse urinary bladder wall thickening and Grade I prostatomegaly. MRI Brain showed chronic infarct in left frontal convexity, chronic ischemic microangiopathic changes and generalized cerebral atrophy.

Hematology shows that Hemoglobin level 11g/dl, WBC 3900cell/mm³, platelet 3.9lakh/mm³ and Random blood sugar 113mg/dl were normal. Liver Function Test shows that Serum Alkaline Phosphatase 128U/L, Albumin 4.5g/dl and globulin 3.3g/dl and renal function test reveals serum creatinine 1.1mg/dl, urea

48mg/dl and uric acid 9.1mg/dl. Blood phenytoin level is 45mcg/ml.

To assess the whether the symptoms that occurs due to toxicity of the drug, we use Naranjo's Adverse Drug Reaction Probability Scale shows a value of 11 and confirmed definite (due to the drug) and WHO-UMC causality assessment system shows certain.

Patient was treated with drugs such as T. Lacosamide 150mg twice daily, T. Phenytoin 100mg twice daily for 15 days thereafter 100mg once daily for 15 days and stop, T. Levetriacetam 1gm twice daily, T. Prucalopride 2mg once daily and T. Febuxostat 40mg twice daily.

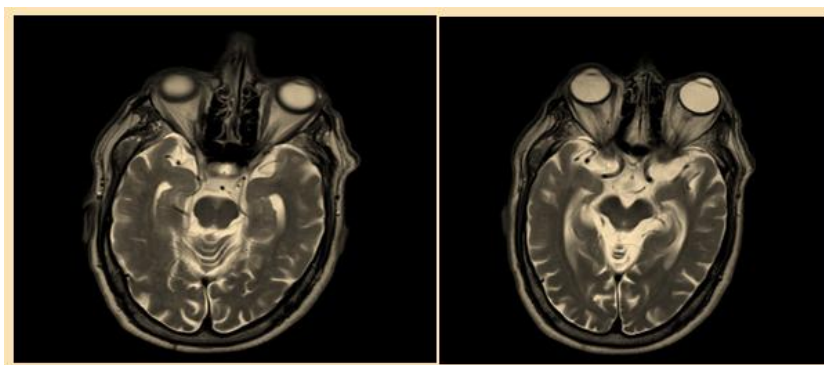


Fig-1: Radiologic images of brain showing chronic infarct in left frontal convexity, chronic ischemic microangiopathic changes and generalized cerebral atrophy

DISCUSSION

In view of its prevalence and expected reversibility upon drug withdrawal, drug-induced Parkinsonism (DIP) has drawn sustained interest for >60 years. Drugs associated with DIP may be classified as neuroleptic versus nonneuroleptic, according to their propensity for causing PS or in terms of the pathogenic mechanism of interference of dopamine neurotransmission. The risks of occurring drug induced were very rare in case of Lithium and anticonvulsant drugs (valproic acid in particular and phenytoin)[3].

The patient was treated with phenytoin for the treatment of complex partial seizures induced by cerebral trabeculoma due to the metastasis of Mycobacterium tuberculosis. To reveal the toxicity, serum Phenytoin level was assessed, having value of 45µg/ml and it exceeds the normal range of 10-20µg/ml. The long term exposure of higher of phenytoin leads to atrophic changes [4]. Radiologic examination shows the presence of cerebral atrophy which is induced by phenytoin [2].

The mechanism of observed toxicity associated with chronic phenytoin administration is unclear but folate deficiency induced by the drug can impair neural function directly [5].

Folate is absorbed from folate polyglutamates, a major component of food folate, with the help of Folate conjugase enzyme which split dietary folate polyglutamates into the simpler folate monoglutamate form and get absorbed. Phenytoin inhibits folate conjugase and thereby inhibits folate absorption producing neuronal damage [6].

CONCLUSION

The patient developed Parkinsonism as a result of phenytoin intoxication. The elevated serum level of the drug and the presence of cerebral atrophy in Magnetic Resonance imaging give strong support to the diagnosis. After the confirmation of diagnosis, patient was advised to stop Phenytoin gradually to reduce the risk of withdrawal symptoms. Even if the radiological findings are still persisting, the clinical symptoms have been relieving with the stoppage of drug.

Study highlights

Drug Induced Parkinsonism may occur due to Diphenylhydantoin class of drugs, eg: phenytoin. The study was done to assess, whether the Parkinsonism and its symptoms having any relation with phenytoin. The use of drug more than the therapeutic level produces Parkinsonism. This will give knowledge about the adverse effects and help clinicians to monitor the symptoms during prescribing of drug.

Author contributions

Das .V, Benjamin B. wrote the manuscript; Das V. designed the research; Das V. performed the research; Benjamin B. analyzed the data.

REFERENCES

1. Anthony S F, Stephen L. Seizures and Epilepsy. Harrison principles of Internal medicine. 19E.Vol 2. 445
2. Ney GC, Lantos G, Barr WB, Schaul N. Cerebellar atrophy in patients with long-term phenytoin exposure and epilepsy. Archives of neurology. 1994 Aug 1;51(8):767-71.
3. Ertan S, Ulu MO, Hanimoglu H, Tanriverdi T, Kafadar AM, Acar ZU, Kiziltan G. Phenytoin-induced parkinsonism. Singapore medical journal. 2006 Nov;47(11):981.
4. Arora M, Boruah DK, Thakker V, Bhanwra S. Imaging in phenytoin induced neurotoxicity: a case series. International Journal of Research in Medical Sciences. 2017 Dec 23;6(1):355-8.
5. Pratima K, Narayan S, Agarwal A. Phenytoin induced cerebellar atrophy: A case report. Panacea journal of medical sciences. 2018; 30;8(1):43-5.
6. Hoffbrand AV, Necheles TF. Mechanism of folate deficiency in patients receiving phenytoin. The Lancet. 1968 Sep 7; 292(7567):528-30.
7. Blanchet P, Kivenko V. Drug-induced Parkinsonism: diagnosis and management. 23 September 2016 ;Volume 2016:6 Pages 83—91.