

Osteoma of External Auditory Canal

Dr. Siddhant Priya Agrawal¹, Dr. Sushil Gauri², Dr. Nehal Vindrani³, Dr. O.N Sinha⁴

^{1,3}Post Graduate Student, ²Assistant Professor, ⁴Head and Professor, Department of ENT, Santosh Medical College and Hospital, Ghaziabad, U.P., India

***Corresponding author**

Dr. Siddhant Priya Agrawal

Article History

Received: 04.01.2018

Accepted: 14.01.2018

Published:30.1.2018

DOI:

10.36347/sjmcr.2018.v06i01.010



Abstract: Osteoma is a benign, slow growing tumour which can arise from various sites in the Temporal bone. Osteomas are benign tumour frequently found in the Fronto-Ethmoid region. In the Temporal bone, External Auditory Canal is the predominant location. Osteomas of the EAC are considered clinically to be discrete, pedunculated lesions arising from the Tympano-Squamous suture. Osteomas of the EAC should be differentiated from Exostosis as they produce the same clinical picture.

Keywords: Osteoma, External Auditory Canal.

INTRODUCTION

Osteomas are bony neoplasms which can be present in the external auditory canal, mastoid cortex, mandible and facial bone [1]. Osteomas are considered as benign lesions as they are non-invasive but can cause significant symptoms due to mass effect and auditory canal obstruction. Chronic irritation, inflammation and pain are the common symptoms which also includes hearing loss, tinnitus and vertigo [2-4].

Osteomas of the EAC are considered clinically to be pedunculated bony lesions arising along the tympano-squamous suture while exostosis of the EAC are broad based elevations of the bone usually multiple and bilaterally symmetrical, including the tympanic bone [5,6].

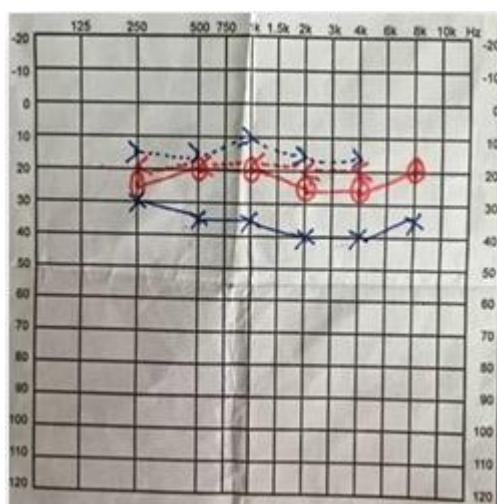


Fig-1: Audiogram showing Mild conductive hearing loss in the Left ear

CASE REPORT

An 18 years old female presented to our hospital with chief complaints of progressive hearing loss in the Left Ear from last 2 months. It was gradually increasing in size. The patient also gave history of intermittent pain and hearing impairment. She had no complaints of otorrhea or otalgia. No episodes of vertigo or tinnitus were encountered.

On Examination of Left external auditory canal, it was completely occluded by a hard mass and covered by wax. Pure Tone Audiometry revealed mild conductive hearing loss in the Left ear and normal hearing in the Right ear.

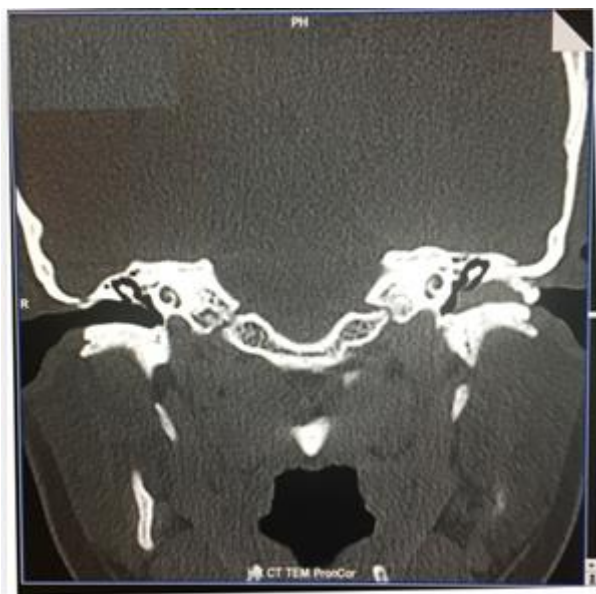

Fig-2: CT – Temporal Bone

CT of Temporal bone revealed 1.8cm * 1.6 cm sized, ovoid mass completely filling and occluding the inner part of the Left bony external auditory canal.

After proper informed consent patient was taken for operation under general anaesthesia. Pinna was retracted anteriorly through classical post auricular incision and skin flap of the posterior canal was created.

The bony mass was removed and sent for histopathological examination. Flap was repositioned, wound closed in layers and EAC packed with soframycin wick. Post-operative period was uneventful and patient was discharged after 2 days. Sutures were removed on the seventh post-operative day. Patient was followed up for 6 months with no recurrence of the disease.

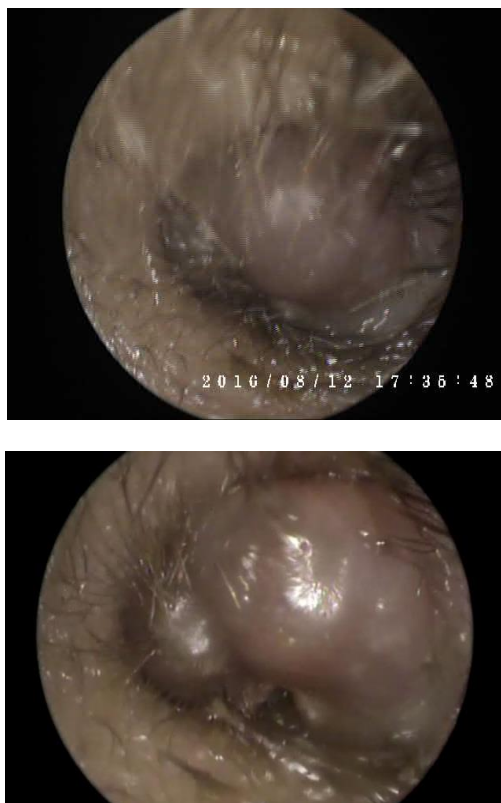


Fig-1 & 2- endoscopic image showing the bony mass in the External Auditory Canal

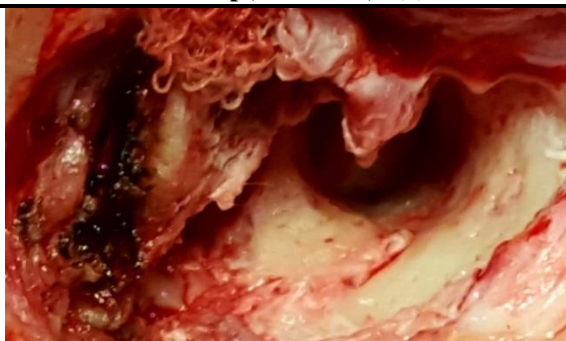


Fig-3: image showing after the excision of the bony mass

DISCUSSION

Temporal bone osteomas are rare entities that can be present in any portion of the temporal bone, among the EAC. The clinical case reported here was diagnosed as External Auditory Canal Osteoma owing to its clinical and radiological characteristics.

Osteoma of the EAC usually arises from the site lateral to the isthmus of the EAC, and its base is located at the tympano-squamous or tympano-mastoid suture lines adjacent to the bony-cartilaginous junction in most of the cases [2, 8, 9]. This was also seen in our case where the osteoma seemed to originate from the posterior superior wall of the canal.

Its incidence peaks in the fourth decade of life, and the male-to-female ratio is 2-3:1. However, in our case the age presentation is in the second decade of life. Although, its aetiology includes trauma, surgery, radiotherapy, chronic infection, and glandular factors such as a pituitary dysfunction, the precise aetiology is still unknown and osteomas are considered to be a true bone tumour [2, 8, 9].

Rarely may they present as an aural polyp as in our case which could be due to reactive changes in the skin overlying the osteoma and association of the osteoma with a cholesteatoma is extremely rare [10,11]. The main treatment for an EAC osteoma is a surgical excision. The size and location of the osteoma as well as the severity of the symptoms determine the treatment [12]. The major surgical challenges of removing obstructive EAC osteoma are related to the proximity of the temporo-mandibular joint, facial nerve injury, inability to visualize the medial EAC landmarks, the thin skin covering the osteoma and contact with the tympanic membrane.

Controversy exists as to whether EAC exostosis and osteomas should be considered similar or separate histopathologic entities [13].

Osteomas are usually solitary, pedunculated lesions attached to the tympano-squamous or tympano-mastoid suture lines, whereas exostosis is usually multiple, bilateral, broadly-based elevations of bone. Exostosis is relatively common as compared to the

osteoma. Osteomas are considered to be the true bone tumours and exostosis is thought to be a reactive condition secondary to multiple cold-water immersions or recurrent otitis externa [14,15].

CONCLUSION

Preliminary diagnosis of the left EAC osteoma was made. The decision was taken to remove the osteoma surgically through the post-auricular approach. It was confirmed that the origin of the osteoma was the posterior wall of the EAC. Removal of the osteoma was performed through the pedicle to avoid recurrences. Histopathological examination of the removed mass was made to rule out the similar conditions. It showed proliferation of the lamellar bone with fibro-vascular core and the bone surrounded by thick cortex. Hence, the diagnosis of the left external auditory canal Osteoma was confirmed.

REFERENCES

1. Liétin B, Bascoul A, Gabrillargues J, Crestani S, Avan P, Mom T, Gilain L. Osteoma of the internal auditory canal. *European annals of otorhinolaryngology, head and neck diseases*. 2010 Mar 31;127(1):15-9.
2. Orita Y, Nishizaki K, Fukushima K, Akagi H, Ogawa T, Masuda Y, Fukazawa M, Mori Y. Osteoma with cholesteatoma in the external auditory canal. *International journal of pediatric otorhinolaryngology*. 1998 May 15;43(3):289-93.
3. Gerganov VM, Samii A, Paterno V, Stan AC, Samii M. Bilateral osteomas arising from the internal auditory canal: case report. *Neurosurgery*. 2008 Feb 1;62(2):E528-9.
4. Denia A, Perez F, Canalis RR, Graham MD. Extracanalicular osteomas of the temporal bone. *Archives of Otolaryngology*. 1979 Dec 1;105(12):706-9.
5. Fenton JE, Turner J, Fogan PA. A histopathologic review of temporal bone exostosis and osteoma. *Laryngoscope* 1996; 106:624-28
6. Graham MD. Osteoma and exostosis of external auditory canal: a clinical histopathological and scanning electronic microscopic study. *Ann otol Rhinol laryngol* 1979; 88: 566-572
7. Baik FM, Nguyen L, Doherty JK, Harris JP, Mafee MF, Nguyen QT. Comparative case series of

- exostoses and osteomas of the internal auditory canal. *Annals of Otolology, Rhinology & Laryngology*. 2011 Apr;120(4):255-60.
8. Gungor A, Cincik H, Poyrazoglu E, Saglam O, Candan H. Mastoid osteomas: report of two cases. *Otology & Neurotology*. 2004 Mar 1;25(2):95-7.
 9. Tran LP, Grundfast KM, Selesnick SH. Benign lesions of the external auditory canal. *Otolaryngologic Clinics of North America*. 1996 Oct;29(5):807-25.
 10. Shenoy P, Paulose KO, Khalifa SA, Sharma R. Osteoma of the ear canal presenting with headache. *The Journal of Laryngology & Otology*. 1989 Jul;103(7):683-4.
 11. Orita Y, Nishizaki K, Fukushima K, Akagi H, Ogawa T, Masuda Y, Fukazawa M, Mori Y. Osteoma with cholesteatoma in the external auditory canal. *International journal of pediatric otorhinolaryngology*. 1998 May 15;43(3):289-93.
 12. Ben-yaakov A, Wohlgelernter J, Gross M. Osteoma of the lateral semicircular canal. *Acta Otolaryngol* 2006; 126: 1005-1007
 13. Pulec JL, Denguine C. Osteomas of the external auditory canal. *Ear Nose Throat J*. 1993; 72:112
 14. Michaels L. Neoplasms of the external ear. In: *Ear, Nose and Throat Histopathology*. London: Springer-Verlag; 1987; 63-65
 15. Bilkay U, Erdem O, Ozek C, Helvacj E, Kilic K, Ertan Y, Gruler Benign osteoma: review of the literature and report of a case. *J Craniofacial Surg* 2004; 15:506-09.