

Cedacea Davisae from ET Culture – A Rare Isolate

Shabnum M*, Vasundhara P, Sreenivasulu Reddy P

Department of Microbiology, Narayana Medical College, Nellore, Andhra Pradesh, India

***Corresponding author**

Shabnum M

Article History

Received: 03.03.2018

Accepted: 18.03.2018

Published: 30.03.2018

DOI:

10.36347/sjmcr.2018.v06i03.014



Abstract: Cedacea davisae is a gram negative bacilli belonging to Enterobacteriaceae Enteric Group 15. There are very cases reported so far caused by different species of Cedacea genus. Advanced automated laboratory diagnosis uncovered a possible role of such emerging pathogen in disease presentation. In this paper, we report a case of pleural effusion in a 36 year old Male Patient who is a K/C/O CKD since 10 years, presented with Cough and Shortness of Breath since 3days. USG, CBC, RFT, ET culture were done. Cedacea davisae was isolated and the patient was successfully treated with Ciprofloxacin and TMP/SMX. Cedacea infection can be difficult to treat due to wide range of antibiotic resistance displayed by the bacterium. Laboratory antibiotic sensitivity tests guided treatment with combination therapy should be considered for treatment such infection.

Keywords: Cedacea davisae, Chronic Kidney Disease, Respiratory Tract Infection, ET cultures.

INTRODUCTION

Cedacea are gram negative, oxidase negative bacilli that include 5 species. This Genus was designated by Centers for Disease Control (CDC) in 1981 as a separate genus in the Enterobacteriaceae as Enteric Group 15. Though Cedacea are closely related to Serratia, it differs from it by not hydrolyzing DNA or gelatin [1].

Over the years there are very few Cedacea infections reported ranging from bacteremia, sepsis, pneumonia, UTI, Atrophic rhinitis, soft tissue infections [2].

In most of the reported cases, the patients had multiple co morbidities or were immunocompromised. In this present case report, we describe a case of pleural effusion caused by Cedacea davisae in a patient with Chronic Kidney Disease Stage V [2, 3].

CASE REPORT

A 36year old male patient with Chronic Kidney Disease Stage V with history of hypertension on Hemodialysis treatment since 10 years was brought to Emergency Department, Narayana Medical College, Nellore, on 29th September 2017 with complaints of bilateral pedal edema, facial puffiness, productive cough and shortness of breath since 3 days. He was admitted in Nephrology Department with a suspicion of CKD with Lower respiratory tract Infection.

On examination, patient was hemodynamically stable with blood pressure of 130/90mmHg and Temperature of 98.4^oF and Crepitations in left basal region. His CBC revealed 10,800 cells/ cumm with 81% neutrophils. USG revealed bilateral moderate pleural effusion with collapse / consolidation of underlying

lung parenchyma and Grade III renal parenchymal changes. Serum urea was 129.3mg/dl and serum creatinine levels were 12.85mg/dl

On day 2, the patient's condition suddenly deteriorated and patient became unresponsive. He was on mechanical ventilation with vasopressor support and shifted to ICU with BP of 210/140 mmHg and pulse rate 153/min. 2D ECHO revealed LVD with LVEF 20%. On day 3, ET secretions were sent for culture and sensitivity to Microbiology Laboratory. The ET secretions were culture positive with gram negative bacilli growth on blood agar, Chocolate agar and MacConkey agar (Figure-1). These bacilli were confirmed as Cedacea davisae by automated microbial identification and susceptibility system VITEK 2 (BioMerieux, Durham, NC). The bacteria were resistant to most of the antibiotics including Colistin but susceptible to only a few antibiotics like Amikacin, Ciprofloxacin, Tigecycline and TMP/SMX. Susceptibility testing was performed based on CLSI guidelines. The treatment was started with Ciprofloxacin and TMP/SMX following which the patient improved. He came off vasopressors and was transferred back to Hemodialysis unit. The patient was discharged home in a stable state with a recommendation of continuing treatment for a total of 10 days.

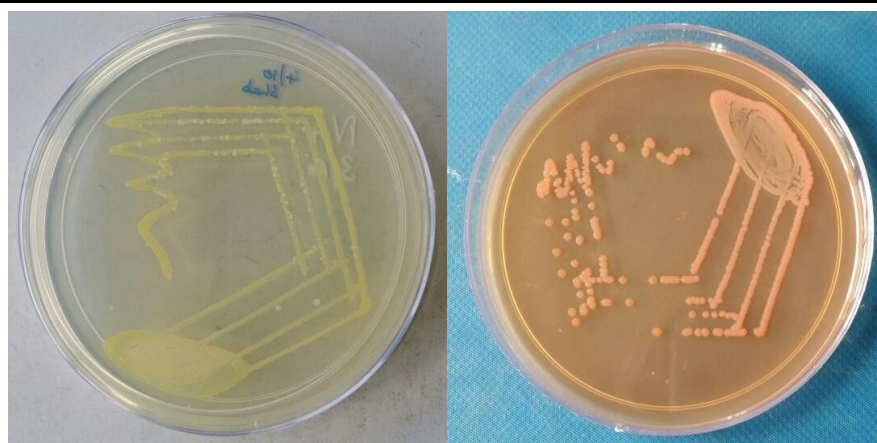


Fig-1: Growth on (a) Nutrient Agar, (b) MacConkey Agar

DISCUSSION

Cedacea is a genus of Enterobacteriaceae with 5 species identified: *C. davisae*, *C. lapagei*, *C. neteri*, Species 3, Species 5 [4, 5]. Morphologically *C. davisae* is a motile gram negative bacillus, oxidase positive,

utilizes citrate, blackens esculin agar, lipase positive, ferments maltose, mannose, sucrose, xylose with production of gas. *C. davisae* can be distinguished from other species of *Cedacea* by its ability to decarboxylate Ornithine.

Reported Cases of Cedacea davisae infections

S.No	Infection Course	Sample	Co morbidities	Age/Sex	Susceptibility of tested drugs	Year
1	Inpatient; Pneumonia	Sputum	DM, HTN, CHF	65/F	Amikacin, Carbenicillin, Chloramphenicol, TMP/SMX, Tetracycline	1981[6]
2	Inpatient; Pneumonia	Sputum	HTN, Arteriosclerosis	76/M	Amikacin, Carbenicillin, Chloramphenicol, TMP/SMX, Tetracycline	1981[6]
3	Inpatient; Scrotal abscess	Abscess	HTN, alcoholic hepatitis, CHF	50/M	Ampicillin, Cephalothin, Carbenicillin, Tetracycline, Aminoglycosides	1983[7]
4	Inpatient; DIC; CRBSI	Blood	COPD, CHF	70/M	Aminoglycosides, Cefotaxime, Cefoperazone, Piperacillin	1986[8]
5	Inpatient, Pneumonia	Sputum	CF, DM	20/F	TMP/ SMX only	2012[3]
6	Inpatient, Febrile with chills, Vomiting, Diarrhoea	Blood, Permacat Catheter tip	DM, HTN, Chronic Renal Disease	77/ M	Amikacin, Ceftazidime, Ciprofloxacin, Gentamicin, Meropenem, TMP/SMX, Levofloxacin	2013[2]
7	OPD, Atrophic Rhinitis	Sinus discharge	Nil	57/F	Levofloxacin	2015[9]
8	Inpatient, Cough, SOB, Hemodialysis	ET aspirate	HTN, CKD	36/ M	Amikacin, Tigecycline, Ciprofloxacin, TMP/SMX	2017 (Current Case)

Aqueous bodies act as environmental reservoirs for *Cedacea* species. Though the bacterium has been isolated from a wide range of specimens like sputum, blood, abscess, catheter tips, infections due to these bacteria are rare[1,3].

Among the above compared cases, all affected patients had either multiple co morbidities or were immunocompromised suggesting *Cedacea* may be an

opportunistic pathogen. Even with wide multidrug resistance pattern exhibited by the organism, the outcomes were favorable with the therapies given.

CONCLUSION

We report the 1st case of isolation of *Cedacea davisae* from ET secretions with sensitivity to Amikacin, Tigecycline, Ciprofloxacin and TMP/SMX. Our case high lightens the increasing emergence of

Cedacea species as a potential opportunistic organism in patients with co morbidities. Further work is required to identify the bacteria's etiological role, mode of transmission, disease spectrum and treatment modalities [3].

ACKNOWLEDGEMENT

The authors are deeply indebted to the patient for allowing them to present the details of his case.

REFERENCES

1. Koneman EW. *Textbook of Diagnostic Microbiology*. 6th Edition.
2. Peretz A, Simsolo C, Farber E, Roth A, Brodsky D, Nakhoul F. A rare bacteremia caused by *Cedecea davisae* in patient with chronic renal disease. *The American journal of case reports*. 2013; 14:216.
3. Ismaael TG, Zamora EM, Khasawneh FA. *Cedecea davisae*'s role in a polymicrobial lung infection in a cystic fibrosis patient. *Case reports in infectious diseases*. 2012; 2012.
4. GRIMONT PA, GRIMONT F, FARMER III JJ, ASBURY MA. *Cedecea davisae* gen. nov., sp. nov. and *Cedecea lapagei* sp. nov., new Enterobacteriaceae from clinical specimens. *International Journal of Systematic and Evolutionary Microbiology*. 1981 Jul 1;31(3):317-26.
5. Lopez LA, Ibarra BS, Garza JA, Rada FD, Nuñez AI, López MG. First reported case of pneumonia caused by *Cedecea lapagei* in America. *Brazilian Journal of Infectious Diseases*. 2013 Oct; 17(5):626-8.
6. Bae BH, Sureka SB, Ajamy JA. Enteric group 15 (Enterobacteriaceae) associated with pneumonia. *Journal of clinical microbiology*. 1981 Nov 1; 14(5):596-7.
7. Bae BH, Sureka SB. *Cedecea davisae* isolated from scrotal abscess. *The Journal of urology*. 1983 Jul 1; 130(1):148-9.
8. Perkins SR, Beckett TA, Bump CM. *Cedecea davisae* bacteremia. *Journal of clinical microbiology*. 1986 Oct; 24(4):675.
9. Bayır Ö, Gökçe Aksoy Yıldırım MD, Saylam G, Yüksel E, Özdek A, Korkmaz MH. Atrophic rhinitis caused by *Cedecea davisae* with accompanying mucocoele. *Kulak Burun Bogaz Ihtis Derg*. 2015;25(4):249-53.