

## An Unusual Localization of Cutaneous Squamous Cell Carcinoma

Kaoutar Laamari\*, Hanane Baybay, Ibtissam Assenhaji, Asmae Rasso, Zakia Douhi, Sara Elloudi, Fatima Zahra Mernissi

Department of Dermatology, CHU Hassan II, Fès, Maroc

### \*Corresponding author

Kaoutar Laamari

### Article History

Received: 07.06.2018

Accepted: 18.06.2018

Published: 30.06.2018

### DOI:

10.36347/sjmcr.2018.v06i06.013



**Abstract:** Squamous cell carcinoma is a frequent and invasive skin cancer, which occurs in exposed photo areas, but may occur in hidden photo areas, especially in dark skin. We report the case of a young man of 40 years, who had a tumor in the left buttock of 25 cm diameter ulcero-budding. This unusual localization lesion had been evolving for two years. A biopsy-excision was performed. Histological examination revealed cutaneous squamous cell carcinoma. The evolution was marked by the extension of the tumor and the alteration of the patient.

**Keywords:** carcinoma, biopsy-excision, skin cancer.

### INTRODUCTION

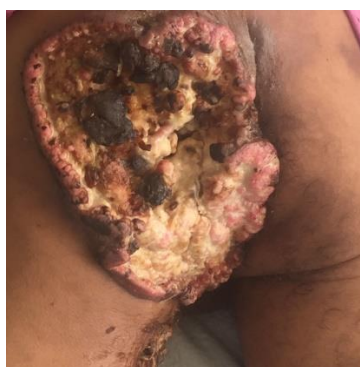Skin squamous cell carcinoma (SCC) is one of the most common skin cancers and most commonly occurs in exposed photo regions. It is prevalent in men and increases with age [1]. The incidence of SCC is increasing today with the frequency of UV exposure associated with lifestyle changes and the destruction of the ozone layer. It is likely to become metastatic [2]. The location in the unexposed areas is atypical. Among these, the perianal region remains extremely rare. Here, we report a case of massive SCC of the left buttock in a young subject.

### CASE REPORT

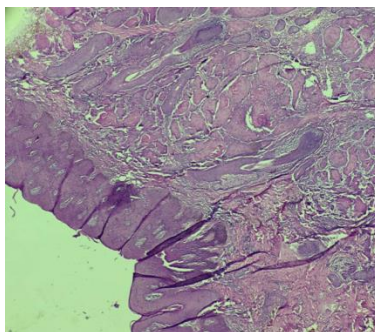
He was a 40-year-old patient with no notable pathological history. He had a bulky mass on his left buttock evolving for 2 years.

Dermatological examination revealed the presence of an ulcer-budding tumor invading the entire left buttock of about 25 cm long axis, well-defined, with irregular contours necrotic surface in place and fibrinous by others with pus at the pressure (Figure 1). The rest of the somatic examination showed bilateral supra-centimeter inguinal lymphadenopathy fixed in relation to the deep plane. Computed tomography (CT) showed that the mass invaded the sacrum as well as the posterior wall of the left thigh and the bilateral inguinal lymph nodes. No visceral metastasis was detected. Histologically, it was a well-differentiated carcinomatous tumor proliferation of trabecular

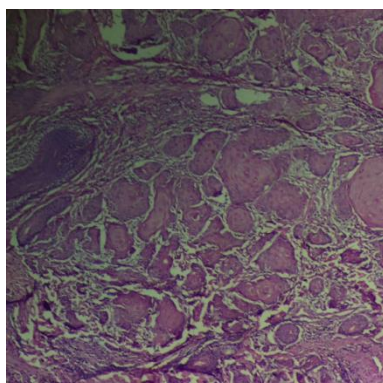
architecture within a fibro-inflammatory tumor stroma. Tumor cells were large, polygonal, with marked cytonuclear atypias. Several figures of mitosis were present. Signs of squamous maturation in the form of horny globes were noted, with no vascular emboli or perineural engulfment. (Figure 2,3) The treatment consisted of performing clean surgery, followed by radiotherapy sessions. However, the patient was lost sight of and the evolution consisted of a massive extension of the tumor (Figure 4) and an important alteration of the general state of the patient. Palliative chemotherapy has been introduced.



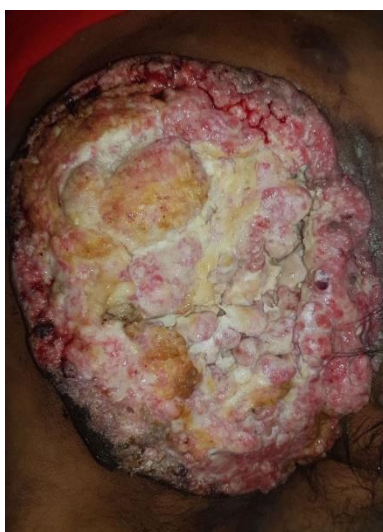**Fig-1: Well-defined ulcero-budding tumor about 20 cm long with necrotic surface in places and fibrinous by other**



**Fig-2 :** Histological section showing a well-differentiated carcinomatous tumor proliferation of trabecular architecture within a fibroinflammatory tumor stroma



**Fig-3:** Higher magnification, Tumor cells are large, polygonal, with marked cytonuclear atypias. Signs of squamous ripening in the form of horny globes were noted



**Fig-4:** Evolution after 6 months: Ulcero-budding tumor with fibrinous surface taking the entire left buttock

## DISCUSSION

The peculiarity of our observation lies in two points which are the origin of the tumor and also the importance of its infiltration and its extension. Because the buttock is not a sun-exposed site and our patient was relatively young, unlike patients with SCC, finding the origin of this tumor was important [3]. The clinical picture prompted us to look for another primitive location, but the para-clinical examinations did not reveal it. The interrogation of the patient and his family revealed the absence of primary lesion at this site. To

date, no case has been published in the literature of squamous cell carcinoma de novo at this site, and the few reported cases have occurred in papilliform syringocystadenoma [3]. It is a benign and rare tumor of the apocrine sweat glands or less often eccrine sweat glands. It mainly affects the head, face, neck and trunk, but also the perianal area [4] and may, however, go unnoticed, which may be the case of our patient. Regarding the second point, the large and rapid extension of the tumor in a young subject made us look for a sarcomatous origin, but the histology confirmed

the diagnosis of SCC. Thus, the management of these patients must be done quickly and surgery remains the best tool available to avoid reaching the stage of metastasis. Chemoradiotherapy treatment after palliative surgery may be an effective treatment for major SCC, as demonstrated by Megumi Nishioka *et al.* [3].

### **CONCLUSION**

Cutaneous squamous cell carcinoma remains an invasive skin cancer, the management of which must be urgent. The education of the patient on the importance of self-control and consultation in front of the appearance of any cutaneous lesion is necessary, and a sensitization with the dermatologists as well as the population is important to recall the possibility of particular localization especially the buttock, and therefore avoid advanced stages as the case of our patient.

### **REFERENCES**

1. Baum C, Bordeaux JS, Brown M, Busam KJ, Eisen DB, Iyengar V, Lober C, Margolis DJ, Messina J, Miller A, Miller S. Guidelines of care for the management of basal cell carcinoma. *Journal of the American Academy of Dermatology*. 2018 Jan 10.
2. Frank P and Bridget H. "Pyoderma gangrenosum," in *Fitzpatrick's Dermatology in General Medicine*, Klaus W, Lowell G, Stephen K, Barbara G, Amy P, and David L, Eds, pp. 1028–1036, McGraw-Hill, Columbus, Ohio, USA, 7th edition, 2008.
3. Nishioka M, Tanemura A, Yamanaka T, Umegaki N, Tani M, Katayama I, Takemasa I, Sekimoto M, Tomita K, Tamai N. A case of giant squamous cell carcinoma of the buttock possibly arose from syringocystadenoma and invaded to the rectum. *Journal of skin cancer*. 2011;2011.
4. Rammeh-Rommani S, Fezaa B, Chelbi E, Kamoun MR, Jilani SB, Zermani R. Syringocystadénome papillifère de localisation inhabituelle. In *Annales de dermatologie et de venerologie* 2006 Mar 1 (Vol. 133, No. 3, pp. 301-302). Elsevier Masson.