

Fibrous Dysplasia Involving Maxillary Sinus: A Rare Case Report**Dr. Devika Singh^{1*}, Dr. Rakesh Kumar Singh², Dr. Sarita Kumari Mishra³, Dr. Sanjay Kumar⁴, Dr. Nivedita⁵, Dr. A.K. Sharma⁶, Dr. Navin Mishra⁷**¹Senior Resident, Oral Medicine and Radiology, Department of Dentistry, Indira Gandhi Institute of Medical Sciences, Patna India²Professor and Head, Department of ENT, Indira Gandhi Institute of Medical Sciences, Patna India³Assistant Professor, Department of ENT, Indira Gandhi Institute of Medical Sciences, Patna India⁴Additional Professor, Orthodontics and Dentofacial Orthopaedics, Department of Dentistry, Indira Gandhi Institute of Medical Sciences, Patna India⁵Senior Resident, Paedodontics and Preventive Dentistry, Department of Dentistry, Indira Gandhi Institute of Medical Sciences, Patna India⁶Professor and Head, Periodontology, Department of Dentistry, Indira Gandhi Institute Of Medical Sciences, Patna India⁷Assistant Professor, Conservative Dentistry and Endodontics, Department of Dentistry, Indira Gandhi Institute Of Medical Sciences, Patna India***Corresponding author***Dr. Devika Singh***Article History***Received: 03.07.2018**Accepted: 19.07.2018**Published: 30.08.2018***DOI:**

10.36347/sjmcr.2018.v06i08.002



Abstract: Benign fibro-osseous lesions of the craniofacial complex are represented by a variety of disease processes that are characterized by pathologic ossifications and calcifications in association with a hyper cellular fibroblastic marrow element. The current classification includes neoplasms, developmental dysplastic lesions and inflammatory/reactive processes. The definitive diagnosis can rarely be rendered on the basis of histopathologic features alone; rather, procurement of a final diagnosis is usually dependent upon assessment of microscopic, clinical and imaging features together. We present one such case of fib osseous lesion which was diagnosed as fibrous dysplasia upon histopathological examination.

Keywords: Maxillary sinus, Fibrous dysplasia.

INTRODUCTION

The Fibrous dysplasia is a type of fibro-osseous lesion in which normal bone is replaced by disorganised fibrous tissue. It represents 2% of the osseous tumors [1] Lichtenstein was the one who in 1938 introduced the term fibrous osseous dysplasia [2]. The etiology of fibrous dysplasia remains unknown, however, they may be neoplastic and/or metabolic imbalances in nature. The aim of this article is to present a rare case of Fibrous dysplasia involving the maxillary sinus [3].

CASE REPORT

A 13 year old male patient reported in the Department of Dentistry, Indira Gandhi Institute of Medical Sciences, Patna with the chief complaint of swelling involving middle one- third region of face on left side. (Fig.1 & 2) The patient gave history that the swelling was initially small in size which gradually increased to attain its present size. The swelling was not associated with any signs and symptoms. There was no complaint of pain, swelling, discharge or any other associated symptoms. On examination, the swelling extended anteroposteriorly from ala of nose till angle of mandible and superoinferiorly from 2 cm below the lower eyelid till level of corner of lip. The superficial skin appeared smooth. On palpation, all inspectory findings were confirmed. The swelling was hard on palpation and the margins were ill defined. The superficial skin was pinchable. There were no

secondary changes observed. Intraoral examination did not reveal any significant findings. (Fig 3 and 4). On radiographic examination, OPG revealed radiopacity which was seen involving the entire maxillary sinus of the left side (Fig 5). The odontogenic cause were ruled out. For further evaluation, a blood investigation and CT-scan were advised. Blood investigation revealed increased levels of alkaline phosphatase (normal <258U/L, finding- 1093 U/L) and CT-scan reports revealed diffuse expansion with ground glass like opacity involving left maxillary sinus, side of nasal cavity on left side, left turbinates, body and wings of sphenoidal bone, left temporal bone involving petrous bone and mastoid bone and temporal part of skull bone.(Fig 6 and 7). Provisional diagnosis of fibrous dysplasia was given and further biopsy was advised for histopathological confirmation. The patient underwent surgical treatment at the Department of ENT, Indira

Gandhi Institute of Medical Sciences, Patna and the excised sample was sent for histopathological evaluation. Histopathological examination was conducted at pathology centre, Patna. (Fig. 8) The

histopathological report of the sample confirmed the diagnosis of fibrous dysplasia. Patient report after 1 month for follow up and showed marked aesthetic improvement.



Fig-1 & 2: Patient with extraoral swelling involving predominantly left side of the face

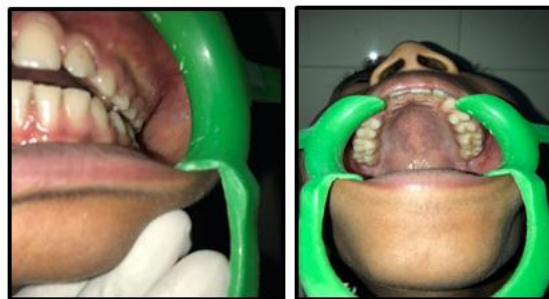

Fig-3 and 4: Intraoral examination findings

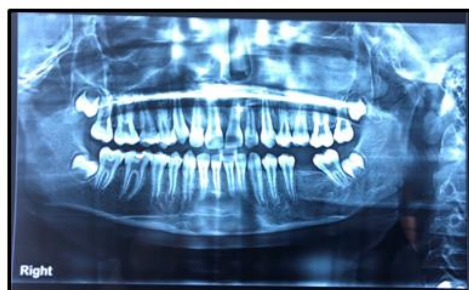

Fig-5: OPG Pan: Shows radiopacity involving entire maxillary sinus of the left side

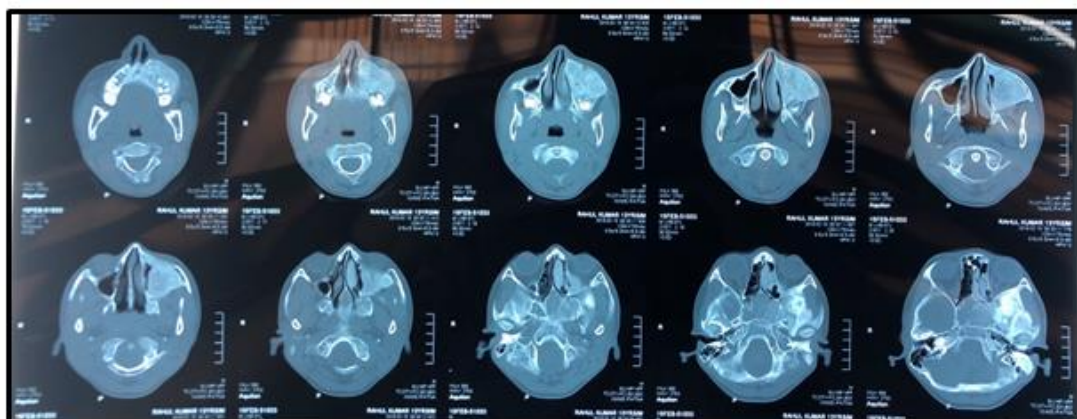


Fig-6: CT scan in axial section shows “Ground Glass Appearance” involving the left maxillary sinus

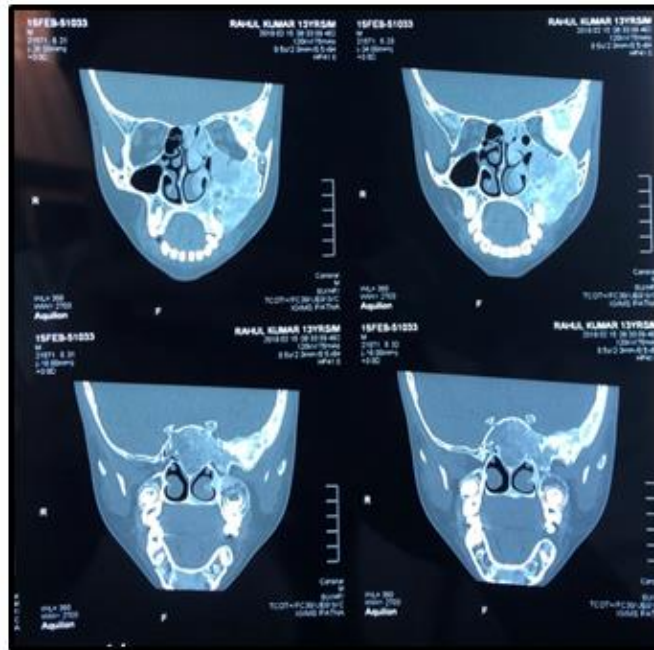


Fig-7: CT scan in coronal section shows “Ground Glass Appearance” involving the left maxillary sinus

| NAME | : MASTER RAHUL KUMAR | RECEIVED DATE | : 10/05/2018 |
|------------------------------|---|---------------|------------------|
| AGE | : 13 Year/s | REPORTED DATE | : 16/05/2018 |
| SEX | : MALE | PATIENT ID | : KPD10052018022 |
| REF BY | : DR IGIMS | SLIDE NO | : KM - 604 |
| TEST NAME | VALUE | UNITS | NORMAL RANGE |
| HISTOPATHOLOGY REPORT | | | |
| SPECIMEN : | TISSUE FROM LEFT MAXILLA | | |
| GROSS FINDING : | RECEIVED MULTIPLE BONY TISSUE MEASURING TOGETHER 5X4X1.5 CMS. MULTIPLE BITS: 3 BLOCKS | | |
| MICROSCOPIC FINDING : | THE SECTION SHOWS MANY CURVED BONY TRABECULAE INTERPERSED WITH FIBROUS TISSUE. NO GRANULOMA SEEN. NO MALIGNANCY SEEN. | | |
| IMPRESSION : | FEATURES SUGGESTIVE OF FIBROUS DYSPLASIA. | | |
| COMMENT : | KINDLY CORRELATE WITH RADIOLOGICAL FINDINGS. | | |
| --End of Report-- | | | |

Fig-8: Histopathologic report confirming diagnosis of fibrous dysplasia

DISCUSSION

The Fibrous dysplasia (FD) is defined as a benign osseous disease characterized by a process of normal bone reabsorption, followed by an abnormal proliferation of a disorganized fibroosseous tissue [1]. It represents about 7% of all benign osseous tumors and may affect any bone of the skeleton [4]. Fibrous dysplasia is classified on the basis of number of bones involved and the presence or not of extraskelton abnormalities. The first subtype is the monostotic type where a single bone is involved and affects 70 - 80 % of the patients. The other subtype is polyostotic type in which several bones are involved. The polyostotic form, in which several bones are affected, may be divided into three subtypes: craniofacial, in which only the

craniofacial complex are involved including the jaw and the maxilla; Lichtenstein Jaffe, in which in addition to the several skeleton bones involvement there are coffee with milk pigmentations; Albright's syndrome, characterized by the affection of several bones, coffee with milk pigmentations in the skin and endocrine affection with a remark for the early adolescence in girls. The polyostotic form corresponds to 20-30% of the cases [5].

It manifests more frequently in the childhood and, however, is not exclusive of this age range [6,7]. It has an usually slow evolution, a tendency to stabilize after adolescence and a high recurrence rate [2, 7, 8]. Such characteristics have a strong implication in the

therapeutic approach. As for the distribution of the disease by sex, there is no uniformity between the studies [9, 7, 8]. The disease is initially asymptomatic. The Fibrous dysplasia (FD) signals and symptoms depend on the location of the lesion(s) and the compressive effect in the adjacent structure as the tumor progresses slowly: facial asymmetry and deformity; pathological fractures; obstruction of the paranasal sinuses which generate recurrence infections, cysts and mucocoeles; anosmia; headache; loss of visual accuracy for compression of the optic nerve; alteration of the ocular movements; descent; exophthalmia, squint; conductive hearing loss [6, 7, 10, 11]. Similar findings were seen in our case where the patient was initially asymptomatic and the swelling gradually increased causing facial asymmetry and deformity. The main factors that guide the Fibrous dysplasia approach are the presence and the intensity of the symptoms, the tumor location and the patient's age. The simple presence of the lesion does not justify surgical intervention. The main indications for surgical treatment of Fibrous dysplasia are the presence of significant clinical symptoms and the control of large aesthetic deformities [2, 7]. In our case, the swelling had caused facial deformity and there was increasing that the swelling might cause pathological fracture, obstruct paranasal sinus, compress optic nerve causing loss of vision. Therefore, the swelling had to be surgically excised. Because of the lesions benign nature and its recurrence character (10-20%), the surgery must be relatively conservative with the main objective of preserving the function [7].

CONCLUSION

The Fibrous dysplasia may be genetic and/or due to metabolic imbalance, it may affect facial and cranial bones and may cause deformities and dysfunctions. In this case, surgical treatment was done taking into account the disease's harmful nature and recurrent potential, by choosing a more conservative approach and removing as much tissue as possible to prevent mutilations and functional deficits[12].

REFERENCES

1. Antunes AA, Filho JR, Antunes AP. Displasia Fibrosa Óssea: Estudo retrospectivo-revisão de literatura. Rev Bras Cirur Cab Pesc. 2004, 33(1):2126.
2. Cruz OL, Pessoto J, Pezato R, Alvarenga EL. Osteodistrofias do osso temporal: Revisão dos conceitos atuais, manifestações clínicas e opções terapêuticas. Rev Bras Otorrinol. 2002, 68(1):11926.
3. Bahl R, Sandhu S, Gupta M. Benign Fibro-Osseous Lesions Of Jaws- A Review. International Dental Journal Of Student'S Research| June-Sep 2012| Volume 1| Issue 2
4. Moreno BA, Sánchez AL, Collado JA, Garcia AU, Cortês JM, Varela HV. Displasia fibrosa

- monostótica de seno esfenoidal. O.R.L. Aragon. 2007, 10(1):1215.
5. Pontual ML, Tuji FM, Yoo HJ, Bóscolo FN, Almeida SM. Estudo epidemiológico da displasia fibrosa dos maxilares numa amostra da população brasileira. Odontol Clin.Científ. 2004, 3(1):2530.
6. Altuna X, Gorostiaga F, Algaba J. Displasia fibrosa monostótica de seno frontal. A propósito de um caso. ORLDIPS. 2004, 31(2):8487.
7. Alves AL, Canavarros F, Vilela DS, Granato L, Próspero JD. Displasia fibrosa: relato de três casos. Rev Bras Otorrinol. 2002, 68(2):288292.
8. Lustig LR, Holliday MJ, McCarthy EF, Nager GT. Fibrous Dysplasia involving the skull base and temporal bone. Arch Otolaryngol Head Neck Surg. 2001, 127:12391247.
9. Moreno BA, Sánchez AL, Collado JA, Garcia AU, Cortês JM, Varela HV. Displasia fibrosa monostótica de seno esfenoidal. O.R.L. Aragon. 2007, 10(1):1215
10. Fuster MA, Martín JÁ, RodríguezPereira C, Navarro JM, Molina JV. Displasia fibrosa monostótica de seno frontal com extensión orbitária. Acta Otorrinolaringol Esp. 2002, 53:203206.
11. Oliveira RB, Granato L, Korn GP, Marcon MA, Cunha AP. Displasia Fibrosa do osso temporal: relato de dois casos. Rev Bras Otorrinol. 2004, 70(5):695700.
12. Tinoco P. Fibrous Dysplasia of Maxillary Sinus. International Archives of Otorhinolaryngology. 2009;13; 2, Apr/June.