

Primary Non-Hodgkin Lymphoma Presenting as a Forehead Mass: A Rare Presentation

Sant Prakash Kataria, Roomi Yadav*, Sanjay Kumar, Nitin Yadav, Archana, Rajeev Sen

Post Graduate Institute of Medical Sciences, Rohtak, Haryana, India

*Corresponding author

Roomi Yadav

Article History

Received: 13.10.2018

Accepted: 23.10.2018

Published: 30.10.2018

DOI:

10.36347/sjmcr.2018.v06i10.023



Abstract: Extranodal Non Hodgkin Lymphoma of head and neck are quite uncommon. They usually involve Waldeyer's ring, nasal cavity and paranasal sinuses. It is very rare for these lesions to present as a soft tissue mass. A forehead swelling in a 63 year old male which proved to be diffuse large B cell lymphoma on biopsy is being reported.

Keywords: Non-Hodgkin's lymphoma, extranodal, forehead swelling.

INTRODUCTION

Lymphoma can be classified into two types- Hodgkin's lymphoma and Non-Hodgkin's lymphoma (NHL), with various subtypes under each category. Lymphoproliferative malignancies can disseminate to organs and tissues that do not ordinarily contain lymphoid cells (extranodal sites). Extranodal Hodgkin's lymphoma is rare, while about 20% of NHL are extranodal [1]. Extranodal NHL of the head and neck is a relatively uncommon disease. In head and neck region, Waldeyer's ring is the most common site of extranodal NHL [2]. We are reporting a case of diffuse large B cell lymphoma (DLBCL) presenting as a soft tissue mass in the region of forehead.

CASE REPORT

A 63 -year-old Indian male presented to surgery outpatient department with a slowly growing swelling on the right side of forehead since 1 month.

There was associated history of blurring of vision and diplopia. There was no history of trauma or loss of weight. On examination, the swelling measured approximately 7x2 cm with smooth contours and was freely mobile, non-tender and non-pulsatile. It was extending up to medial canthus of right eye. There was no associated cervical or peripheral lymphadenopathy. Systemic examination was essentially unremarkable. Ophthalmological examination showed paralysis of medial rectus muscle. Anterior and posterior segments of eye were normal.

Ultrasonography of the swelling at right side of forehead showed a well-defined hypoechoic lesion of size 7x1.5 cm superficial to the bone. There was no significant flow on color doppler. B Scan of right eye showed normal anterior and posterior segments of eye with normal optic disc. X- Ray skull revealed a radiopaque lesion in soft tissue of right frontal region without involvement of underlying bones. Computed tomography (CT) head showed a hyperdense soft tissue attenuation lesion in the subcutaneous plane of right frontal region with extension into right orbit. Underlying bones were normal. Brain parenchyma was also normal. Patient was advised contrast enhanced magnetic resonance imaging (MRI) for further

characterisation of the lesion and determining its intraorbital/intracranial extent. MRI revealed a T1 and T2 hypointense lesion in the region of right forehead (Figure 1). The lesion showed diffusion restriction and showed subtle enhancement on post contrast images (Figure 2). The lesion was noted to extend into medial part of right orbit with involvement of extraocular muscle (medial rectus). Optic nerve was normal. No intracranial extension of lesion was noted. There was no evidence of fatty component or calcification within the lesion. Differential diagnosis considered on imaging included rhabdomyosarcoma, lymphoma and metastatic deposits. Positron Emission Tomography (PET) scan (done after biopsy) revealed hypermetabolic extraconal soft tissue mass superior to right zygoma, extending along medial wall of right orbit. There was no evidence of any other hypermetabolic lesion in chest or abdomen, ruling out the possibility of metastases.

FNAC performed at a primary care centre showed atypical large round to oval hyper chromatic cells, lying predominantly singly, with scant basophilic cytoplasm with convoluted and indented nuclei against a background of mature lymphocytes. An occasional atypical mitosis was also seen. A differential diagnosis of Non-Hodgkin Lymphoma and metastatic

undifferentiated carcinoma was considered and further histopathological evaluation was advised.

Excision biopsy done at our institute showed organoid pattern of large round to oval cells with indistinct cell boundary, abundant wispy, feathery, granular cytoplasm. The nuclei showed moderate anisokaryosis and vesicular chromatin with prominent nucleoli (Figure 3). Tumor cells were transversed by large ramifying vascular structures with inflammatory infiltrate. Immunohistochemical staining revealed

positivity for LCA and CD20 (Figure 4), whereas CD3, CD5, Cytokeratin, CD10, SMA, Vimentin, Synaptophysin and CD68 were negative (Figure 4), confirming the diagnosis of Non Hodgkin Lymphoma, diffuse large B cell type.

The patient received postoperative chemotherapy and complete remission has been achieved for 2 years since the excision of the mass.

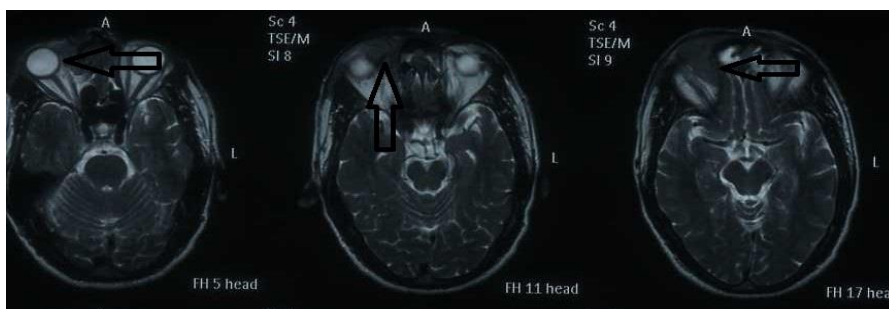


Fig-1: Axial T2 weighted MRI image showing hypointense lesion at right side of forehead reaching upto medial canthus of right eye (arrows)

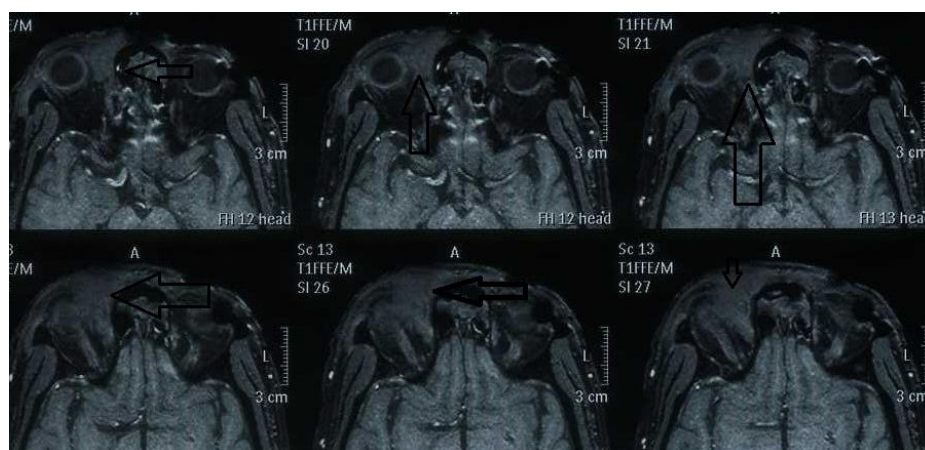


Fig-2: Axial T1 weighted post contrast MRI image showing mildly enhancing hypointense lesion in right forehead region reaching upto medial canthus of right eye (arrows)

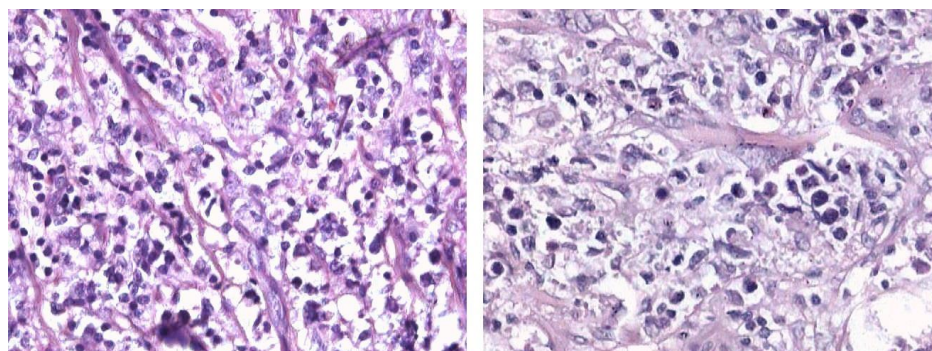


Fig-3: Nuclei showing anisonucleosis and vesicular chromatin with prominent nucleoli at 200X (left panel) and 400X (right panel)

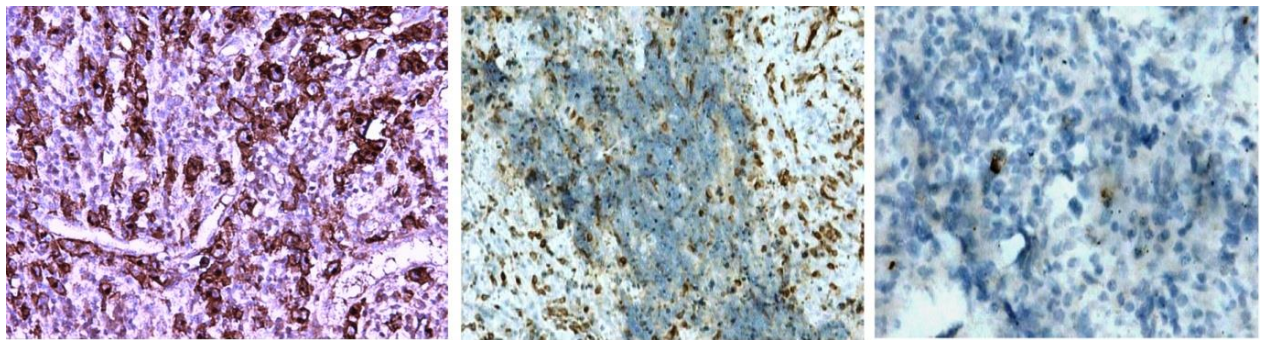


Fig-4: showing positive membranous staining for CD20 (left panel), CD3 positivity in normal T lymphocytes (mid panel) and negative staining for cytokeratin (right panel)

DISCUSSION

NHLs of head and neck have a wide spectrum of presentation. Approximately 20% of all NHLs of the head and neck region are primary extra nodal. Most of the extra nodal NHLs of the head and neck arise in the Waldeyer's ring followed by salivary glands and the oral cavity, which can be explained due to high content of lymphatic tissue at these sites [2].

Lymphoma presenting as a forehead mass is quite rare. In the present case, clinical diagnosis of soft tissue lesions like lipoma was considered. However, lymphoma was not among the clinical differential diagnosis. FNAC had suggested a diagnosis of lymphoma or metastatic undifferentiated carcinoma. Extensive search of literature revealed only few case reports of lymphoma presenting as a forehead soft tissue mass [3].

Extranodal lymphoma in the head and neck region typically occurs in elderly patients in 50 to 60 years age group. A large study performed by Chi *et al.* demonstrated tonsil (31.4%), sinus and nasal cavity (16.3%), tongue base (11.6%), thyroid (10.5%) and orbit (10.5%) as the common sites of extranodal head and neck lymphoma[1]. Another study done by Picard *et al.* reported palatine tonsil (28%) and nasal fossa and sinus (19%) as being the most common site of extranodal lymphoma of head and neck[4]. The common extranodal NHL pathological types in the head and neck are B-cell lymphoblastic, small lymphocytic, follicular, mantle cell, diffuse large B-cell, Burkitt's, and extranodal NK/T-cell nasal type. Diffuse large B-cell lymphoma is the most common type of NHL in the head and neck, with Waldeyer's ring and paranasal sinuses being common sites. Marginal zone lymphoma (MALT type) has a predilection for ocular adnexae, salivary glands, larynx, and the thyroid gland. Nasal cavity is the common site of NK/T-cell lymphoma. Burkitt's lymphoma commonly involves maxilla and facial bones [5].

Diffuse large B cell lymphoma is mostly seen in elderly age group with a median age of 64 with male predominance. DLBCL typically presents as a rapidly enlarging mass as a nodal or extra nodal site, but

involvement of forehead is very rare. Histologically, DLBCLs consist of intermediate to large-sized cells that may be noncleaved, cleaved, or immunoblastic. Immunophenotypic studies demonstrate B-cell lineage with expression of pan-B-cell markers (CD19, CD20, CD22, CD79A, PAX5) and absence of T-cell markers [6].

Imaging features of lymphoma on MRI are characteristic and often provide important clue to diagnosis. Lymphoma appears characteristically hypointense on T1 and T2 weighted images, show restricted diffusion and subtle homogenous post contrast enhancement [7]. The lesion in the present case had these features. However, it was kept lower down in the list of differentials on imaging because of rare site of presentation and no associated lymphadenopathy. USG and CT have lower specificity for diagnosis of lymphoma compared to MRI.

Primary Diffuse B cell Lymphoma arises as denovo lesions and have an excellent prognosis, if proper treatment is instituted. DLBCLs are very aggressive tumors that are rapidly fatal without treatment. With intensive combination chemotherapy (CHOP based regimen), 60% to 80% of patients achieve a complete remission [8], which was also observed in our case.

CONCLUSION

Extranodal NHL presenting as a forehead mass is very rare. It should be considered in the differential diagnosis of soft tissue swelling of forehead. Prompt diagnosis is essential for proper management of these lesions since they show good response to chemotherapy.

REFERENCES

1. Chi HS, Lee KW, Chiang FY, Tai CF, Wang LF, Yang SF, Lin SF, Kuo WR. Head and neck extranodal lymphoma in a single institute: a 17-year retrospective analysis. The Kaohsiung journal of medical sciences. 2012 Aug 1;28(8):435-41.
2. Laskar S, Mohindra P, Gupta S, Shet T, Muckaden MA. Non-Hodgkin lymphoma of the Waldeyer's

- ring: clinicopathologic and therapeutic issues. *Leukemia & lymphoma*. 2008;49(12):2263-71.
3. Omoti AE, Omoti CE, Ogbeide OU. Non-Hodgkin's Lymphoma Presenting as a Huge Ocular Adnexal and Forehead Mass. *J Ophthalmic Vis Res*. 2011;6(1):47-50.
 4. Picard A, Cardinne C, Denoux Y, Wagner I, Chabolle F, Bach CA. Extranodal lymphoma of the head and neck: a 67-case series. *Eur Ann Otorhinolaryngol Head Neck Dis*. 2015;132(2):71-5.
 5. Weber AL, Rahemtullah A, Ferry JA. Hodgkin and non-Hodgkin lymphoma of the head and neck. *Neuroimaging Clinics*. 2003;13(3):371-92.
 6. Vega F, Lin P, Medeiros LJ. Extranodal lymphomas of the head and neck. *Ann Diagn Pathol*. 2005;9(6):340-50.
 7. Aiken AH, Glastonbury C. Imaging Hodgkin and non-Hodgkin lymphoma in the head and neck. *Radiologic Clinics of North America*. 2008;46(2):363-78.
 8. Essadi I, Ismaili N, Tazi E, Elmajjaoui S, Saidi A, Ichou M, Errihani H. Primary lymphoma of the head and neck: two case reports and review of the literature. *Cases journal*. 2008 Dec;1(1):426.