

Inter-Tibiofibular Graft: Case Report

Mohammed Kadiri*, Mouad Beqqali-Hassani, Moncef Boufettal, Mohamed Kharmaz, Moulay Omar Lamrani, Ahmed El Bardouni, Mustapha Mahfoud, Mohamed Saleh Berrada

Faculty of medicine of Rabat, Avenue Mohamed Belarbi El Alaoui B.P.6203 10000, Rabat, Morocco

***Corresponding author**

Mohammed Kadiri

Article History

Received: 22.10.2018

Accepted: 05.11.2018

Published:30.11.2018

DOI:

10.36347/sjmcr.2018.v06i11.002



Abstract: We report in this work our experience of an inter-tibio-fibular graft (ITFG) performed to treat a tight aseptic pseudarthrosis of the lower quarter of the right leg in a 57-year-old patient with chronic smoking. This technique was beneficial to us and allowed us to have a satisfactory consolidation and a good result after a follow-up of 2 years.

Keywords: Pseudarthrosis of the leg, ITFG, Consolidation.

INTRODUCTION

Fractures of the lower quarter of the leg are often complicated by septic or aseptic pseudarthrosis, and chronic smoking is a contributing factor. The treatment is surgical, whose stake is to achieve a consolidation of the fracture without axis defect or length defect. GTP is an ideal treatment, but it can only be performed if the vascular state of the affected leg allows is good, involving a mastery of the technique and these complications.

CASE REPORT

This is a 57-year-old patient with chronic smoking operated for fracture of fracture to the lower quarter of the leg with fracture of the head of the fibula by intramedullary nailing with double locking proximal and distal dynamic type with closed focus, but whose evolution had shown a delay in consolidation at 6 months of follow-up and then a lack of consolidation of the fracture site at 10 months of evolution with clinically persistent pain and mobility of the fracture site.

The paraclinical assessment included a standard radiograph that showed a consolidation delay on the face and profile (Figure 1), a CT scan that confirms the absence of callus and Bone Bridge, and a biological assessment excluding any sepsis.

Therefore, the diagnosis of tight aseptic pseudarthrosis was retained. Therefore a CT scan was performed for evaluation of the vascular state of the affected limb, and lastly, there is no problem of permeability of the main arteries.

Surgical treatment with ITFG technique has been advocated.

The instalation:(Figure 3)

- Ventrale decubitus
- Pneumatic tourniquet at the root of the thigh
- Facing the fracture site and preparing the posterior superior iliac crest

Avotivation of the pseudarthrosis focus

- First postero-external way of the leg passing through the muscular interstice between the long hallux prominent forwards and the soleus muscle behind (Figure 4)
- Decorporation of the tibial and fibular cortical over a length of 8 cm (Figure 5)
- Autograph graft taken from postero-superior iliac crest, an 8 cm fragment was taken (Figure 6)

Implementation of the graft

- Use of a Mehari davierr in the interosseous space for well exposure (Figure 7)
- Interposition of the graft in space (Figure 8)
- Fixing with two pins (Figure 9)

Consolidation of the graft was obtained at 4 month. The final control X-ray shows the bone bridge (Figure 10)

The decline at 2 years shows a patient satisfied with the treatment with a mobile and functional indolent leg.

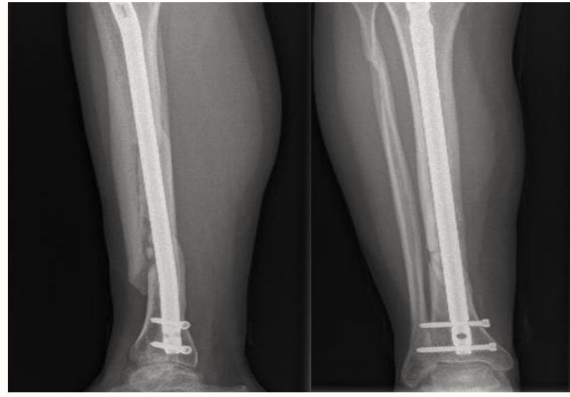


Fig-1: X-Ray shows Pseudarthrosis of the leg

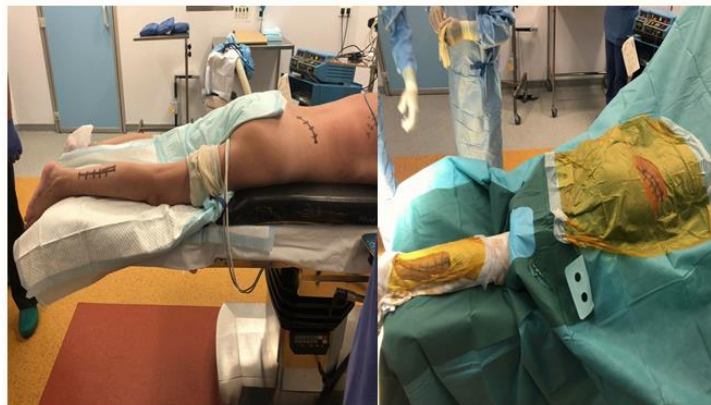

Fig-2: The installation

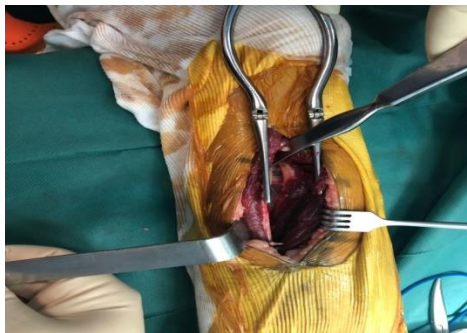

Fig-4: Surgical approach

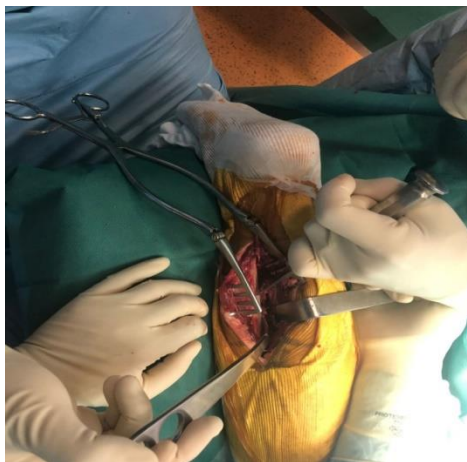


Fig-5: Decorporation of the tibial and peroneal cortical over a length of 8 cm

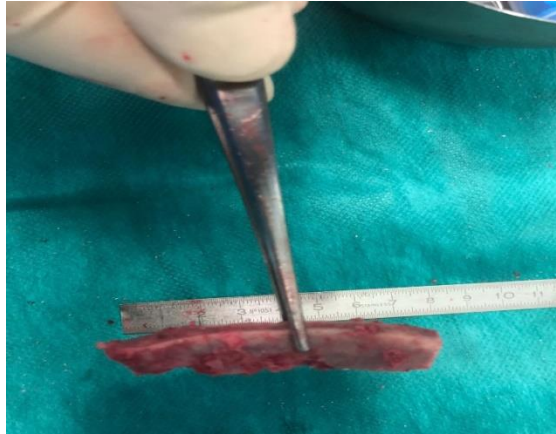


Fig-6: Autograph graft taken from posterior superior iliac crest

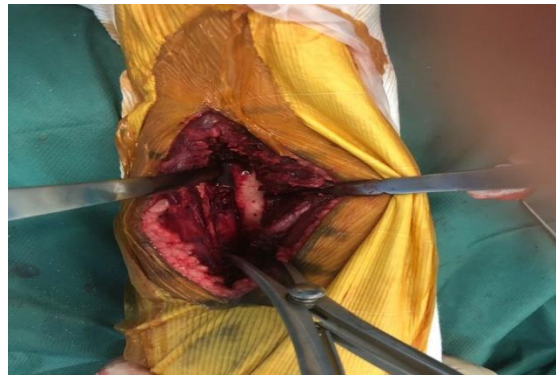

Fig-7: Meharidavier in the space

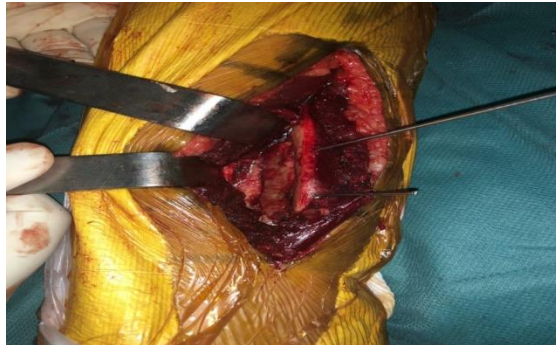

Fig-8: Interposition of the graft in space

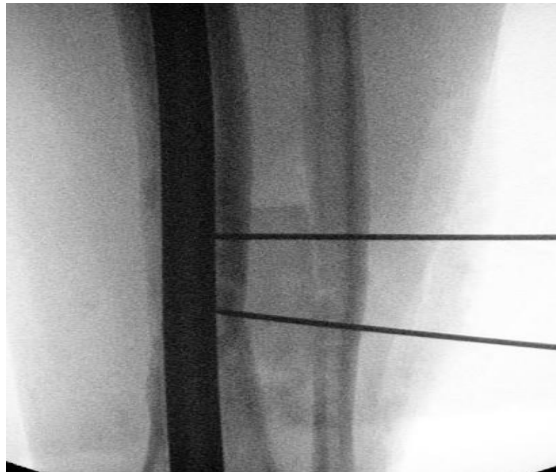

Fig-9: Fixing with two pins

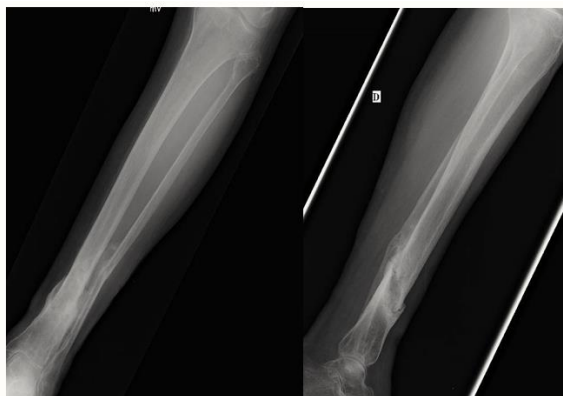

Fig-10: X-Ray after 8 months

DISCUSSION

ITFG has been used since the 1960s for the treatment of pseudarthrosis of the leg, septic and aseptic, as well as its loss of substance. It consists of creating a tibio-fibular synostosis on both sides of the fracture site allowing bone continuity of the leg playing the role of bypass of pseudarthrosis [1].

The challenge with this technique is to obtain a stable, indolent and functional leg without axis or length defects. It consists of interposing the allograft or, more often, the autograft, taking antero-inferior or postero-superior iliac crest, in the interosseous space between two sharpened portions of the tibia and fibula over a distance stretching 3 to 4 cm above and below the pseudoarthrosis focal point [2].

The interposed graft can be held in place simply by the biomechanical pressure exerted by the tibia and fibula or, if the fragment does not repal the interosseous space, provisional osteosynthesis by pins taking the fibula, the graft and the tibia can be achieved until at least obtaining a fibrous callus [3].

As for the stabilization of the focal point of pseudarthrosis or the loss of substance it will be imperatively assured by an internal osteosynthesis of the type of nailing or else by external fixator in the event of sepsis associated [4].

The GTP almost constantly leads to the consolidation of the nonunion center: 98% for EVRARD more than 90% for VIDAL and COLL [5]. However, VIDAL reports a fairly high number of failures (13 out of 47 GTP cases) related to, according to him, technical errors due to the variety of operators. Moreover, failures of ITFG can be successfully resumed by iterative ITFG [6]. In severe bone loss, an anterior diaphyseal graft [7] is of great interest. The use of the opposite fibula [5] has been proposed in some cases.

CONCLUSION

Our study confirms the interest of GTP as an intervention of choice in the treatment of pseudarthrosis of the leg, because of the constancy of its success on the consolidation and to a lesser degree on the infection. It remains in the surgical arsenal of the surgeon, the least expensive intervention. It can significantly shorten the duration of hospitalization and disability, if it is performed early, before the often complete scarring of skin lesions.

CONSENT

The patient has given their informed consent for the case to be published.

COMPETING INTERESTS

The authors declare no competing interest.

AUTHORS' CONTRIBUTIONS

All authors have read and agreed to the final version of this manuscript and have equally contributed to its content and to the management of the manuscript.

REFERENCES

1. BUMBIC S. Pseudarthrose ostéomyélique du tibia avec perte de substance, traitée par greffon du péroné opposé. Clin. Pédiatr. 1986, 27, 356-358.
2. Chauvet J, SAVORNIN C, TRIPON P, WILLEMS P, CASANOVA G, Gandon F. Pseudarthroses septiques diaphysaires: orientations thérapeutiques actuelles à partir d'une série de quatre-vingts cas. In Annales de chirurgie 1986 (Vol. 40, No. 9, pp. 633-640). Elsevier.
3. Cattaneo R, Villa A, Catagni M, Tentori L. Traitement des pseudarthroses diaphysaires septiques ou non septiques selon la méthode d'Ilizarov en compression monofocale. Revue de chirurgie orthopédique et réparatrice de l'appareil moteur. 1985;71(4):223-9.
4. Evrard J. Bilan de la greffe intertibia-péronière. Ann. Orthop. Ouest, 1978, 10, 104-106.
5. Fischer LP, Carret JP, Gonon G, Mourgues G. Greffe Intertibia-péronière dans le Traitement des

Pseudarthroses Fistuleuses Diaphysaires de Jambe.
International Orthopaedics. 1977 Mar 1;1(1):58-63.

6. Jones KG, Barnett HC. Cancellous-bone grafting for non-union of the tibia through the posterolateral approach. JBJS. 1955 Dec 1;37(6):1250-60.

7. Vidal J, Buscayret CH, Finzi M. ET Melka J. La greffe intertibio-péronière dans le traitement des retards de consolidation jambiers. A propos de 47 cas. Rev. Chir. Orthop. 1982, 68, 123-132.