

Solar Retinopathy-A Case Series

Dr. Nilesh Mohan¹, Dr. Bandana Kumari^{2*}, Dr. Randhir Kumar³, Dr. Subhash Prasad⁴, Dr. Satya Prakash Tiwary⁵

¹Additional Professor, Indira Gandhi Institute of Medical sciences, Patna, India

²Senior Resident, Indira Gandhi Institute of Medical sciences, Patna, India

³⁻⁵Director, Divyadrishti Eye Centre, Patna, India

*Corresponding author: Dr. Bandana Kumari

| Received: 01.02.2019 | Accepted: 08.02.2019 | Published: 18.02.2019

DOI: 10.36347/sjmcr.2019.v07i02.002

Abstract

Case Report

Purpose: To report a case series of solar retinopathy in a tertiary eye care center of India. We report 11 cases of different causes of solar retinopathy. **Methods:** This is an observational study. Patients reporting to a tertiary eye care center with central scotoma and defective vision. **Results:** Cases with different types of phototoxicity to retina were diagnosed as having solar retinopathy on the basis of clinical examination and optical coherence tomography (OCT) scanning. **Conclusions:** Phototoxicity not as uncommon as it is thought. Proper history, clinical examination and diagnostic testing helps in clinching the diagnosis.

Keywords: Solar retinopathy, photic retinopathy, sungazing, phototoxicity to retina.

Copyright @ 2019: This is an open-access article distributed under the terms of the Creative Commons Attribution license which permits unrestricted use, distribution, and reproduction in any medium for non-commercial use (NonCommercial, or CC-BY-NC) provided the original author and source are credited.

INTRODUCTION

Solar retinopathy is a type of retinal injury which is rarely seen. It occurs mostly after viewing solar eclipse, prolonged sun gazing, exposure of laser light, or exposure of light reflected from the surface of

snow. Most common form of solar injury is either solar eclipse or habitual or religious sun gazing

METHODS

In our series, we are reporting 11 cases of photic retinopathy of different etiology.

Causes	No of patients
Solar eclipse	5
Sun gazing	1
Welding light	2
Laser light	1
Snow reflection	2

One patient presented after habitual sun gazing [1] and retinopathy was seen in both eyes. Two patients had significant history of welding light exposure without protection (Fig. 1).

RESULTS

In our series, most common cause was watching a solar eclipse (Image 2) with unprotected eye [2]. In all patients, only one eye was affected. They all gave a peculiar history of watching eclipse by one eye and other eye was closed as they knew about the harmful effect of eclipse on the eye. Mostly it was found in young age group male patient (4 out of 5) as they took it as challenge in peer group while one patient was female of 55 years age.

One patient had injury by laser light of toy. Two patients were soldiers posted for longer duration in hilly area and significant exposure of sunlight reflected from the surface of snow (Image 3).

All patients complained of defective central vision and metamorphosis with fairly good visual acuity, ranging from 6/9 to 6/6.

Clinically the fundus appeared normal with central small red defect at fovea. But diagnosis were confirmed by optical coherence tomography (OCT). OCT characteristically showed a central defect in IS/OS junction of outer retina [3]. Retinal pigment epithelium defect was also present in few cases [4]. There was actually an outer lamellar macular hole.

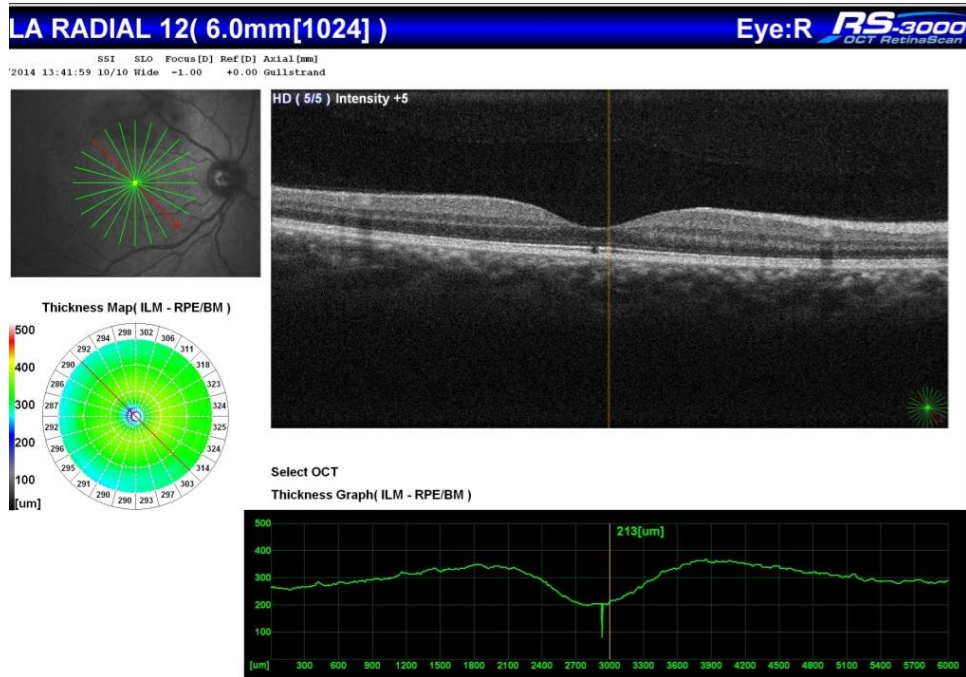


Fig-1: OCT showing loss of IS/OS junction

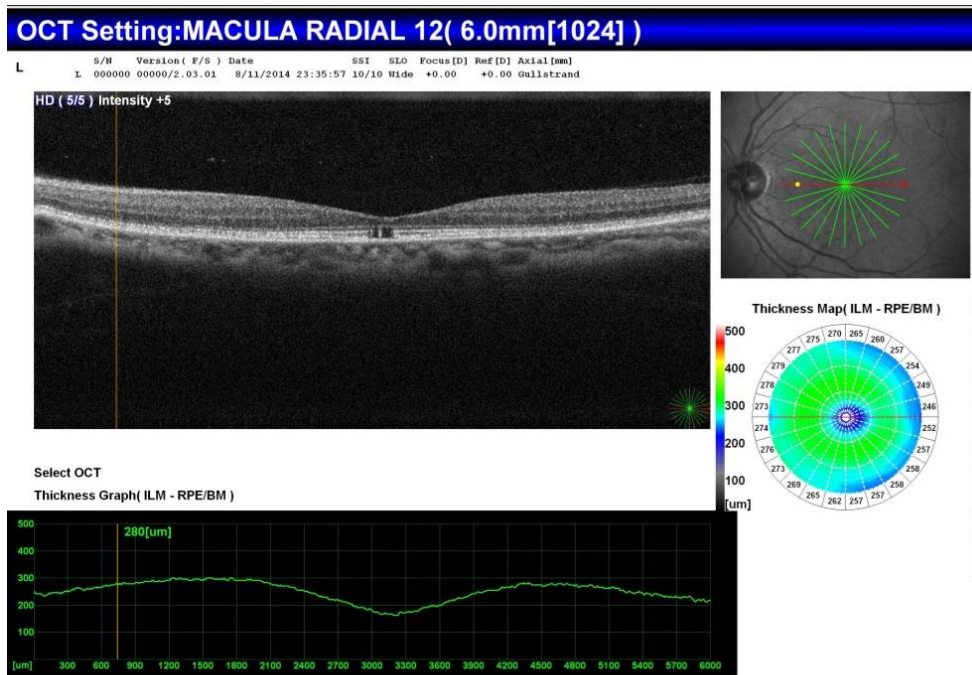


Fig-2: OCT showing loss of IS/OS junction

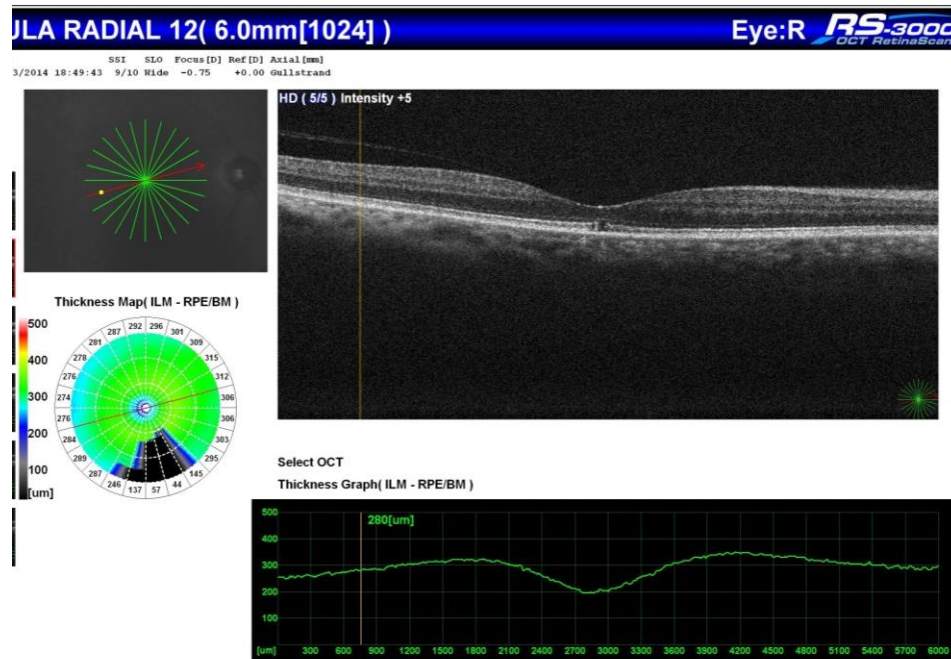


Fig-3: OCT showing loss of IS/OS junction

DISCUSSION

Solar retinopathy is an uncommon form of retinal injury which is generally reported after eclipse viewing. Other types of prolonged light exposure may also cause retinal toxicity with similar findings. Ultraviolet (UV-B) component of sunlight is supposed to be toxic to retina. Mechanisms of injury include photochemical toxicity generated by UV-B light and thermal injury from near-infrared radiation. Thermal, photochemical, and photomechanical reactions taking place in fovea after UV-B exposure leading to solar retinopathy [5, 6].

In cases of acute injury, there is blurring of central vision and on examination yellowish spot is seen in the fovea which gradually fades over time. OCT in acute injury will show a small hyper-reflective shadow in all retinal layers which signifies acute toxicity to photoreceptors. In chronic stage, OCT shows characteristic finding with disruption of photoreceptor layer (IS/OS) junction (D7) with defective RPE layer (Figure 1, 2, 3). There is outer lamellar macular hole of very small size centered over fovea.

Other investigations like fluorescein angiography, autofluorescence, OCT angiography and electrophysiology has also been described but the diagnosis mainly depends on OCT scanning.

Most common cause described widely in literature is solar eclipse viewing. In our series also we got similar history in 5 cases. In all 5 cases of solar eclipse injury only one eye was involved as the patient watched eclipse with other eye closed. All patients

knew about the risk of damage to eye by solar eclipse and so they closed other eye.

Other common cause is habitual sun gazing due to religious practice or psychiatric illness. Arc welding light exposure without protection glass also causes phototoxicity to retina. During military exercises or prolonged posting of soldiers can have injury by reflected sunlight from the surface of snow, we saw 2 such cases in our series.

Recently pointed laser light source has become very common in pointers and toys. Laser light emitted from toys can damage retina if seen directly and we had 1 patient with phototoxicity from laser light.

In our series, we found many types toxic light exposure causing solar retinopathy. Once injury occurs and if patient presents early in acute phase, systemic steroid can be given to prevent loss of photoreceptors [7]. In late phase there is defect in subfoveal photoreceptors which cannot be repaired. So making people aware about the possible toxic light and methods to prevent exposure is necessary to avoid photo injury to retina. Safe methods of eclipse viewing, preventive glasses during arc welding work, providing protective glasses to soldiers in hilly areas and safe use of laser pointers and toys will be helpful in preventing solar retinopathy.

CONCLUSIONS

Solar retinopathy is not as uncommon as it is thought. UV-B light exposure can damage the photoreceptors and lead to defective vision. There can be many mechanism of phototoxicity to retina which

includes, solar eclipse viewing, arc welding light exposure, laser light exposure, sun gazing etc. Making people aware about possible and methods to prevent can help in avoiding photo damage to retina.

REFERENCES

1. Moran S, O'Donoghue E. Solar retinopathy secondary to sungazing. *BMJ case reports*. 2013 Jan 25; 2013: bcr2012008402.
2. Michaelides M, Rajendram R, Marshall J, Keightley S. Ecliptic retinopathy. *Eye*. 2001; 15(Pt 2):148–151.
3. Jorge R, Costa RA, Quirino LS, Paques MW, Calucci D, Cardillo JA, Scott IU. Optical coherence tomography findings in patients with late solar retinopathy. *American journal of ophthalmology*. 2004 Jun 1; 137(6):1139–42.
4. Hope-Ross MW, Mahon GJ, Gardiner TA, Archer DB. Ultrastructural findings in solar retinopathy. *Eye*. 1993 Jan; 7(1):29.
5. Yannuzzi LA, Fisher YL, Krueger A, Slakter J. Solar retinopathy: a photobiological and geophysical analysis. *Transactions of the American Ophthalmological Society*. 1987; 85:120.
6. Wu J, Seregard S, Algever PV. Photochemical damage of the retina. *Survey of ophthalmology*. 2006 Sep 1; 51(5):461–81.
7. Nakamura M, Komatsu K, Katagiri S, Hayashi T, Nakano T. Reconstruction of Photoreceptor Outer Layers after Steroid Therapy in Solar Retinopathy. *Case Reports in Ophthalmological Medicine*. 2018; 2018.