

An Unusual Presentation of Lung Carcinoma as Metastases to Skeletal Muscle

Nanda Patil¹, Jyoti Tele², Shoaib Khoja^{3*}

¹Professor, Department of Pathology, Krishna Institute of Medical Sciences Deemed to be University, NH4, Pune - Bangalore Highway, Dist.Satara, Agashivnagar, Malkapur, Maharashtra 415539, India

²Assistant Professor, Department of Pathology, Krishna Institute of Medical Sciences Deemed to be University, NH4, Pune - Bangalore Highway, Dist.Satara, Agashivnagar, Malkapur, Maharashtra 415539, India

³Tutor, Department of Pathology, Krishna Institute of Medical Sciences Deemed to be University, NH4, Pune - Bangalore Highway, Dist.Satara, Agashivnagar, Malkapur, Maharashtra 415539, India

*Corresponding author: Shoaib Khoja

| Received: 02.03.2019 | Accepted: 07.03.2019 | Published: 30.03.2019

DOI: 10.36347/sjmcr.2019.v07i03.010

Abstract

Case Report

Metastases to skeletal muscle from Non Small Cell Lung Cancer is rarely seen. Presence of skeletal muscle metastases from lung cancer suggest an aggressive disease. Though skeletal muscle accounts for about 50% of total body mass, metastases in skeletal muscle is seen very rarely. We present a case of adenocarcinoma of lung in a 45 years male patient presenting as metastasis in right thenar muscles.

Keywords: Adenocarcinoma, Metastases, Skeletal muscle, Thenar.

Copyright @ 2019: This is an open-access article distributed under the terms of the Creative Commons Attribution license which permits unrestricted use, distribution, and reproduction in any medium for non-commercial use (NonCommercial, or CC-BY-NC) provided the original author and source are credited.

INTRODUCTION

Cancer of the lung is the leading cause of cancer related mortality. Non Small Cell Lung Cancer (NSCLC) accounts for 80% of lung cancer which shows metastases to brain, liver, bone and adrenal glands [1, 2]. Metastases is rarely seen in skeletal muscle despite high vascularity and large mass of muscle tissue. In this study we aim to focus on a rare occurrence of metastasis of adenocarcinoma of lung to right thenar muscles

CASE REPORT

A 45-year male patient presented with rapidly growing, painless swelling in right thenar eminence with flexion deformity for past two months. Patient was

a chronic cigarette smoker and drinker. There was history of cough since one year. Patient also had weight loss over the past year. On Physical examination swelling was 1.5 cm in size. MRI of right-hand swelling showed a small soft tissue lesion in the right thenar region which was circumferential involving flexor pollicis longus tendon along its course, likely represent metastases.

In search of primary CECT Chest was done which showed primary lesion in right lung with metastatic bilateral lung nodules, lymphangitis carcinomatosa and metastatic mediastinal lymphadenopathy.

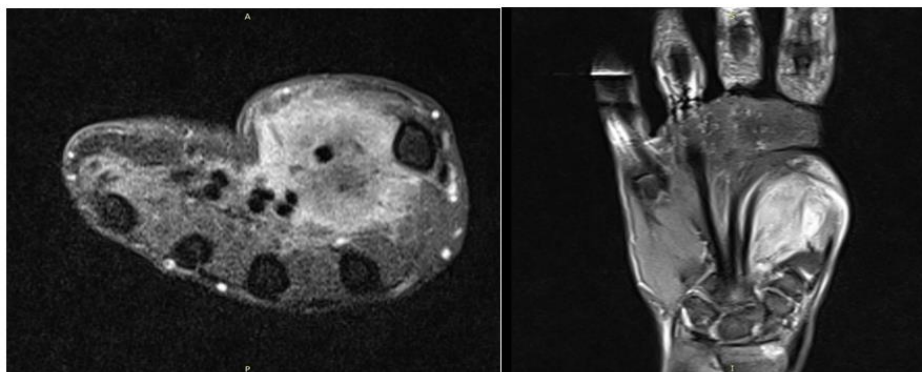


Fig-1: Axial and coronal section. MRI of right-hand swelling showed a small soft tissue lesion in the right thenar region circumferential involving flexor pollicis longus tendon along its course

The lesion on the thenar eminence was biopsied and received for histopathological examination in the form of multiple soft tissue cores.

Microscopy revealed deposits of well to moderately differentiated adenocarcinoma in soft tissue and skeletal muscle.

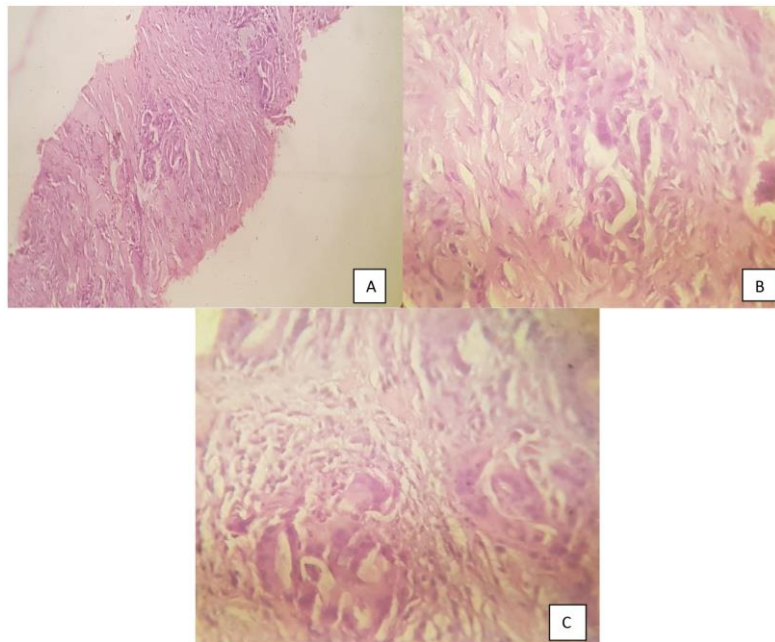


Fig-2: Deposits of adenocarcinoma in soft tissue and skeletal muscle in form of glands.
(A-100x H&E; B & C – 400x H&E)

DISCUSSION

Metastases of lung cancer to skeletal muscle is rarely reported in the literature with a reported prevalence of 2.3% [3, 4]. Soft tissue metastases from lung cancer spread by hematogenous route [5]. The commonest site for soft tissue metastases are abdomen, chest wall and back [6]. These soft tissue metastases clinically present as a rapidly growing solitary or multiple nodules which are firm, painless and covered with normal skin [7]. Among soft tissue, skeletal muscle is resistant to hematogenous metastases because of high metabolic activity producing lactic acid and free Oxygen radicals. Also low pH in the environment constitute an infertile medium for multiplication of tumor cells. In addition, mechanical factors like high tissue pressure, repeated contractions and widely alternating blood flow make the environment resistant for survival of cancer cells [8, 9]. Skeletal muscle metastases affect staging and prognosis of the tumor. Patient with adenocarcinoma and large cell carcinoma of lung show high risk for extrathoracic metastases. Lung is the commonest carcinoma site which leads to soft tissue metastases [3]. Metastases to soft tissue are considered as a sign of advanced cancer and it indicates a grave prognosis. It is difficult to differentiate skeletal muscle metastasis of lung cancer as a primary soft tissue sarcoma from metastatic carcinoma without doing a biopsy [10].

Subcutaneous metastases from a lung cancer are rare and ominous and highlight the significance of good physical examination. Diagnosis of soft tissue

metastases with the help of biopsies provide prognostic implications and help in avoiding invasive procedures. Also it helps in initiation of early treatment which can help in survival of patient. Our patient presented as rapidly growing painless soft tissue swelling over right thenar eminence with history of weight loss and respiratory symptoms. Thus biopsy of the lesion helped in making a definitive diagnosis and initiating treatment

CONCLUSION

Rapid and painless soft tissue swelling with weight loss can be an alarming sign of metastases. Histopathological examination of the biopsy of the lesion helps in establishing diagnosis as well as initiation of early treatment.

REFERENCES

- Schuchert MJ, Luketich JD. Solitary sites of metastatic disease in non-small cell lung cancer. *Current treatment options in oncology*. 2003 Jan 1;4(1):65-79.
- Quint LE, Tummala S, Brisson LJ, Francis IR, Krupnick AS, Kazerooni EA, Iannettoni MD, Whyte RI, Orringer MB. Distribution of distant metastases from newly diagnosed non-small cell lung cancer. *The Annals of thoracic surgery*. 1996 Jul 1;62(1):246-50.
- Perisano C, Spinelli MS, Graci C, Scaramuzzo L, Marzetti E, Barone C, Fabbriani C, Maccauro G. Soft tissue metastases in lung cancer: a review of

- the literature. *Eur Rev Med Pharmacol Sci*. 2012 Dec 1;16(14):1908-4.
4. Sinha N, Niazi M, Diaz-Fuentes G, Duncalf R. An innocent appearing subcutaneous nodule diagnoses a small cell lung cancer in a never-smoker female. *Case reports in oncological medicine*. 2014;2014.
 5. Spencer PS, Helm TN. Skin metastases in cancer patients. *Cutis*. 1987 Feb;39(2):119-21.
 6. Nguyen NC, Chaar BT, Osman MM. Prevalence and patterns of soft tissue metastasis: detection with true whole-body F-18 FDG PET/CT. *BMC Medical Imaging*. 2007 Dec;7(1):8.
 7. Pathak S, Joshi SR, Jaison J, Kendre D. Cutaneous metastasis from carcinoma of lung. *Indian dermatology online journal*. 2013 Jul 1;4(3).
 8. Perisano C, Spinelli MS, Graci C, Scaramuzzo L, Marzetti E, Barone C, Fabbriani C, Maccauro G. Soft tissue metastases in lung cancer: a review of the literature. *Eur Rev Med Pharmacol Sci*. 2012 Dec 1;16(14):1908-4.
 9. Pauli BU, Augustin-Voss HG, El-Sabban ME, Johnson RC, Hammer DA. Organ-preference of metastasis. *Cancer and Metastasis Reviews*. 1990 Nov 1;9(3):175-89.
 10. Tuoheti Y, Okada K, Osanai T, Nishida J, Ehara S, Hashimoto M, Itoi E. Skeletal muscle metastases of carcinoma: a clinicopathological study of 12 cases. *Japanese journal of clinical oncology*. 2004 Apr 1;34(4):210-4.