

## An Atypical Calcaneal Tuberosity Fracture: A Multi-Fragmented Avulsion Fracture and Surgical Treatment

Emre Kaya<sup>1\*</sup>, Özgür Erdoğan<sup>2</sup>

<sup>1</sup>Kartal Lütfü Kırdar Training & Research Hospital Orthopaedics & Trauma Department General hospital in Istanbul, Turkey  
<sup>2</sup>Haydarpaşa Numune Training & Research Hospital Orthopaedics & Trauma Department General hospital in Istanbul, Turkey

DOI: [10.36347/sjmcr.2019.v07i07.010](https://doi.org/10.36347/sjmcr.2019.v07i07.010)

| Received: 28.06.2019 | Accepted: 07.07.2019 | Published: 30.07.2019

\*Corresponding author: Emre Kaya

### Abstract

### Case Report

Avulsion fractures of the calcaneal tuberosity involve the insertion of the Achilles tendon to the posterosuperior aspect of the calcaneus and are usually caused by sudden muscular contraction of the Achilles tendon. Avulsion fractures of the calcaneal tuberosity involving one or two displaced fragment have been reported. In our case, there are numerous smaller pieces in addition to the two major displaced fragments. We decided to surgically treat this atypical fracture, which was very fragmented and displaced. Although we used suture anchor to stabilize the fracture, sufficient stability could not be obtained, so the tension band technique was used to strengthen the stabilization during surgery. In this case, we wanted to report the successful treatment of avulsion fractures of the calcaneal tuberosity via a tension band and suture anchor combinations that have not yet been reported.

**Keywords:** Avulsion, calcaneal tuberosity, tension band.

**Copyright © 2019:** This is an open-access article distributed under the terms of the Creative Commons Attribution license which permits unrestricted use, distribution, and reproduction in any medium for non-commercial use (NonCommercial, or CC-BY-NC) provided the original author and source are credited.

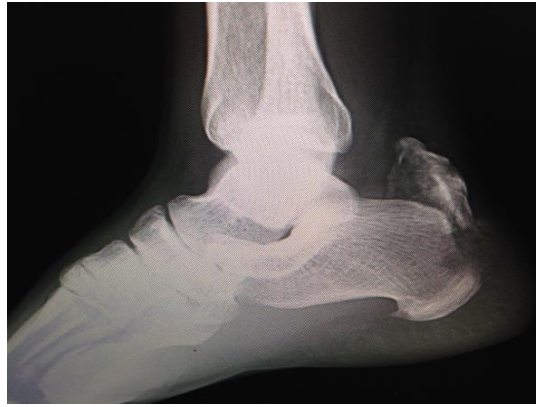## INTRODUCTION

Avulsion fractures of the calcaneal tuberosity localize to the posterosuperior aspect of the calcaneus without involving the subtalar joint. They are rare injuries, and avulsed calcaneal fractures comprise 1.3% to 2.7% of all calcaneal fractures. The most important mechanism of injury is dorsiflexion violence against the maximally plantar flexed foot. The other causes are powerful contraction of the triceps surae muscle with simultaneous extension of the knee and direct blunt blow to the hind foot [1, 2]. The recommended management of all displaced calcaneal tuberosity fractures is open reduction and internal fixation to allow restoration of the Achilles tendon insertion. This is because non-operative treatment of displaced calcaneal tuberosity fractures includes skin necrosis, Haglund's deformity, and loss of plantarflexion strength [3, 4]. Although avulsion fractures of the calcaneal tuberosity involving one or two displaced fragment have been reported, multi-partial avulsion fracture of the calcaneal tuberosity has not yet been previously reported [2, 6, 8,

9]. In this report, we describe the surgical management of an unusual multi-partial avulsion fracture of the calcaneal tuberosity caused by a direct blunt blow.

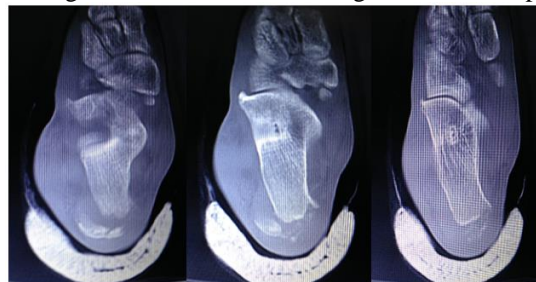## CASE REPORT

A 42-year-old male patient was admitted to another emergency center with a right ankle crush injury as a result of a car accident. A short leg splint application was performed at the admission of the patient and conservative treatment was suggested as a result of orthopedic consultation. The patient applied to our clinic for the purpose of control on the 3rd day after the trauma. At first examination, bone fragments disturbing the skin in the superolateral of the Achilles tendon insertion site was palpated. There was swelling and ecchymosis at the Achilles tendon insertion site. The patient could not actively do a plantar flexion and could not rise to the tip of his toes. The Thompson test was positive. A calcaneal tuberosity fracture was suspected and standard anteroposterior and lateral ankle radiographs were performed (image 1).



**Image-1: Multi-fragmented and displaced calcaneal tuberosity fracture**

A large multi-partial avulsed fragment was seen on the image, and CT was performed (image 2).



**Image-2: Axial CT image of the ankle. An atypical multi-fragmented calcaneus avulsion fracture**

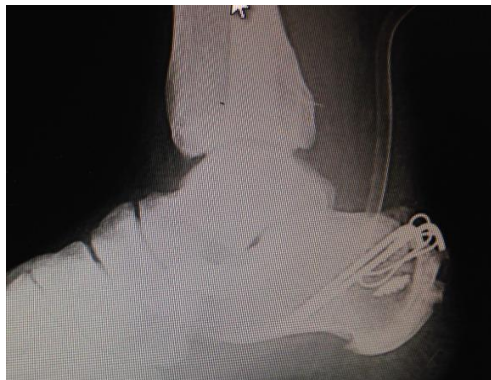Surgery was decided because of a lack of active plantar flexion, presence of multi-partial displaced fractures, and the presence of skin irritation. After examination of the CT images, it was clear that the fragments could not be stabilized, and thus screw and suture anchoring was performed. The patient was subjected to prophylactic antibiotics in a prone position under spinal anesthesia, and the ankle was positioned to stay outside the table.

The Achilles tendon and calcaneus were revealed by posterolateral incision. The fracture contained many small fragments alongside the larger fragments. First, suture anchors were sent in posterosuperior of the calcaneus to fix the Achilles tendon and broken fragments. However, the fracture was multi-fragmented and the fracture surface was too wide to fix it. We decided that stabilization could not be sufficiently increased with a second suture anchor, and

thus the tension band was used to support and make the fixation dynamic.

Two 1.5-mm Kirschner cores were placed obliquely to the base of the calcaneus at right angles to the Achilles insertion angle. A cerclage wire was used transversally to the posterior aspect of the calcaneus. The tension band technique was applied by rotating this cerclage wire around the Kirschner cores in a figure 8 shape.

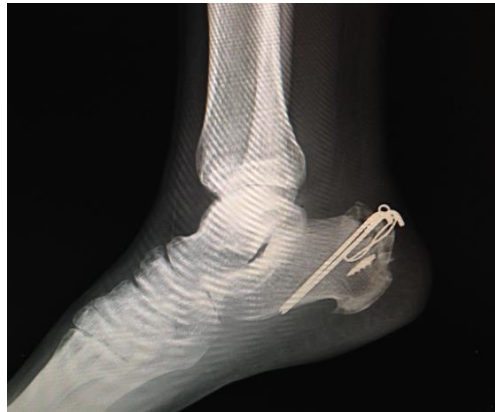The fracture was stable, and the passive ankle dorsiflexion and stability were not impaired. The crumbled bone fragments were fixated to the main fragment by using anchor spines. The plane was imaged with a scope and found to be suitable. The skin was closed, and the ankle was wrapped in long leg plaster in neutral (image 3).



**Image-3: Satisfactory anatomic reduction can be seen on the first postoperative day**

Three weeks after the operation, the ankle was moved to the lower leg walking plaster in the neutral position. At the end of the 6th week, the plaster was

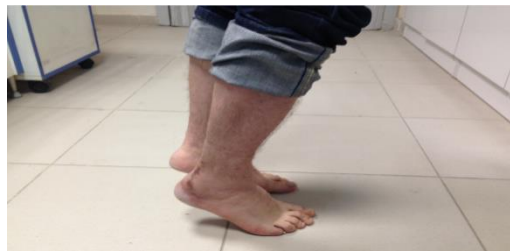removed and passive ankle movements were initiated. At the twelfth week, radiological union was observed and active ankle movements could begin (image 4).



**Image-4: A satisfactory healing in the lateral ankle graph at the twelfth postoperative week**

A skin tenderness caused by the Kirschner wire was detected in the control performed at the first postoperative year. The wire was removed with an additional surgical procedure, and no additional problems developed after the procedure. At the end of

the first year, the AOFAS score was 77 and painless full ankle ROM with good triceps surae muscle strength was detected. The patient could rise to the tip of his toes (image 5). At the end of the second year the AOFAS score increased to 86.

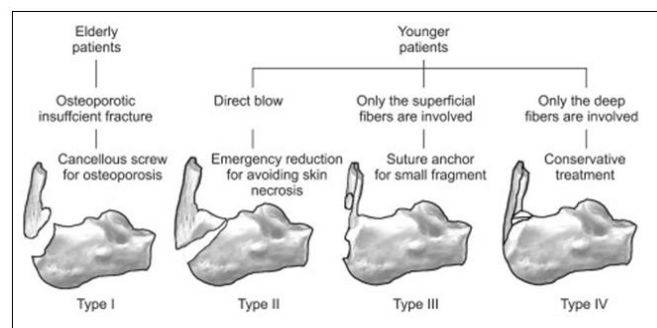


**Image-5: The patient was able to rise to the tip of the toes on the 6th postoperative month**

## DISCUSSION

There is limited information on surgical treatment of multi-fragmented calcaneal tuberosity fractures. In the fixation of such a fracture screw, the tension band method or anchoring methods may not be sufficient. There are some classification systems for calcaneus avulsion fractures. Recently, Lee *et al.* have

reported a new classification and treatment algorithm for different types of calcaneal tuberosity fractures [2]. Lee *et al.* offered an appropriate treatment option for each type of fracture (image 6). In this classification, the type 1 fracture is seen in aged osteoporotic patients. The other types are encountered in young patients.



**Image-6: Characteristics of the avulsion fracture of the calcaneal tuberosity and recommended treatment**

Our patient was 42 years old and had some features of both type 1 and type 3 fractures. Scanning fixation for large single-fragmented avulsion fractures such as type 1 is proposed according to the treatment

algorithm of this classification system. The fractures involving small fragments such as type 2 and type 3 should be treated with a suture anchor. In our case, we tried to fix this multi-fragmented fracture with anchor

so that it would not be possible to fix them with screws. Since we could not provide enough stability during surgery, we stabilized the fracture by supporting the tension band technique. Liu *et al.* reported a case of fracture of the sleeve type with small fragments that they recommended to fix with 2 suture anchors [5]. There was a multi-fragmented fracture in our case, and the tensile strength of the gastro-soleus complex was high. Thus, the suture anchoring was inadequate. None of the surgical techniques recommended in these solutions were suitable for our fracture type. We think that existing classification systems and treatment recommendations are inadequate, and the tension band method should be an alternative to surgical treatment.

Rijal *et al.* reported two fragmented fracture types as an atypical calcaneal tuberosity fracture [6]. They recommended screw fixation for avulsed fragment and reported successful results. However, the two fragments in their case were sufficiently large to allow screw fixing. Rijal *et al.* made additional attempts to remove the screw when the screw heads cause pain to the skin. In our case, we similarly made an additional attempt to remove the implants. Levi *et al.* reported the tension band technique in calcaneal tuberosity fractures with good results [7]. Recently, Nagura *et al.* reported three cases of osteoporotic elderly patients, which were treated successfully via the tension band technique in avulsion fractures of calcaneal tuberosity.

The most important disadvantages of the tension band method is pull-out as in the screw technique. This has skin problems and requires additional surgical interventions. The advantage is that it is a simple and powerful fixation method. As in our case, bringing together widely distributed fracture fragments in the horizontal plane and overcoming the pull resistance in vertical plane makes the tension band method preferable. If necessary, anchor support may be beneficial for the remaining small fragments and crumbling suture. Although there are clinical and biomechanical studies including anchor technique applied with screw technique, our study is the first to include a suture anchor applied with a tension band [9, 10].

Although there are risks such as the pull out of implants or irritation of the skin, we recommend that the suture anchor applied with the tension band technique especially in large and multiple fragmented

fractures. This is because of the strong and dynamic fixation of the Achilles tendon and early movement. In addition, we believe that the fracture type of our case should be included in the new classification and appropriate treatment options should be developed because the fracture type of our case does not conform to the latest defined classifications.

## REFERENCES

1. Cooper DE, Heckman JD. The heel of Achilles: Calcaneal avulsion fracture from gunshot wound. *Foot Ankle.* 1989; 9:204-205.
2. Lee SM, Huh SW, Chung JW, Kim DW, Kim YJ, Rhee SK. Avulsion fracture of the calcaneal tuberosity: Classification and its characteristics. *Clin Orthop Surg.* 2012 Jun; 4(2):134-8.
3. Beavis RC, Rourke K, Court-Brown C. Avulsion fracture of the calcaneal tuberosity: A case report and literature review. *Foot Ankle Int.* 2008 Aug; 29(8):863-6.
4. Squires B, Allen PE, and Livingstone J. Fractures of the tuberosity of the calcaneus. *J Bone Joint Surg [Br]* 83-B:55–61, 2001. <http://dx.doi.org/10.1302/0301-620X.83B1.11184>.
5. Lui TH. Fixation of Achilles tendon avulsion fracture. *Foot Ankle Surg.* 2009; 15(2):58-61.
6. Rijal L, Sagar G, Adhikari D, Joshi KN. Calcaneal tuberosity avulsion fracture: An unusual variant. *J Foot Ankle Surg.* 2012 Sep-Oct; 51(5):666-8.
7. Levi N, Garde L, Kofoed H. Avulsion fracture of the calcaneus: Report of a case using a new tension band technique. *J Orthop Trauma.* 1997 Jan; 11(1):61-2.
8. Nagura I, Fujioka H, Kurosaka M, Mori H, Mitani M, Ozaki A, Fujii H, Nabeshima Y. Modified tension band wiring fixation for avulsion of the calcaneus in osteoporotic bone: A review of three patients. *J Foot Ankle Surg.* 2012 May-Jun; 51(3):330-3.
9. Yoshida K, Kasama K, Akahane T. Avulsion fracture of the calcaneus treated with a soft anchor bridge and lag screw technique: A report of two cases. *J Foot Ankle Surg.* 2016 Mar-Apr; 55(2):310-3.
10. Khazen GE, Wilson AN, Ashfag S, Parks BG, Schon LS. Fixation of calcaneal avulsion fractures using screws with and without suture anchors: A biomechanical investigation. *Foot Ankle Int.* 2007. Nov; 28(11):1183-6.