

Cutaneous Penicilliosis by *Penicillium Marneffeii* in A Human Immunodeficiency Virus Infected Individual From A Tertiary Care Center of Tripura, North-East India

Tapan Majumdar¹, Mousumi Paul^{2*}, Santosh Majumder³

¹Associate Professor, Department of Microbiology, Agartala Government Medical College & GBP Hospital, Agartala, Pin no. 799006, Tripura, India

²Postgraduate trainee, Department of Microbiology, Agartala Government Medical College & GBP Hospital, Agartala, Pin no. 799006, Tripura, India

³Senior Medical Officer, ART Center, Agartala Government Medical College & GBP Hospital, Agartala, Pin no. 799006, Tripura, India

DOI: 10.36347/sjmcr.2019.v07i07.014

| Received: 20.07.2019 | Accepted: 27.07.2019 | Published: 30.07.2019

*Corresponding author: Mousumi Paul

Abstract

Case Report

Penicillium marneffeii infection is an important emerging public health problem, especially among patients infected with human immunodeficiency virus in the areas of endemicity in Southeast Asia, India, and China. Within these regions, it is regarded as an AIDS-defining illness, and severity of the disease depends on the immunological status of the infected individual [1]. We report a case of *Penicillium marneffeii* infection in a 28 years male under antiretroviral therapy for HIV infection. He was presented with papulo-nodular umbilicated skin lesions all over body and fever for 1 month. This is the first case report of *Penicillium marneffeii* from Tripura.

Key Words: *Penicillium marneffeii*, immune-compromised, dimorphic.

Copyright © 2019: This is an open-access article distributed under the terms of the Creative Commons Attribution license which permits unrestricted use, distribution, and reproduction in any medium for non-commercial use (NonCommercial, or CC-BY-NC) provided the original author and source are credited.

INTRODUCTION

Penicillium marneffeii also known as *Talaromyces marneffeii*, is the only known thermally dimorphic species of *Penicillium*, and it can cause both localized and lethal systemic infection in human being [2]. It is considered to be 3rd most frequent opportunistic pathogen in endemic areas after Tuberculosis & Cryptococcosis [2]. It is regarded as one of the AIDS defining illness. The fatal systemic infection by this fungus is known as Penicilliosis – may manifested with fever, anemia, hepatomegaly, generalized lymphadenopathy, soft tissue abscesses, papulo-nodular umbilicated skin lesions and chronic skin ulcers. The fungus is an opportunistic pathogen endemic in South East Asia and its neighbouring countries. In India it is mostly isolated from north-eastern states- Manipur, Nagaland, Mizoram, upper part of Assam [3],[4]. This is probably because of abundance of the bamboo groves, the habitat of bamboo rats which are the natural reservoir or carriers of *Penicillium marneffeii*. An individual usually get the infection when CD₄ T-lymphocytes count drops down to 60 cells/ul or below. Although *Penicillium marneffeii* infection is common in some of the regions of north-eastern India, but this is the first diagnosed case reported from Tripura.

CASE REPORT

A 28 years old Human Immunodeficiency Virus (HIV) infected truck driver attended ART Center with multiple papulo-nodular skin lesions with central umbilication all over the face & trunk (Figure 1) along with low grade fever for last 1-month duration. He had been diagnosed with HIV infection 3 months back & was under antiretroviral drugs along with tablet cotrimoxazole for the same duration. Multiple papules first appeared on the trunk and the extremities and later spread all over the skin. There was no oro-genital lesions. His body weight decreased 10 kg in last 1 month

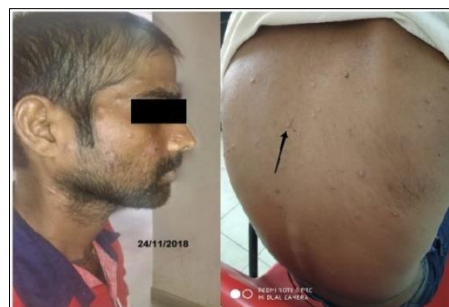

Fig-1: Nodulo-papular umbilicated Skin lesion (face & back)

On Physical examination findings were as follows: sensorium alert, blood pressure 110/70 mmHg, pulse 82 times/min, regular, respiration, 22 times/min, body temperature, 38.4°C. Multiple generalized papules were seen on the face, ear, chest, abdomen and the extremities with central umbonation on most of the lesion. There was no palpable lymphadenopathy, his chest was clear and his abdomen was soft and non-tender with no organomegaly.

Laboratory examination shows, his hemoglobin 6.5 g/dL, white blood cell count 3500/μL and platelet 210,000/μL, ESR 50mm/1st hr, Urea: 30mg/dL; Creatinine: 1.04 mg/dL. Peripheral CD4+ T lymphocyte count were 09 cells/μL. AST: 47 U/L; ALT: 42 U/L; HbsAg, Anti HCV and VDRL test: non-reactive, respectively. Automated Blood culture for bacterial & fungal agents done by BecT ALERT did not grow any organism after 7 days of incubation.

Slit skin smear was prepared, and the scrapped materials were further processed for isolation & identification of the causative organism. From the direct scrapped material Giemsa staining was done which was showing both intracellular & extracellular yeast cells with cross-walled septa (figure 2). Fungal culture was done on Sabourauds dextrose agar (SDA) and incubated at both 25°C & 37°C. After 5 days incubation at 25°C, the colony morphology appearance was wrinkled, folded, velvety, and grey-brown in colour with brownish red/wine colour diffusible pigmentation on reverse side (figure 3). After 12 days incubation, 37°C culture tube showed the presence of smooth cream coloured dry yeast like colonies without any pigmentation. Slide culture test was also performed. Lacto phenol cotton blue (LPCB) mount was done for morphological identification of the fungus. In LPCB mount from 25°C - short septate hyphae were seen with chains of elliptical smooth walled phialoconidia arising from ends of tapered phialides (Broom-stick appearance) (figure 4) and in 37°C - oval yeast cell with cross-septation were seen. Giemsa staining from 37°C culture tube was also corresponding with LPCB mount report (figure 5). Slide culture test was done for morphological confirmation of the isolated organism.

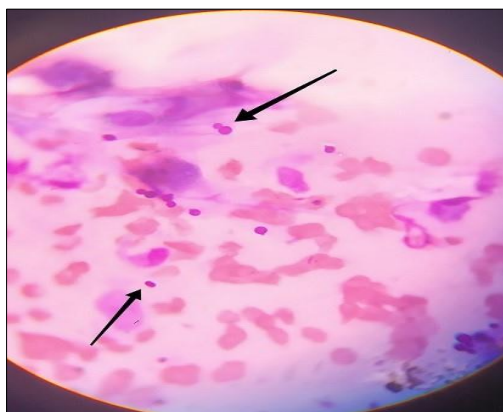


Fig-2: Giemsa stain showing cross-walled septate yeast cell (X 1000)

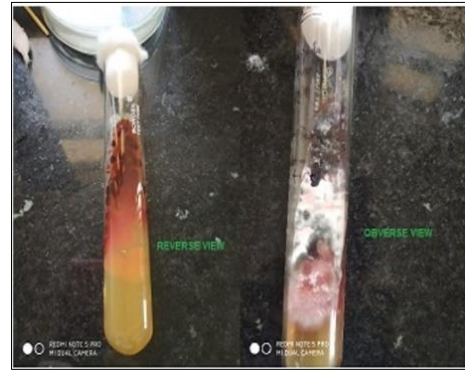


Fig-3: Colony character at 25°C SDA culture tube

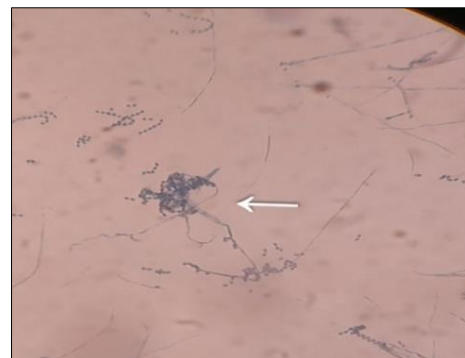


Fig-4: LPCB mount showing "Broom-stick" mold of *Penicillium marneffeii* (X 1000)

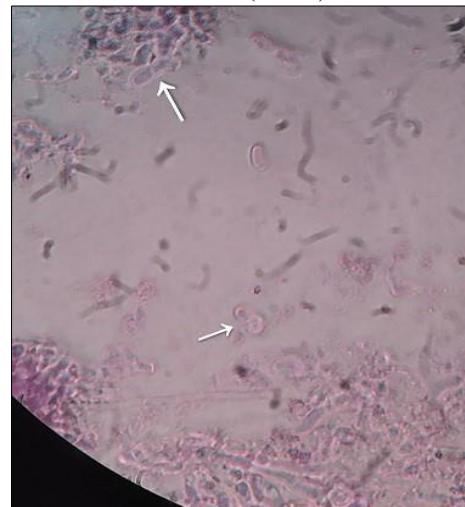


Fig-5: Giemsa stain showing "cross-walled" yeast cell (X 1000)

From the clinical history, clinical finding, macroscopic & microscopic morphology of the isolate, the presence of characteristic red diffusible pigment & the dimorphic nature of the isolate, it was identified as *Penicillium marneffeii*. The patient was prescribed with Tab Itraconazole 200 mg twice daily, but after 15 days of initiation of treatment, the patient expired.

DISCUSSION

Penicillium marneffeii infection is an important disease among HIV-infected in South-east Asia. Discovered in 1956 from bamboo rat *Rhizomys sinensis* in Vietnam, [2] *Penicillium marneffeii* was first

identified in an HIV-infected patients in 1988 [2]. Till date many cases are reported from our neighbouring State Manipur, but from Tripura this is the first laboratory confirmed case of *Penicillium marneffei* infection. This infection has been reported from non-endemic regions of India such as Tamil Nadu, Maharashtra, Assam, Meghalaya & Delhi [5-8]. The case from Delhi was a patient of immune restoration syndrome and was of Manipur origin [8].

The fungus is sensitive to Amphotericin B & Itraconazole. The current recommended treatment regimen is to give amphotericin B 0.6 mg/kg/day for 2 weeks followed by Itraconazole 400 mg/day orally in two divided doses for next 10 weeks [2].

CONCLUSION

The incidence of HIV infection and opportunistic mycotic infections are on the rise in this part of India. Penicilliosis is mostly seen in late HIV infection with CD4+ count less than 100/uL. Up to 80% or more of the cases have CD4+ count below 50/uL [9]. In our case at diagnosis patients CD4 count was only 09/uL. A robust screening mechanism especially for the high risk individuals along with high degree of clinical suspicion & appropriate laboratory test is the need of the hour to identify both HIV and Opportunistic infection, as early detection and prompt treatment is necessary to reduce mortality & morbidity.

REFERENCES

1. Vanittanakom N, Cooper CR, Fisher MC, Sirisanthana T. *Penicillium marneffei* infection and recent advances in the epidemiology and molecular biology aspects. *Clinical microbiology reviews*. 2006 Jan 1;19(1):95-110..
2. Jagadish C. Talaromycosis. In: Niranjan nayak. *Text book of Medical Microbiology*. 4th edition. Jypee: 2018; 506-523.
3. Sood N, Gugnani HC. Disseminated *Penicillium marneffei* infection in a Myanmar refugee from Mizoram state. *Indian Journal of Pathology and Microbiology*. 2010 Apr 1;53(2):361.
4. Singh PN, Ranjana K, Singh YI, Singh KP, Sharma SS, Kulachandra M, Nabakumar Y, Chakrabarti A, Padhye AA, Kaufman L, Ajello L. Indigenous Disseminated *Penicillium marneffei* Infection in the State of Manipur, India: Report of Four Autochthonous Cases. *Journal of clinical microbiology*. 1999 Aug 1;37(8):2699-702.
5. Maniar JK, Chitale AR, Miskeen A, Shah K, Maniar A. *Penicillium marneffei* infection: an AIDS-defining illness. *Indian Journal of Dermatology, Venereology, and Leprology*. 2005 May 1;71(3):202.
6. George M V, Gajanan P, Joy MS, Mary J, Renu G. Letter To Editor-Disseminated *Penicillium marneffei* infection in a Human Immunodeficiency Virus-infected individual. *Journal of postgraduate medicine*. 2004 Jul 1;50(3):235-6.
7. Sharma A, Hazarika NK, Barua P, Dey I, Tudu NK. *Penicillium marneffei* infection in a HIV infected child. *Indian Journal of Medical Research*. 2007 Dec 1;126(6):580.
8. Devi KR, Singh LR, Rajkumari R, Usharani M, Devi K, Singh TB. *Penicillium marneffei*--an indicator disease of AIDS: a case report. *Indian journal of pathology & microbiology*. 2007 Jul;50(3):674-6..
9. So SY, Chau PY, Jones BM, Wu PC, Pun KK, Lam WK, Lawton JW. A case of invasive penicilliosis in Hong Kong with immunologic evaluation. *American Review of Respiratory Disease*. 1985 Apr;131(4):662-5.