

## Ophthalmological Involvement in Scleromyxedema: A Case Report

Dr. Bencharki Youssra\*, Dr. Driouech Hind, Dr. Tamym Bouchra, Dr. Salek Hajar, Pr Berraho Amina

Department of Ophthalmology B, Hôpital Des Spécialités, Chu Ibn Sina, Rabat Morocco

DOI: 10.36347/sjmcr.2019.v07i07.017

| Received: 18.07.2019 | Accepted: 25.07.2019 | Published: 30.07.2019

\*Corresponding author: Bencharki Youssra

### Abstract

### Case Report

**Introduction:** Scleromyxedema, or papulosclerotic mucinosis, is a very rare chronic condition, often associated with extracutaneous manifestations. We report a case associated with a unilateral macular edema and treated effectively with melphalan and corticosteroids. **Case report:** We examined a 57-year-old woman with severe left visual loss and biopsy-proven scleromyxedema disease, by showing mucin deposition in the superficial dermis, diagnosed four months prior to the ocular involvement. The clinical exam showed the presence of skin-colored micropapules, in the face, the ear lobes, the neck and the upper part of the trunk; the face and hands had a sclerodermiform appearance. Meanwhile, the fundus examination found out a unilateral macular edema confirmed with an optical coherence tomography who showed the macular edema with intraretinal cystic spaces and retinal thickening. A monthly course of melphalan (16 mg / day combined with prednisone 2 mg / kg / day for 4 days / month) allowed disappearance of macular edema. And a clear improvement in cutaneous lesions. **Discussion:** Most information about scleromyxedema has been retrieved from anecdotal or single case reports. scleromyxedema is a chronic disease, with an unpredictable evolution. However, some lucky patients can have spontaneous clinical resolution. It can involve systemic implications, especially neurologic, cardiologic, and hematologic ones, entailing a guarded prognosis. Ocular manifestations are very rare. Rongioletti described this localization in a single patient in the form of bilateral macular edema. There is no specific definitive treatment and the therapeutic response varies greatly between patients. The use of IV immunoglobulins constitute a promising treatment as a first-line therapy, as it is relatively effective and safe for the treatment of both cutaneous and extracutaneous manifestations of scleromyxedema, especially ophthalmological involvement. **Conclusion:** macular edema is a rare ocular feature of scleromyxedema disease and may cause vision loss and scotomas which needs a specific treatment.

**Keywords:** Scleromyxedema, papulosclerotic mucinosis, micropapules.

**Copyright @ 2019:** This is an open-access article distributed under the terms of the Creative Commons Attribution license which permits unrestricted use, distribution, and reproduction in any medium for non-commercial use (NonCommercial, or CC-BY-NC) provided the original author and source are credited.

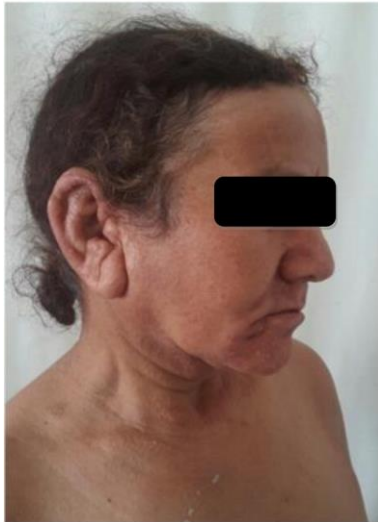## INTRODUCTION

Scleromyxedema, also known as diffuse/generalized and sclerodermoid lichen myxedematosus first defined by Arndt-Gottron [1], is a very rare chronic condition, often associated with extracutaneous manifestations. It is a primary cutaneous mucinosis characterized by a generalized, papular and sclerodermoid, cutaneous eruption that usually occurs in association with monoclonal gammopathy [2]. We report a case associated with a unilateral macular edema and treated effectively with melphalan and corticosteroids.

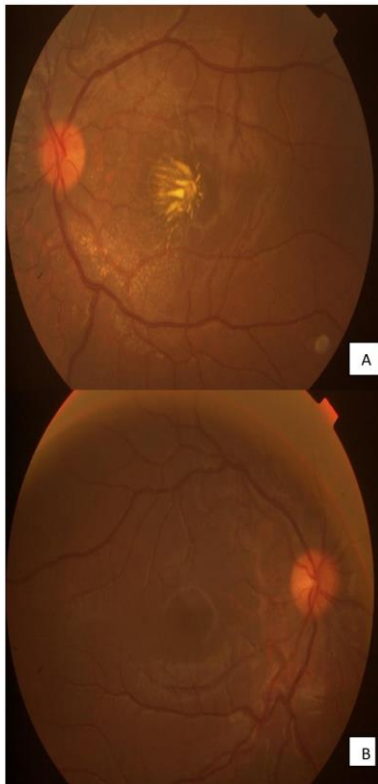
## Case Report

We examined a 57-year-old woman with severe left visual loss and biopsy proven scleromyxedema disease, by showing mucin deposition in the superficial dermis, diagnosed four months prior

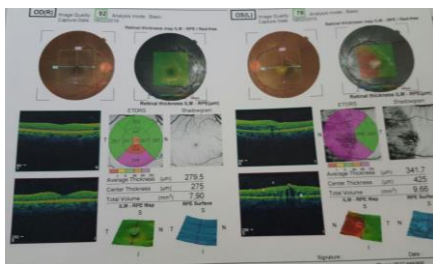
to the ocular involvement. The clinical exam showed the presence of skin-colored firm micropapules, in the face with a diffuse thickening of the skin, especially surrounding the lips, the ear lobes (Figure-1), the neck and the upper part of the trunk; the face and hands had a sclerodermiform appearance. Meanwhile, the fundus examination found out a unilateral macular edema (Figure-2) confirmed with an optical coherence tomography (Figure-3) who showed the macular edema with intraretinal cystic spaces and retinal thickening. A monthly course of melphalan (16 mg / day combined with prednisone 2 mg / kg / day for 4 days / month) allowed disappearance of macular edema. And a clear improvement in cutaneous lesions.



**Fig-1: Clinical appearance directly prior to initiating treatment with melphalon and corticosteroids – skin thickness decreased, papules became less visible**



**Fig-2: A: photographies du fond d’œil de l’œil droit montrant un œdème maculaire, B: photographie du fond d’œil de l’œil gauche**



**Fig-3: Optical coherence tomography shows intraretinal cystic spaces and retinal thickening near and within the foveola**

## DISCUSSION

Most information about scleromyxedema has been retrieved from anecdotal or single case reports. scleromyxedema is a chronic disease , with an unpredictable evolution. However, some lucky patients can have spontaneous clinical resolution. It can involve systemic implications, especially neurologic, cardiologic, and hematologic ones, entailing a guarded prognosis. Ocular manifestations are very rare [1]. Rongioletti described this localization in a single patient in the form of bilateral macular edema [2]. We also find as an ophthalmological manifestations: Corneal deposits [1, 3], thinning of the eyelid, ectropion.

The pathogenesis of scleromyxedema is not clear. The main hypothesis is the possible role of circulating cytokines, such as interleukin 1, tumor necrosis factor, and transforming growth factor- $\beta$ , known to stimulate glycosaminoglycan synthesis and fibroblast proliferation in the skin [4] , Many authors have also suggested that the paraproteins themselves might act as autoantibodies that stimulate fibroblasts to proliferate and overproduce mucin [5].

There is no specific definitive treatment for the disease, and the therapeutic response varies greatly between patients. The use of IV immunoglobulins constitute a promising treatment as a first-line therapy, as it is relatively effective and safe for the treatment of both cutaneous and extracutaneous manifestations of scleromyxedema, especially ophthalmological involvement [6, 7].

Therefore, the chronic course of this disease affects the patient mentally, thus psychological or psychiatric therapy may also be introduced in order to improve the results of systemic treatment [1].

## CONCLUSION

Scleromyxedema is a rare mucinous deposition disorder with a pathognomonic clinical presentation characterized by major organ complications that should be recognized as ophthalmological ones. Patients typically respond well to therapy as highlighted in our case.

## REFERENCES

1. Koronowska SK, Osmola-Mańkowska A, Jakubowicz O, Żaba R. Scleromyxedema: a rare disorder and its treatment difficulties. *Advances in Dermatology and Allergology/Postępy Dermatologii I Alergologii*. 2013 Apr;30(2):122.
2. Rongioletti F, Merlo G, Cinotti E, Fausti V, Cozzani E, Cribier B, Metze D, Calonje E, Kanitakis J, Kempf W, Stefanato CM. Scleromyxedema: a multicenter study of characteristics, comorbidities, course, and therapy in 30 patients. *Journal of the American Academy of Dermatology*. 2013 Jul 1;69(1):66-72.

3. Ramli I, Amarouch H, Bouhllab J, Aitourhroui M, Senouci K, Hassam B. *Une présentation caractéristique de scléromyxœdème associé à des manifestations oculaires. In Annales de Dermatologie et de Vénérologie 2015 Dec 1, 142(12), S627-S628. Elsevier Masson.*
4. Rongioletti F, Rebora A. Updated classification of papular mucinosis, lichen myxedematosus, and scleromyxedema. *Journal of the American Academy of Dermatology.* 2001 Feb 1;44(2):273-81.
5. Hummers LK. Scleromyxedema. *Current opinion in rheumatology.* 2014 Nov 1;26(6):658-662.
6. Blum M, Wigley FM, Hummers LK. Scleromyxedema: a case series highlighting long-term outcomes of treatment with intravenous immunoglobulin (IVIg). *Medicine.* 2008 Jan 1;87(1):10-20.
7. Bidier M, Zschoche C, Gholam P, Enk AH, Hadaschik EN. Scleromyxoedema: clinical follow-up after successful treatment with high-dose immunoglobulins reveals different long-term outcomes. *Acta dermato-venereologica.* 2012 Jul 1;92(4):408-409.