

Giant Palpebral Hemangioma of an Infant- Indication of Surgical Treatment: A Case Report

Bencharki Y.^{1*}, Nyinko Aboughé H.¹, Bouzoubaa T.¹, Tamym B.², El Hassan A.², Berraho A.¹

¹Ophthalmic Service B, Specialty Hôpital, CHU Ibn Sina, Rabat, Morocco

²Otolaryngology Département, Specialty Hôpital, CHU Ibn Sina, Rabat, Morocco

DOI: 10.36347/sjmcr.2019.v07i07.018

| Received: 15.07.2019 | Accepted: 22.07.2019 | Published: 30.07.2019

*Corresponding author: Bencharki Youssra

Abstract

Case Report

Introduction: Capillary hemangioma is a common benign tumor most often involving the skin of the eyelids and sometimes the eyelid and orbit or orbit only. It is more common in girls and present at birth or in the first months of life. We report the case of a child with a giant upper palpebral capillary hemangioma of the right eye. **Patients and Methods:** We describe a case of capillary palpebral hemangioma. A female infant of 2 years old, presented with a mass in the right upper eyelid causing a ptosis and amblyopia. A complete exam and a RMI and angiography were performed.

Results: Clinical examination revealed a palpebral sub-cutaneous tumor covered by a normal appearing skin with a deeper blue –purple color, with a firm consistency and extensive palpebral ptosis covering the entire cornea. The exam of the anterior and posterior segment was normal. MRI showed an aspect that first suggests a right venous angioma. The established treatment was based essentially on surgery immediately excisional with a skin graft. Histological examination confirmed the diagnosis. The evolution was marked by satisfactory progressive healing with weekly monitoring. **Discussion:** Capillary hemangioma is the most frequent benign tumor of the child, It usually requires just monitoring with therapeutic abstention because in most cases the regression is spontaneous. However, it can have sometimes severe consequences as vision loss, ocular mobility restrictions and more serious like amblyopia. Authors advocate medical treatments such as systemic corticosteroid therapy, beta blockers and intra-tumoral injections of corticosteroids. In our case, it is a giant capillary hemangioma with the risk of functional amblyopia. We opted for immediate surgery. Therefore, the management of hemangioma should take into consideration the age of patient, location, size of the lesion, and presence of complications. **Conclusion:** Palpebral angiomas are common and their management depends on several factors, corticosteroid injections and surgical excision are the treatments of choice. Depending on the case we must decide on a hierarchy of these different treatments, or even their possible association.

Keywords: Amblyopia, Children Eyelid Lesion, Corticosteroid, Infantile Periocular Hemangioma, surgery.

Copyright © 2019: This is an open-access article distributed under the terms of the Creative Commons Attribution license which permits unrestricted use, distribution, and reproduction in any medium for non-commercial use (NonCommercial, or CC-BY-NC) provided the original author and source are credited.

INTRODUCTION

Cavernous Hemangioma on the eyelid in children is a congenital benign tumor. It first tends to increase and then regress spontaneously usually around the age of one year. Two histological types predominate: capillary angioma and cavernous angioma. Lymphangiomas are exceptional [1].

It presents in different sizes and shapes, and present medical and cosmetic problems. MRI is the best test for the exploration of orbital pathology and allows the best soft tissue analysis. It provides a valuable contribution to accurate topographic diagnosis and tissue characterization. Amblyopia is often the mode of discovery of a capillary or palpebral angioma, but

remains, above all, the main complication to be feared and prevented. Most of the time a simple monitoring with management of a possible amblyopia is sufficient, but sometimes they require a more specific treatment. We report through a case of giant eyelid haemangioma the indication of the surgery in front of the risk of amblyopia.

PATIENTS AND METHODS

We report a case of a 2-year-old girl with a large eyelid hemangioma of the right eye causing ptosis and amblyopia (Figure 1). this tumor appears in the first several weeks of life; characterized by a rapid enlargement reaching the 90% of its full size by 1 year of age according to the parents then followed by 1 year

of no growth. A complete exam and a RMI and angiography were performed.. The treatment with intralesional injection of corticosteroids did not allow

any regression of the hemangioma and clearance of the visual axis. Surgical treatment was then undertaken.

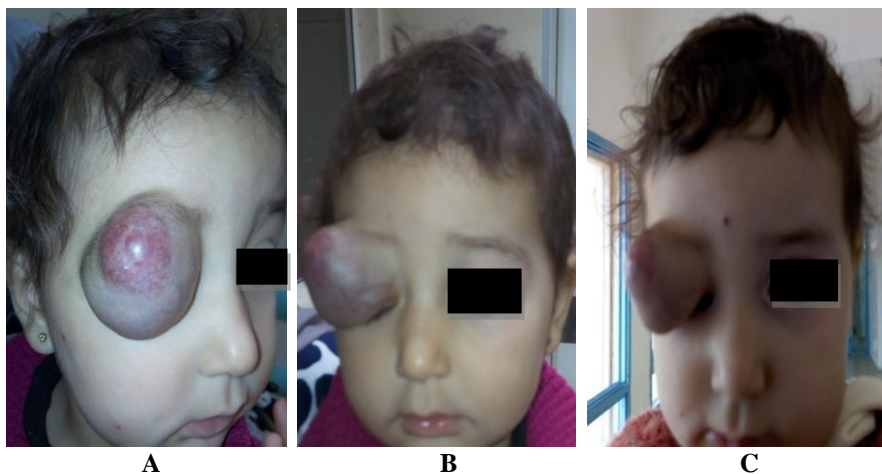


Fig-1:periocular infantile hemangioma of the eyelid of the right eye; (a) right profile vue (b), front vue, (c)left profile vue.

RESULTS

Clinical examination revealed a palpebral sub-cutaneous tumor covered by a normal appearing skin with a deeper blue –purple color, with a firm consistency and extensive palpebral ptosis covering the

entire cornea. The exam of the anterior and posterior segment was normal. MRI showed an aspect that first suggests a right venous angioma. The case was treated by surgical excision and did not persist any tumor residue (figure 2).

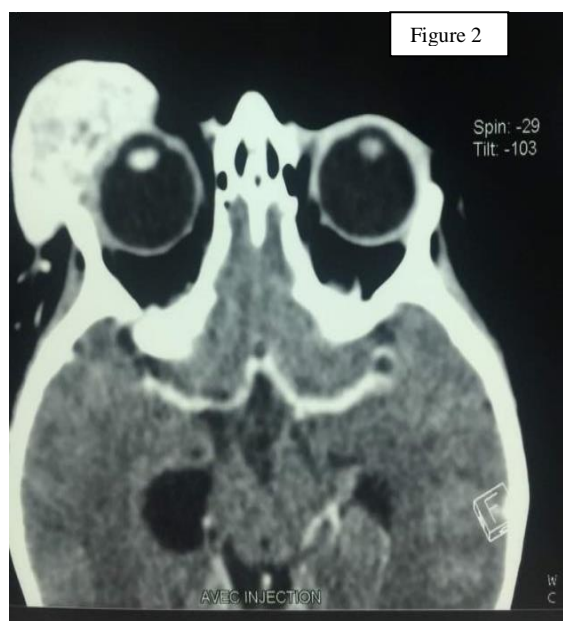


Fig-2 : a lesion of the upper eyelid, roughly oval, well limited, with a regular contour, with areas of greasy density intensely and heightened heterogeneously after contrast product injection, measuring: 40 * 38 * 23mm

Amblyopia was managed (correction of ametropia and intermittent occlusion of the healthy eye). However, oral corticosteroid therapy (Prednisone 1 mg / kg / day) for 1 month with associated measures was maintained, with progressive decay to avoid any

tumor rebound. Monitoring was reinforced at the time of decay of corticosteroid therapy. Histological examination confirmed the diagnosis. The evolution was marked by satisfactory progressive healing with weekly monitoring. (Figure 3)

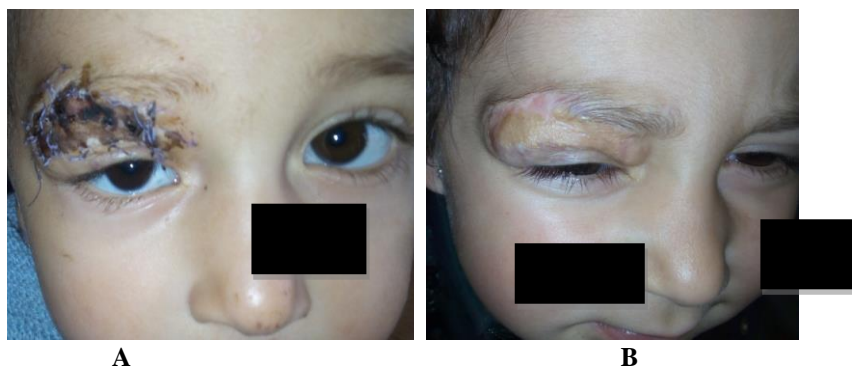

Fig-3: palpebral hemangioma Treatment for 2 Years old infant. (A) Day 14 post skin graft placement; (B) healed palpebral lesion 2 months post graft.

DISCUSSION

Capillary hemangioma is the most frequent benign tumor of the child, it requires just monitoring with therapeutic abstention because in most cases the regression is spontaneous. However, sometimes this lesions can have severe consequences. Authors advocate medical treatments such as systemic corticosteroid therapy, beta blockers and intra-tumoral injections of corticosteroids. Surgery is reserved for complicated cases. Surgical excision allows an immediate suppression of amblyogenic factors. On the other hand, tumor dissection is delicate because of the non-encapsulated nature of these tumors, increasing the risk of recurrence in case of incomplete excision and the risk of injuring anatomical elements of the neighborhood (vessels, tarsus, eyelid levator muscle in our case). Oral corticosteroid therapy, leads to a slower tumor regression, but with a significant general repercussion (in particular a risk of severe cortisone cardiomyopathy justifying echocardiographic and blood pressure monitoring) and a risk of rebound after stopping treatment [1].

In our case, it is a giant capillary haemangioma with the risk of functional amblyopia. We opted for immediate surgery. In case the medical treatment is not effective, surgery can be performed as both a diagnostic and therapeutic modality, and also for cosmetic purposes [3]. There is a high chance of bleeding and hemostasis should be considered especially in large masses [2]. Therefore, the management of hemangiomas should take into consideration several factors for the choice of treatment: the age of patient, location, size of the lesion, and presence of complications and sometimes even psychological damage [1,4].

We must always remember the high rate of spontaneous regression in cases of capillary angiomas, [5]. If a therapeutic indication is made, the benefits and risks of each option must be weighed in order to choose the treatment that will have the best result in order to restore visual function, prevent or treat amblyopia and respect the anatomical integrity of the face.

CONCLUSION

The palpebral involvement is particular because of the specific anatomy of the eyelids and their intimate relationship with the eye. The therapeutic decision is dictated by the spontaneous evolution or under treatment of the lesion [6] the surgery can be suggested early in infancy. It has a very good result in the release of the visual axis with a reeducation of the amblyopia.

Conflicts of Interest

There are no conflicts of interest

REFERENCES

- O'Keefe M, Lanigan B, Byrne SA. Capillary haemangioma of the eyelids and orbit: a clinical review of the safety and efficacy of intralesional steroid. *Acta Ophthalmologica Scandinavica*. 2003 Jun;81(3):294-8..
- Tavakoli M, Yadegari S, Mosallaei M, Aletaha M, Salour H, Lee WW. Infantile periocular hemangioma. *Journal of ophthalmic & vision research*. 2017 Apr;12(2):205..
- Levi M, Schwartz S, Blei F, Ceisler E, Steele M, Furlan L, Millman A, Kodsi SR. Surgical treatment of capillary hemangiomas causing amblyopia. *Journal of American Association for Pediatric Ophthalmology and Strabismus*. 2007 Jun 1;11(3):230-4.
- Garzon MC, Drolet BA, Baselga E, Chamlin SL, Haggstrom AN, Horii K, Lucky AW, Mancini AJ, Metry DW, Newell B, Nopper AJ. Comparison of infantile hemangiomas in preterm and term infants: a prospective study. *Archives of dermatology*. 2008 Sep 15;144(9):1231-2.
- Goyal R, Watts P, Lane CM, Beck L, Gregory JW. Adrenal suppression and failure to thrive after steroid injections for periocular hemangioma. *Ophthalmology*. 2004 Feb 1;111(2):389-95.
- H. Elouarradi, R. Daoudi. capillary hemangioma of the upper eyelid. *Pan Afr Med J*. 2014; 17: 175.