

Solanum Xanthocarpum Ethanol Extract Inhibits Mast Cell Degranulation in OVA-Sensitized Animals

Poonam Arora*, Ansari SH, Iram Nazish

Department of Pharmacognosy and Phytochemistry, School of Pharmaceutical Education and Research, Jamia Hamdard, New Delhi, India

DOI: 10.21276/sajp.2019.8.8.6

| Received: 05.08.2019 | Accepted: 16.08.2019 | Published: 21.08.2019

*Corresponding author: Poonam Arora

Abstract

Original Research Article

Aim of present study was to investigate the effects of *Solanum xanthocarpum* Schrad and wendl on degranulation of mast cells in abdominal mesentery of male albino rats. 4 groups of animals (6 animals per group) were used. All animals except group I were sensitized and challenged with ovalbumin (40 mg/rat) followed by treatment with standard dexamethasone or *S. xanthocarpum* ethanolic whole plant extract (0.5 mg/kg b.wt) (SXE). %Protection offered by drugs against mast cell degranulation was studied in isolated mesentery stained with toluidine blue. Number of mast cells with extruded granules and intact cells were counted under microscope (x45). Allergen treatment resulted in significant increase in number of degranulated mast cells compared to normal control group. After treatment with SXE for 28 days significant decrease (55±4.22%) in number of mast cell with extruded granules compared to ovalbumin control group were found. However, the effects were not found to be significant in animals treated with standard dexamethasone compared to ovalbumin control group. Results of study show powerful mast cell stabilizing property of *S. xanthocarpum* ethanolic whole plant extract.

Key words: *Solanum xanthocarpum*, dexamethasone, mast cells, ovalbumin, mesentery.

Copyright @ 2019: This is an open-access article distributed under the terms of the Creative Commons Attribution license which permits unrestricted use, distribution, and reproduction in any medium for non-commercial use (NonCommercial, or CC-BY-NC) provided the original author and source are credited.

INTRODUCTION

Mast cells are present in all over body especially skin, lungs, abdominal cavity and other mucosal tissues. These cells are associated with allergies and asthma. Cytoplasm of mast cells contains lipid bodies whose metabolism through arachidonic acid pathway results in production of leukotrienes [1]. Mast cells (MCs) are present in their inactive form which gets activated after interaction of an antigen/allergen with its specific IgE antibody bound to its high-affinity receptor (FcεRI) on the MC membrane.

Inhalation of an aeroallergen leads to crosslinking of membrane bound IgE via the allergen, inducing rapid release of mast cell mediators such as histamine, leukotrienes, proteases and prostaglandins, which can be detected in increased concentration in the broncho-alveolar lavage (BAL) of allergen challenged patients. On activation, degranulation releases a variety of granule-associated inflammatory mediators, including histamine, proteoglycans (heparin and chondroitin sulfate), and the neutral proteases (tryptase, chymase, and carboxypeptidase A [2]). These mast cell mediators have been implicated in inflammatory responses such as bronchospasm and airway

hyperresponsiveness in asthma, bronchoconstriction, mucus secretion, and mucosal edema, all characteristic features of asthma.

Mast cells not only play an important role in the induction of allergic airway disease in sensitized individuals, but also are involved directly in the induction of specific T cell responses to aeroallergens.

In the present study, role of an herbal drug extract, *S. xanthocarpum* on inhibition of mast cell degranulation was studied in a murine model of allergy. *S. xanthocarpum* is a well-known plant with multiple medicinal uses such as anti-allergic, anti-histaminic, immunomodulatory, anti-inflammatory, and many more. It is also an important component of antiasthmatic ayurvedic formulations [3].

MATERIALS AND METHODS

Chemicals: All chemicals and reagents used in study were purchased from authentic source. Ovalbumin was purchased from sigma Aldrich.

Experimental design

Albino wistar rats were procured from Jamia Hamdard Animal House Facility and approval was obtained for conducting studies on animals. For induction of allergy, animals were sensitized and challenged with ovalbumin as per method described [3] with some modifications. Each animal (except Group I) was sensitized with i.p. injection of allergen suspension containing ovalbumin, 40 mg and aluminum hydroxide, 2 mg, on day 1. After 15 days of sensitization, animals were challenged by exposure to aerosol consisting of 1% ovalbumin in normal saline for 20 min. Group I animals were treated similarly but 0.9% saline was used instead of OVA suspension. All treatments were done from day 1 to day 28.

Mast cell study

Evaluation of mast cell degranulation

After respective drugs treatments, anterior abdomen was cut opened and the mesentery was dissected away from the small intestine. Several contiguous well-vascularized mesenteric windows were cut and placed immediately in beakers containing Ringer Locke solution (in mM: NaCl 154, KCl 5.6, CaCl₂ 2.2, NaHCO₃ 6.0 and dextrose 5.5) for 30 ± 1 min. The pieces of mesentery were fixed overnight in solution consisting of 4% formaldehyde in 0.1 M phosphate buffer, pH 7.4. After fixation, excess fatty layers and adhering small intestine tissues were carefully removed from mesentery. The trimmed tissues were stained for 15 min in a solution containing 50% ethanol, 10% formaldehyde (HCHO), 5% Acetic acid and 0.2% toluidine blue. Stained pieces of mesentery were mounted and covered with cover slips taking care of any folds or stretching. Mast cells are readily identifiable by their metachromatic cytoplasmic granules which stain purple after staining with blue colour of aqueous toluidine blue [3, 4].

The stained and mounted mesentery was viewed within each circular × 20 field of view under an optical digital microscope (motic, B1 series system microscope with field area 1.13 mm²). One microscopic field was taken as the area encompassed the by the graticule of 10x eye piece i.e, 1cm², here, 40x and 100x. The first 10 mast cells were examined, starting from the left hand side of the field and proceeding clockwise. About 10 microscopic fields were counted for each mesenteric window to total of 100 mast cells.

Mast cell degranulation was assessed by counting the % of cells with extruded granules. Intact and degranulated mast cells were identified. The sole criterion for calling a cell "degranulated" was presence of intracellular granules released into the surrounding tissue i.e., the mast cells which did not show disruption of their surface membranes were counted as intact ones and those which showed partial or complete discontinuity of their cell membranes with one or more

extruded purple stained granules were counted as degranulated mast cells.

STATISTICAL ANALYSIS

Results were reported as mean ± S.E.M. Statistical analyses were performed using one-way analysis of variance (ANOVA) followed by *post hoc* Tukey's test.

RESULTS

Number and extent of degranulation of mast cells in OVA control rats were significantly high ($p < 0.001$) compared to normal control. Treatment with *S. xanthocarpum* ethanol extract (SXE) at dose levels (0.6 mg/kg b.w.) offered significant ($p < 0.05$) protection to mast cells against allergen induced degranulation in OVA sensitized rats. SXE exhibited reduction in disruption of mast cells by 55±4.22% compared to OVA control group. In the study, the effect obtained with standard dexamethasone (2.5 mg/kg b.w.) were lesser than that observed with herbal drug treatment (Table 1; Figure 1 and 2) revealing potent mast cell stabilizing effects of *S. xanthocarpum* whole plant ethanol extract (SXE) in rats.

Table-1: Effect of *S. Xanthocarpum* treatment on degranulation of abdominal mast cell of allergic rats

Groups	Entact mast cells	% degranulation	% protection
NC	15±0.428	15	-
OVA	89±3.71 ^{###}	89±3.77 ^{###}	0
OVA+DEX	72±4.22*	72±4.16	19.10±4.08*
OVA+SXE	55±3.81*	45±3.77*	55±4.22*

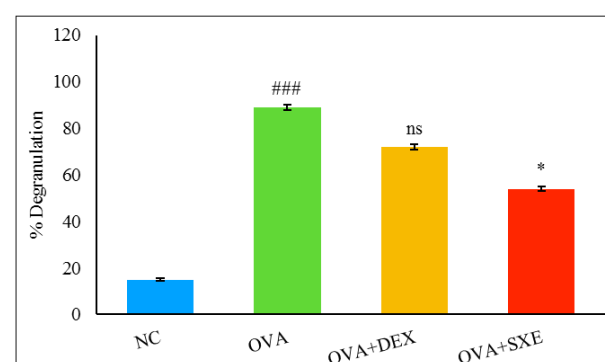


Fig-1: Effect of *S. Xanthocarpum* treatment on mast cell degranulation in abdominal mesentery of OVA-sensitized+treated rats. Values shown are mean ± S.E.M. (n = 6); ^{###} $p < 0.001$ compared to the normal control (NC); * $p < 0.05$, ns (non-significant) compared to OVA-control (OVA); OVA+DEX, 2.5 mg/kg, b.w; OVA+SXE, 0.6 mg/kg, b.w.

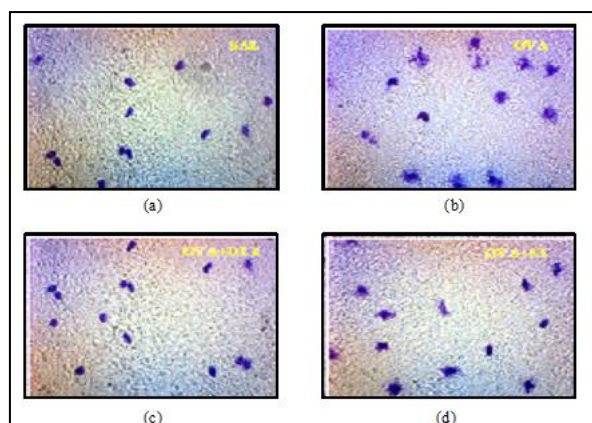


Fig-2: Effect of *S. Xanthocarpum* treatment on mast cell degranulation in abdominal mesentery of OVA-sensitized+treated rats (X45). Normal control (NC or Sal); OVA-control (OVA); OVA+DEX, 2.5 mg/kg, b.w.; OVA+SXE, 0.6 mg/kg, b.w

DISCUSSION

In the present study, a highly significant protection of rat peritoneal mast cells from disruption by SXE at dose (0.6 mg/kg b.w.) indicates prominent mast cell stabilizing activity of formulation which may be mediated by multiple mechanism including inhibition of Ca^{2+} mobilization, possible modulation of FcεRI surface (IgE Fc receptors) or/and inhibition of formation of radical oxygen species in activated mast cells which represent potentially important targets for regulating mast cell activity in allergic conditions.

MCs are believed to be important in the pathogenesis of asthma, specifically in association with a Th2-like phenotype. MCs were among the first cells associated the pathogenesis of asthma and allergies through type I IgE-mediated hypersensitivity reactions, likely through activation of epithelial MCs [5, 6].

CONCLUSION

Finding of present study shows significant inhibition of *S. xanthocarpum* ethanolic extract demonstrating mast cell stabilizing property of the herbal extract. Further study is warranted to identify potential mechanism of action of the plant in this direction.

REFERENCES

1. Merritt LF, Sally EW. Mast Cells, Their Subtypes, and Relation to Asthma Phenotypes. *Annals of Amer. Thoracic Society*. 2013; 10; S158-S164. <https://doi.org/10.1513/AnnalsATS.201303-064AW>.
2. Krystal-Whittemore M, Dileepan KN, Wood JG. Mast Cell: A Multi-Functional Master Cell. *Front Immunol*. 2016;6(6):620.
3. Arora P, Ansari SH, Anjum V, Mathur R, Ahmad S. Investigation of anti-asthmatic potential of Kanakasava in ovalbumin-induced bronchial asthma and airway inflammation in rats. *Journal of ethnopharmacology*. 2017 Feb 2; 197:242-9.
4. Arora P, Ansari SH, Najmi AK, Anjum V, Ahmad S. Investigation of anti-asthmatic potential of dried fruits of *Vitis vinifera* L. in animal model of bronchial asthma. *Allergy, Asthma & Clinical Immunology*. 2016 Dec;12(1):42.
5. Da Silva EZ, Jamur MC, Oliver C. Mast cell function: a new vision of an old cell. *J Histochem Cytochem*. 2014;62(10):698-738.
6. Amin K. The role of mast cells in allergic inflammation. *Resp. Med*. 2012; 106:9-14.