

Gallstone Ileus of the Sigmoid Colon: Rare cause of Bowel Obstruction in a Case Report

Zakaria Elbarkaoui^{1*}, Lotfi Azzouz¹, Iliass Maouni¹, Taib Lachguer¹, El Mahjoub Echerrab¹, Mohamed El Absi¹, Mohamed El Ounani¹, El Hassan El Alami¹

¹Department of Visceral Surgical Emergencies, Ibn Sina University Hospital Rabat, Morocco

DOI: [10.36347/sasjs.2023.v09i06.004](https://doi.org/10.36347/sasjs.2023.v09i06.004)

| Received: 11.03.2023 | Accepted: 26.04.2023 | Published: 06.06.2023

*Corresponding author: Zakaria Elbarkaoui

Department of Visceral Surgical Emergencies, Ibn Sina University Hospital Rabat, Morocco

Abstract

Case Report

A gallstone ileus is a rare cause of intestinal obstruction, caused by the migration of a gallstone through an entero-biliary fistula and its impact in the digestive system, most often in the ileocecal valve. We report here the case of a 60-year-old woman who was admitted for a biliary ileus at the sigmoid level, which is an even rarer cause of intestinal obstruction. The fistula was located between the colon and the gallbladder. The gallstone was surgically removed by colotomy, without treating the fistula and afterwards. The follow-up was without complications. Surgical closure of an enterobiliary fistula is an option that should be considered, but it may result in higher morbidity. Therefore, we chose not to do it, especially considering that spontaneous fistula closure can occur.

Keywords: Gallstone Ileus, Gallbladder, Enterobiliary Fistula.

Copyright © 2023 The Author(s): This is an open-access article distributed under the terms of the Creative Commons Attribution 4.0 International License (CC BY-NC 4.0) which permits unrestricted use, distribution, and reproduction in any medium for non-commercial use provided the original author and source are credited.

INTRODUCTION

A gallstone ileus is a rare cause of bowel obstruction [1]. The colon is a rare site of impaction (3.0%-4.1% of cases) [2]. It occurs mostly in elderly subjects with a history of diverticulitis because it can lead to a reduction in the diameter of the sigmoid [3]. This cause of bowel obstruction should be suspected in the presence of pneumobilia [4].

Treatment options include endoscopic extraction of the gallstone, endoscopic lithotripsy, and one- or two-stage surgery [3].

Here we report a rare and unusual case of gallstone ileus of the sigmoid colon as a cause of intestinal obstruction.

A 60-year-old woman was admitted to the emergency department of the Ibn Sina Rabat University

Hospital with complaints of abdominal pain, vomiting, and absolute constipation.

The patient had a history of sigmoid diverticular disease but no history of cholecystitis or other disease. The patient's physical examination revealed a distended abdomen with left iliac fossa tenderness, but no evidence of peritonitis.

Biochemical and hematological examinations revealed a CRP of 30 mg/l and a white blood cell count of 9000/mm³. Liver function tests and serum amylase were completely normal.

The patient underwent a CT scan that showed a fistulous connection of the gallbladder with the colon and a 3-cm impacted opacity in the sigmoid associated with distension of the bowel. Another gallstone of 2 cm was found in the gallbladder (Figure 1).

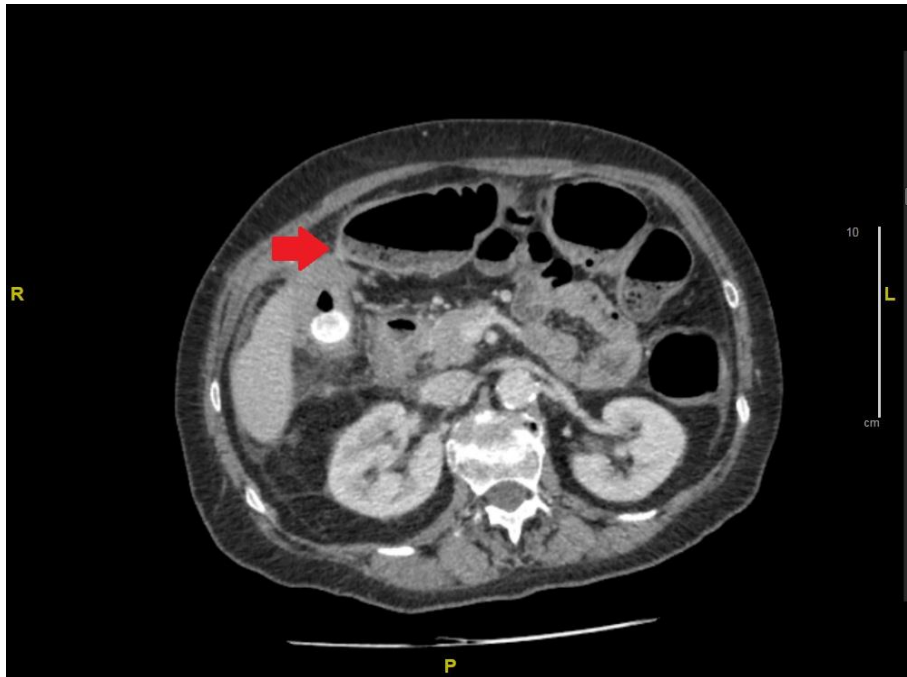


Figure 1: Image montrant une fistule entre la vésicule biliaire et le côlon

The patient underwent surgery and a laparotomy was performed with a colotomy to remove the gallstone. The colon was closed with direct sutures

without colostomy. The fistulous connection was identified but not treated to reduce the risk of complication (Figure 2).

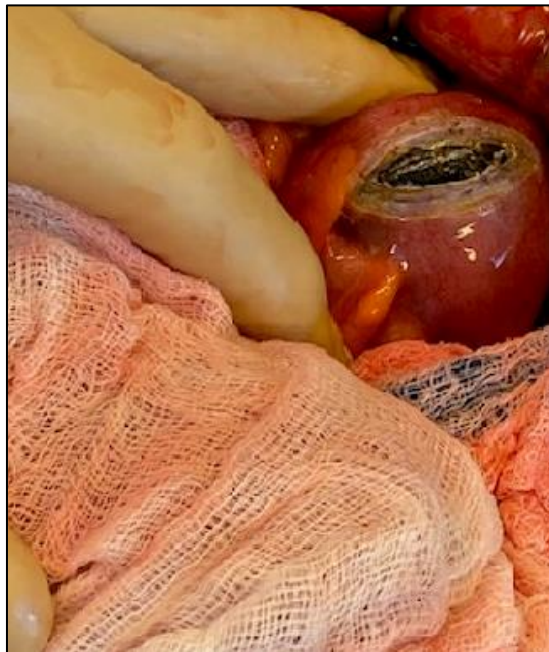

Figure 2: Vue opératoire montrant un calcul enclavé après la colotomie

Postoperative follow-up was uneventful, with rapid recovery of normal bowel function, and the patient was discharged on day 7.

DISCUSSION

Gallstone ileus is a rare complication of cholestasis [1]. It may account for two to five percent of mechanical bowel obstructions, but in patients over 60 years of age, it may cause up to one quarter of bowel

obstructions. Therefore, when treating symptoms of bowel obstruction, biliary ileus should be considered, especially in elderly women, as it is 5 to 15 times more likely in women [9, 10].

Enterobiliary fistulas are an uncommon complication of cholecystitis (1.5-5% of cholecystectomies) [1] and usually occur with the

duodenum (nearly 75% of enterobiliary fistulas); cholecystocolic fistulas are rare (10-20%) [10].

Gallstone ileus is rare and frequently occurs in the ileum (50.0%-60.5%), jejunum (16.1%-26.9%), duodenum (3.5%-14.6%) and colon (3.0%-4.1%) [6-8].

In cases of impaction on the colon, such as ours, the impaction is due to intestinal stenosis caused by diverticulitis [9]. Cholecystocolic fistulas are extremely rare (only 2-8% of biliary ileus) and are due to cholecystocolic fistulas [1].

Contrast-enhanced CT has high sensitivity (93%), specificity (100%), and accuracy (99%) for the diagnosis of biliary ileus [11].

Treatment options include endoscopic extraction of the gallstone, endoscopic lithotripsy, and one- or two-stage surgery [4]. Endoscopic lithotripsy may not be effective as it has been shown to be successful in patients with obesity and gas-containing bowel loops [12] and cases of fragment re-impaction have been reported [13].

Surgery is indicated for gallstone removal and fistula closure, but what is important to know is whether it should be performed in one or two stages. One-stage surgery may be associated with a higher mortality rate and longer hospital stay [2, 14]. Two-stage surgery is associated with a risk of recurrence, retrograde cholecystitis, and cancer development due to the remaining cholecysto-intestinal fistula [6].

CONCLUSION

Biliary ileus of the sigmoid colon is a very rare cause of intestinal obstruction, especially in elderly patients. Although endoscopic treatment is not always feasible. Surgery remains the final option. However, surgeons should choose the type of surgery according to the patient's general condition.

REFERENCES

1. Carlsson, T., & Gandhi, S. (2015). Gallstone ileus of the sigmoid colon: an extremely rare cause of large bowel obstruction detected by multiplanar CT. *BMJ Case Rep.*, 18, 2015209654-10.10.1136/bcr-2015-209654
2. Clavien, P. A., Richon, J., Burgan, S., & Rohner, A. (1990). Gallstone ileus. *British Journal of Surgery*, 77(7), 737-742.
3. Inukai, K. (2019). Gallstone ileus: a review. *BMJ Open Gastro*, 6, 000344-10.
4. Mazine, K., Barsotti, P., Elbouhaddouti, H., & Taleb, K. A. (2017). Iléus biliaire colique: une cause rare d'occlusion colique [Colonic gallstone ileus: a rare cause of colonic obstruction]. *Pan Afr Med J.*, 11, 187.
5. Ploneda-Valencia, C. F., Gallo-Morales, M., Rinchon, C., Navarro-Muñiz, E., Bautista-López, C. A., De la Cerda-Trujillo, L. F., ... & López-Lizarraga, C. R. (2017). Gallstone ileus: An overview of the literature. *Revista de Gastroenterología de México (English Edition)*, 82(3), 248-254.
6. Cooperman, A. M., Dickson, E. R., & ReMine, W. H. (1968). Changing concepts in the surgical treatment of gallstone ileus: a review of 15 cases with emphasis on diagnosis and treatment. *Ann Surg*, 167, 377-839.
7. Wakefield, E. G., Vickers, P. M., & Walters, W. (1963). Cholecystoenteric fistulas. *Surgery*, 54, 716.
8. Osman, N., Subar, D., Loh, M. Y., & Goscimski, A. (2010). Gallstone ileus of the sigmoid colon: an unusual cause of large-bowel obstruction. *Hpb Surg*, 2010(153740), 153740.
9. Anselme, P. (1981). Colonic gall-stone ileus. *Postgrad Med J.*, 57, 62-5.
10. Hernandez, C., Heuman, D., & Vlahcevid, Z. R. (1988). Pathophysiology of disease associated with deficiency of bile acids. Principles and practice of gastroenterology and hepatology. New York. *Elsevier Science Publishing*, 384, 95.
11. Yu, C. Y., Lin, C. C., Shyu, R. Y., Hsieh, C. B., Wu, H. S., Tyan, Y. S., ... & Chen, C. Y. (2005). Value of CT in the diagnosis and management of gallstone ileus. *World journal of gastroenterology: WJG*, 11(14), 2142-7.
12. Dumonceau, J. M., Delhay, M., Devière, J., Baize, M., & Cremer, M. (1997). Endoscopic treatment of gastric outlet obstruction caused by a gallstone (Bouveret's syndrome) after extracorporeal shock-wave lithotripsy. *Endoscopy*, 29(04), 319-321.
13. Alsolaiman, M. M., Reitz, C., Nawras, A. T., Rodgers, J. B., & Maliakkal, B. J. (2002). Bouveret's syndrome complicated by distal gallstone ileus after laser lithotripsy using Holmium: YAG laser. *BMC gastroenterology*, 2(1), 1-4.
14. Halabi, W. J., Kang, C. Y., Ketana, N., Lafaro, K. J., Nguyen, V. Q., Stamos, M. J., ... & Demirjian, A. N. (2014). Surgery for gallstone ileus: a nationwide comparison of trends and outcomes. *Annals of surgery*, 259(2), 329-335.