

Anemia Due to Familial Vitamin B12 Deficiency: About 3 Cases

N. Attari^{1*}, N. Anssari¹, L. Hsissen¹

¹Department of Pediatric Hematology and Oncology, Children's Hospital C.H.U, Faculty of Medicine and Pharmacy of Rabat, Mohammed V University, Rabat, Morocco

DOI: [10.36347/sasjm.2023.v09i06.021](https://doi.org/10.36347/sasjm.2023.v09i06.021)

| Received: 01.05.2023 | Accepted: 05.06.2023 | Published: 14.06.2023

*Corresponding author: N. Attari

Department of Pediatric Hematology and Oncology, Children's Hospital C.H.U, Faculty of Medicine and Pharmacy of Rabat, Mohammed V University, Rabat, Morocco

Abstract

Case Report

Vitamin B12 deficiency is a rare pathology in the paediatric population, most often due in our Moroccan context to a deficiency in intake. However, in rarer cases, it may be the result of an inborn anomaly in cobalamin transport or metabolism. A well-codified diagnostic approach can clarify the nature of the deficiency and adapt therapeutic options. We report 03 pediatric cases of three brothers treated for vitamin B12 deficiency. Diagnosed at 8, 4 and 3 years of age, they all presented with a severe anemic syndrome and delayed stature, two of them had seizures, and the elder brother was also delayed at school. Given the familial nature of the disease and the presence of proteinuria in 2 patients, Imerslund-Grasbäck disease was suspected in our patients. Treatment was based on parenteral vitamin B12 supplementation, with good clinical and biological progression in our patients. Vitamin B12 deficiency is a metabolic emergency and should be considered in the presence of hematological and neurological disorders. Although Imerslund-Grasbäck disease is rare, it should be suspected and proteinuria investigated.

Keywords: paediatric population, Vitamin B12 deficiency, metabolism, Imerslund-Grasbäck disease.

Copyright © 2023 The Author(s): This is an open-access article distributed under the terms of the Creative Commons Attribution 4.0 International License (CC BY-NC 4.0) which permits unrestricted use, distribution, and reproduction in any medium for non-commercial use provided the original author and source are credited.

INTRODUCTION

Vitamin B12 (cobalamin) deficiency is a rare pathology in the paediatric population, most often due in our Moroccan context to a deficit in intake following a vegetarian diet in children, or exclusive breastfeeding in infants of malnourished mothers, strict vegetarians or those suffering from Biermer's disease. However, in rarer cases, it may be the result of an inborn anomaly in cobalamin transport or metabolism. A well-coded diagnostic approach enables the nature of the deficiency to be determined, and therapeutic options to be adapted.

Clinical manifestations are polymorphous. They include hematological, neurological, digestive, mucocutaneous and vascular disorders.

We report 03 pediatric observations of three brothers treated for vitamin B12 deficiency in the pediatric hematology and oncology department (SHOP) at the children's hospital of the Ibn Sina University Hospital in Rabat, with a review of the literature.

REPORTS

Case n° 1

K, 8-year-old boy, 1st of four siblings, from a consanguineous marriage. Hospitalized on 11/10/2012 at SHOP, for management of anemic syndrome.

History of illness 4 years prior to admission, with onset of asthenia and headaches, evolving in a context of anorexia and weight loss. Examination revealed pallor of the skin and mucous membranes, with retarded growth and weight. The haemogram revealed an aregenerative macrocytic anaemia (Hb 9.8 g/dl, VGM 105 μm^3 , CCMH 35.4 pg, reticulocytes 21920/mm³), and leukopenia (WBC 2530/mm³, PNN 580/mm³). Myelogram showed dysmyelopoiesis with medullary megaloblastosis. FOGD showed non-specific chronic interstitial duodenitis without villous atrophy or crypt hyperplasia. Serum vitamin B12 levels were decreased to 83 pg/ml and proteinuria was negative.

The diagnosis of megaloblastic anemia due to vitamin B12 deficiency was retained, and the patient was put on vitamin therapy with hydroxocobalamin IVL 1000 $\mu\text{g}/\text{week}$ for four weeks, then one injection per month, with normalization of hematological parameters and restoration of vitamin B12 reserves, but

appearance 2 years later of generalized tonic-clonic convulsive seizures, put on Depakine with notion of school delay.

Case 2

A, brother of K, aged 4 years, the fifth of six siblings, He was hospitalized on 04/03/2019 at SHOP, for management of anemic syndrome.

HDM began 2 years prior to his admission, with the onset of asthenia, pallor and headaches, evolving in a context of anorexia and uncalculated weight loss. Clinical examination revealed a pale child, with slightly discoloured conjunctivae, delayed stature (-2DS) and a cafe-au-lait spots on the abdomen. The haemogram revealed an aregenerative macrocytic anaemia (Hb 9.8 g/dl, GMV 105 µm³, MCHC 35.4 pg, reticulocytes 21920/mm³), associated with leukopenia (WBC 2530/mm³, NNP 580/mm³), and thrombocytopenia (platelets 154000/mm³). Myelogram showed dysmyelopoiesis with medullary megaloblastosis. Vitamin B12 levels were decreased to <50 pg/ml and proteinuria was positive at 0.71g/L. Given the brother's history and the presence of proteinuria, Imerslund's disease was suspected. The

patient was put on lifelong hydroxocobalamin-based vitamin therapy with good progression.

Case 3

M, brother of K and A, aged 3, the sixth of six siblings, hospitalized on 04/03/2019 at SHOP, for management of anemic syndrome. Followed for juvenile myoclonic convulsions on Depakine for 2 years.

Symptoms began 4 months prior to admission, with the onset of anemia. Clinical examination revealed a pale child, with slightly discolored conjunctivae and delayed stature (-2DS), A myelogram showed dysmyelopoiesis with medullary megaloblastosis. Vitamin B12 levels were decreased to 90 pg/ml and proteinuria was positive at 0.54g/L. The diagnosis of Imerslund's disease was therefore evoked. The patient was put on lifelong hydroxocobalamin-based vitamin therapy with good progression.

The patient is now 6 years old, still receives a weekly injection of hydroxycobalamin, and has been off depakine for 2 years.

Table 1: Summary table of the characteristics of our 3 cases

	Case 1:A	Case 2: K	Case 3: M
Age at diagnosis	8 years	4 years	3 years
Sex	Male	Male	Male
History	-	brother treated for anemia due to vitamin B12 deficiency	juvenile myoclonic convulsions + 2 brothers treated for anemia due to vitamin B12 deficiency
Symptoms	Anemia syndrome staturo-ponderal delay	Anemia syndrome statural delay	Anemia syndrome statural delay
Vitamin B12 levels in pg/ml	83	<50	90
Treatment	Hydroxocobalamin for life	Hydroxocobalamin for life	Hydroxocobalamin for life
Evolution	generalized tonic-clonic convulsive seizures + school delay	good evolution	good evolution + Depakine discontinuation

DISCUSSION

Vitamin B12 (cobalamin) is a water-soluble molecule that plays a vital role in the maturation of rapidly-renewing tissues, particularly in the synthesis of deoxyribonucleic acid (DNA). Vitamin B12 deficiency is a rare condition in the paediatric population [1, 2]. According to the US National Health and Nutrition Examination Survey 27 (NHANES), prevalence is estimated at less than 1% in children and adolescents [3]. Pawlak *et al.*, reported a prevalence of between 25 and 86% in children and between 21 and 41% in adolescents [4].

Clinically, the symptoms are polymorphic. It is mainly represented by an anemic syndrome, delayed height and weight, digestive syndrome, mucocutaneous signs and neuropsychological signs such as delayed psychomotor acquisition, seizures, hypotonia and polyneuropathy.

Our study included 3 cases, all belonging to the same family (brothers). Our patients were diagnosed at the age of 8/4/3 years, and all presented with a severe anemic syndrome with delayed stature, two of them with seizures, and the eldest brother with delayed schooling.

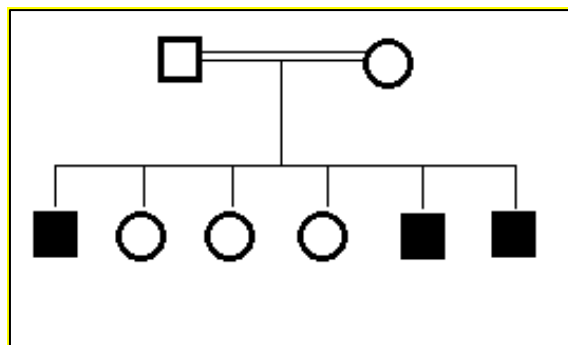


Figure 2: Genealogy tree

Biologically, vitamin B12 deficiency is responsible for an aregenerative macrocytic anemia with medullary megaloblastosis. Pancytopenia is also possible, especially in cases of profound deficiency. Vitamin dosage is the key diagnostic test. Cerebral CT and MRI are useful in the presence of neurological signs, and can detect abnormalities such as cerebral atrophy, thinning of the corpus callosum, hydrocephalus or delayed myelination [5].

Its etiologies are diverse and result from three different mechanisms: deficient intake, which is the most frequent mechanism, malabsorption and innate errors in the transport and metabolism of this vitamin.

In our patients, given the familial nature of the disease and the presence of proteinuria in 2 patients, Imerslund-Grasbäck disease was evoked: Imerslund-Grasbäck disease (IG) is a genetic form of megaloblastic anemia due to vitamin B12 deficiency, and is an autosomal recessive disorder caused by selective malabsorption of the intrinsic factor-cobalamin complex (IF-Cbl) by the terminal ileum. Described in 1959 by Imerslund and in 1960 by Gräsbeck, it is a rare disease (250 published cases) [1], mainly observed in Norway, Finland and the Middle East. Elsewhere, it is sporadic [1, 2]. It is associated with megaloblastic anemia occurring in childhood, often between the ages of one and five, after depletion of hepatic Cbl stocks, and associated with moderate proteinuria [2, 3]. Confirmation is based on urinary and genetic studies of cubilin (receptor for FI-Cbl complex), and on exclusion of other causes of Cbl deficiency: vitamin B12 levels are low, intrinsic factor levels are normal, and gastric intrinsic factor antibodies are absent. The Schilling test is essential for differential diagnosis, and shows an uncorrected absorption defect after the addition of intrinsic factor [4, 5].

In most cases, the molecular basis of selective malabsorption and proteinuria involves a mutation in one of two genes, cubilin (CUBN) on chromosome 10 or amnionless (AMN) on chromosome 14. Both proteins are components of the intestinal receptor for vitamin B(12) intrinsic factor complex and the receptor mediating tubular reabsorption of primary urine proteins.

Unfortunately, it was not possible to carry out a molecular study in our patients. Treatment is based on parenteral vitamin B12 supplementation.

We emphasize the importance of careful questioning and a thorough clinical examination, as well as the determination of serum vitamin B12 levels, in the event of any statural-ponderal delay or neurological disorders, even in the absence of anemia, as neurological symptoms may precede anemia by several months [6]. In our study, two of our patients developed neurological complications as a result of the disease: the first developed generalized convulsions with school delay during treatment, and the second juvenile myoclonic convulsions, which were successfully treated with vitamin B12 supplementation.

Progression is usually favourable under treatment, and early diagnosis and treatment determine the prognosis, especially neurological, by preventing progression of the disease and the onset of neurological sequelae such as learning difficulties or behavioural disorders, secondary epilepsy or mental retardation [7].

CONCLUSION

Vitamin B12 deficiency is a metabolic emergency and should be considered in the presence of hematological and neurological disorders. Although Imerslund-Gräsbeck disease is rare, it should be suspected and proteinuria investigated. Because it is autosomal recessive, a family investigation should be carried out.

REFERENCES

1. Khakee, S., Stachewitsch, A., & Katz, M. (1974). Selective vitamin B12 malabsorption in two siblings. *Canadian Medical Association Journal*, 110(1), 53-55.
2. Masson, E. P186 - Le deficit en vitamine B12 cause rare de l'anémie de l'enfant. EM-Consulte n.d. <https://www.em-consulte.com/article/260201/article/p186-le-deficit-en-vitamine-b12-cause-rare-de-lane> (accessed March 12, 2022).
3. Allen, L. H. (2009). How common is vitamin B-12 deficiency?. *The American journal of clinical*

- nutrition*, 89(2), 693S-696S. <https://doi.org/10.3945/ajcn.2008.26947A>.
4. How prevalent is vitamin B(12) deficiency among vegetarians? - PubMed n.d. <https://pubmed.ncbi.nlm.nih.gov/23356638/> (accessed March 12, 2022).
 5. Taskesen, M., Yaramis, A., Pirinccioglu, A. G., & Ekici, F. (2012). Cranial magnetic resonance imaging findings of nutritional vitamin B12 deficiency in 15 hypotonic infants. *European journal of paediatric neurology*, 16(3), 266-270. <https://doi.org/10.1016/j.ejpn.2011.08.005>.
 6. Serin, H. M., & Arslan, E. A. (2019). Neurological symptoms of vitamin B12 deficiency: analysis of pediatric patients. *Acta Clinica Croatica*, 58(2), 295-302. <https://doi.org/10.20471/acc.2019.58.02.13>.
 7. Bousselamti, A., El Hasbaoui, B., Echahdi, H., & Krouile, Y. (2018). Psychomotor regression due to vitamin B12 deficiency. *Pan African Medical Journal*, 30(1). <https://doi.org/10.11604/pamj.2018.30.152.12046>.