

## Etiological Profile of Bilateral Papillary Edema in Young Subjects at the CHU-IOTA – Bamako

Brainima Coulibaly<sup>1\*</sup>, Oumar Diallo<sup>2</sup>, Salimata Diallo<sup>3</sup>, Aissatou Simaga<sup>1</sup>, Modibo Sissoko<sup>1</sup>, Rouky Djibril Sangaré<sup>1</sup>, Fatoumata Tata Sidibé<sup>1</sup>, Seydou Diallo<sup>1</sup>, Tenin Traoré<sup>4</sup>, Abdoulaye Napo<sup>1</sup>, Nouhoum Guirou<sup>1</sup>, Japheth Pobanou Thera<sup>1</sup>

<sup>1</sup>University Hospital Center-IOTA, Bamako, Mali

<sup>2</sup>Ophthalmology Department, “Luxembourg” University Hospital Center in Bamako, Mali

<sup>3</sup>Neurology Department of CHU Gabriel Touré, Bamako, Mali

<sup>4</sup>Pediatrics service of the referral health center of Commune VI, Bamako, Mali

DOI: [10.36347/sjmcr.2023.v11i06.062](https://doi.org/10.36347/sjmcr.2023.v11i06.062)

Received: 24.05.2023 | Accepted: 19.06.2023 | Published: 24.06.2023

\*Corresponding author: Brainima Coulibaly  
University Hospital Center-IOTA, Bamako, Mali

### Abstract

### Original Research Article

**Introduction:** Papillary edema is the clinical expression of various conditions. This is fluid and/or axonal swelling of the optic nerve head due to blockage of axoplasmic flow at the level of the cribriform plate. The aim of our study was to assess the etiological aspects of bilateral papillary edema in young subjects and their impact on vision. **Patients and Method:** This was a 36-month prospective study, January 1, 2018 to December 31, 2020 including all young patients aged 15 to 40 followed for papilledema at CHU-IOTA Bamako. **Results:** Ninety-four affected eyes were collected in 47 patients, with a female predominance of 76.6%. Our average age was 25.7 years and the sex ratio 0.31. Papillary edema was bilateral in 100% of cases. Stasis papilledema due to intracranial hypertension (ICH) was the most common etiology (91.5%). Intracranial hypertension was idiopathic in 74.5% of cases and secondary in 25.7% of cases. In idiopathic ICH the main risk factor was overweight found in 78.3% of cases (all women) followed by taking oral contraceptives with 21.7% and alcoholism in 7.7%. Secondary ICH resulted from tumor or compressive (55.6%), infectious and cerebral thrombophlebitis (22.2%) each. **Conclusion:** This prospective study including 47 patients for papilledema without obvious cause highlighted the frequency of intracranial hypertension as the main etiology.

**Keywords:** Bilateral papilledema, young, etiologies.

Copyright © 2023 The Author(s): This is an open-access article distributed under the terms of the Creative Commons Attribution 4.0 International License (CC BY-NC 4.0) which permits unrestricted use, distribution, and reproduction in any medium for non-commercial use provided the original author and source are credited.

## INTRODUCTION

Papillary edema is the clinical expression of various conditions. It is fluid and/or axonal swelling of the optic nerve head due to blockage of axoplasmic flow at the level of the cribriform plate [1].

Its exact pathogenesis remains unknown. However, it seems that the main mechanism behind papilledema is an interruption of axoplasmic flow at the level of the optic nerve head. In fact, a slowing down of this anterograde axoplasmic flow at the level of the cribriform plate would lead to turgidity of the axons of the preliminary portion of the optic nerve [2Van Stavern GP Optic disc edema Semin Neurol 2007; 27: 233-243], which results in the fundus (FO) by papilledema.

Its diagnosis is easy and requires etiological research and optimal etiological treatment. The diagnosis of papilledema is above all clinical and is

based on examination of the fundus which will reveal either manifest edema or, on the contrary, simple papillary turgor or blurred papillary contours [3].

The appearance of papilledema is not specific to an etiology. The etiological diagnosis, which is sometimes complex, is therefore based on the association of clinical and paraclinical arguments [2].

The objective of our study was to assess the etiological aspects of bilateral papillary edema in young subjects and their impact on vision.

## PATIENTS/METHODS

**This was a prospective study.**

The study was carried out over a period of 36 months from January 1, 2018 to December 31, 2020. Were included all the patients youth consenting aged 15-40 follow-ups for bilateral papilloedema. The papillary

edema of retinal affections, of the CRVO type, were not included.

Each patient benefited from a meticulous questioning, a complete ophthalmological examination, a neurological examination, additional examinations: cerebral imaging (Systematic CT), Retinal Angiography, Optical Coherence Tomography (OCT) and Goldman Visual Field (CV) and a cardiovascular assessment depending on the case. The variables studied related to the socio-demographic characteristics

of the patients (age, sex, etc.), functional signs, signs of ophthalmological examination (visual acuity and fundus), the appearance of the papilledema on color retinophotographs, the results of neurological examinations, cerebral imaging, biological examinations carried out initially and finally the etiological diagnosis retained. We used Dandy's modified criteria for the diagnosis of idiopathic or so-called benign intracranial hypertension found in table I [4].

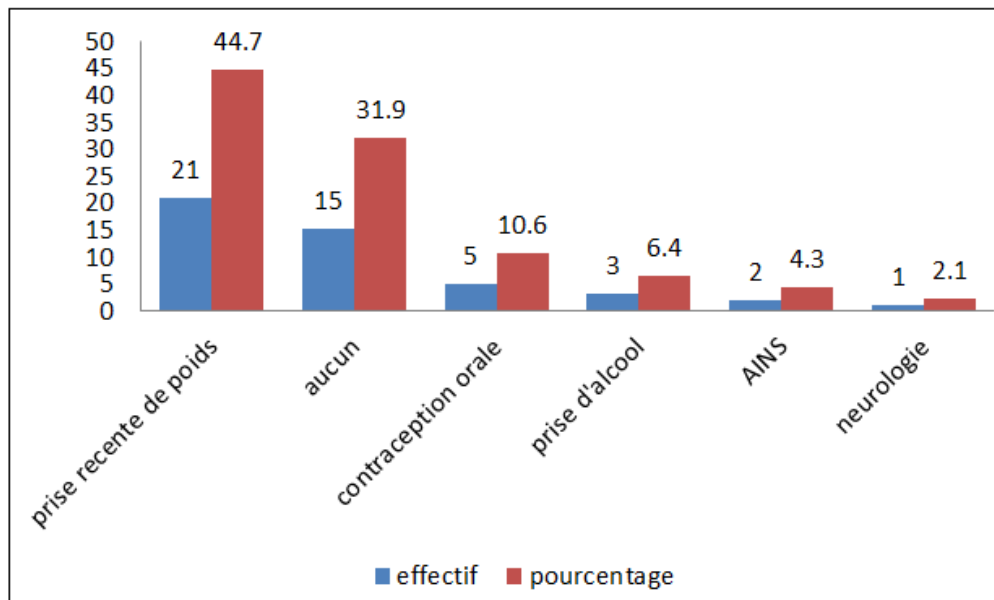
**Table I: Statistical analysis was performed using the software.**

The definitive diagnosis can be made if the patient fulfills criteria A to E.
The diagnosis is probable if the patient fulfills criteria A to D, but the blood pressure LCS is < 25 cm of water
A. Stasis papilledema
B. Neurological examination normal, except for paralysis of the VI
C. Neuroimaging: normal brain parenchyma without hydrocephalus, expansive process intracranial, or structural abnormality, and absence of meningeal enhancement on MRI without and with contrast product. Venous angio-MRI is necessary in patients atypical; if MRI is unavailable or contraindicated, a brain scan without and with contrast product can be done in combination with a venous CT angiogram with contrast product.
D. Normal composition of the LCS
E. Elevated CSF opening pressure ( $\geq 25$ cm of water in adults and $\geq 28$ cm of water in children [25 cm of water if the child is not sedated and not obese]) obtained from a lumbar puncture performed in lateral decubitus

## RESULTS

During the study period we collected forty-seven patients with an average age of 25.7 years, with a

female predominance of 76.6% (n = 36) and sex/ratio of 0.31. Among the associated risk factors, we noted recent weight gain in 48.9% of our patients (Figure I).



**Figure I: Risk factors**

Headaches were the most frequent functional sign with 42.6% (n= 20), followed by loss of visual acuity with 31.9% (n= 15). Visual acuity was less than or equal to 3/10 in 38.3% of patients (n=18). Of a total of 94 eyes included, the papilledema was bilateral in 100% of cases and asymmetrical in 19.1% of cases

(n=9). Stasis papilledema was the most common type found in 91.5% of cases (n = 39).

The neurological examination was almost normal except in 4 cases (2 cases of meningeal syndrome and 2 cases of pyramidal syndrome).

In terms of additional examinations, optical coherence tomography (OCT) performed in 36.2% of patients showed fiber thickening in the majority of cases. The retinal angiography performed confirmed the papilledema in 100% of cases. The Goldman visual field performed in 23.4% showed an enlargement of the blind spot. Lumbar puncture was deemed necessary and performed in 42.3% of patients (n=20) and was sterile in 90%. Brain imaging (CT) with and without injection of contrast product was performed in the 47 patients

and was normal in 80.9% of cases (n=38). MRI was performed in 2 patients confirming the diagnosis of cerebral thrombophlebitis. Biological assessment revealed hypochromic microcytic anemia in one patient.

The main etiology retained after the various examinations was intracranial hypertension (ICH) in 74.5% (n=35). Of a total of 35 cases of ICH, 25.7% (n=9) were of secondary origin (tumor, infection and thrombophlebitis) and 74.3% (n=26) were idiopathic.

**Table II: Overall characteristics and causes of papilledema**

Types	Origins	Causes or factors found	Case Name	%
OPB of stasis	HIC secondary	Meningitis	2	25,7
		Brain tumor	5	
		Cerebral thrombophlebitis	2	
	HIC Idiopathic	Obesity	18	74,3
		Alcohol	2	
		Anemia	1	
Oestrogens		5		
OPB vascular	cardiovascular	malignant hypertension	5	10,6
OPB inflammatory	Optic neuritis	Papillitis	5	10,6
OPB traumatic	Trauma	Head trauma	2	4,3

In our sample, idiopathic intracranial hypertension (ICH) was mainly found in 88.5% of women (n=23) with an average age of 21.4 and overweight. The main risk factors found in these women were being overweight and taking oral contraceptives with 78.3% (n=18) and 21.7% (n=5) respectively. Idiopathic intracranial hypertension was found in 11.5% of men with alcoholism as the main risk factor.

On the therapeutic level, the majority of our patients were put on Acetazolamide tablets at an initial dose of 1 gram and a half per day and then a decreasing dose of 750 mg/day. The use of corticosteroid therapy was not systematic. Two patients benefited from an evacuating lumbar puncture for therapeutic purposes. The treatment also took into account the etiology and correction of the risk factor. The evolution was favorable with total regression of the papilledema in 87.2%. Papillary edema evolved into optic atrophy in 6 cases, i.e. 12.8%. We noted an overall increase in visual acuity to 66% after treatment.

## DISCUSSION

We collected 47 patients in our study with a female predominance in 70.2% of cases. Headache was the most common warning sign followed by loss of visual acuity with 42.6% and 31.9% respectively. If the main mode of revelation is headache [3]; other studies [5, 6] report a decrease in visual acuity associated with a headache as a mode of revelation. Stasis papilledema was the most found type in 91.5% of our cases. It was almost the same in the study conducted by S. Malobe Seck *et al.*, [7] in Dakar which noted stasis papilledema in 92.30% of cases. In our study, intracranial

hypertension (ICH) was the main cause of bilateral papilledema with a rate of 74.5%. This result is higher than that found by S. Malobe Seck *et al.*, which is 62.5%. According to a study by R. Deschamps [8], 80% of bilateral papilledema (OPB) were related to ICH, which is the most frequent cause of OPB according to MB Rougier [9]. Intracranial hypertension can be either idiopathic or secondary, and it is the latter that must be sought in priority because of the severity of the prognosis of certain etiologies. Secondary ICH must be eliminated from the first imaging [3]. In European and American studies [3, 10] intracranial tumors and cerebral thrombophlebitis were the main causes of ICH. In our study, in addition to intracranial tumors and cerebral thrombophlebitis with 77.8% (7 cases/9) were the main causes of secondary HIC; we also noted two cases of meningitis (22.2%). Idiopathic ICH is the most common cause of acute stasis OPB according to MB. Rougier *et al.*, [3]. R. Deschamps *et al* [8] also found this frequency in 60% of their patients. In our study, the modified Dandy criteria found 74.3% of idiopathic ICH, essentially 88.5% of overweight women. The profile of these idiopathic HICs for R. Deschamps *et al.*, [8] is that of young obese women (96.7% of women. Our study found a superimposable profile (88.5% of overweight women). Obesity occurs through an increase in intra-abdominal pressure which increases venous pressure [11]. Increased intracranial venous pressure is the currently accepted hypothesis in the pathophysiology of idiopathic ICH [11]. Although the association with obesity is very frequent, other risk factors can promote idiopathic ICH [12, 13]. Thus in our study we find other risk factors such as taking oral contraceptives (oestrogen-progestins) in 21.7% and alcohol intake in 11.5%. The use of estrogen-progestins and alcoholism were also reported in other studies [10,

13] as factors favoring ICH. HIC is not the only etiology of OPB, we noted in our study others such as malignant hypertension, papillitis and head trauma and anemia.

## CONCLUSION

Bilateral stasis papilledema due to idiopathic intracranial hypertension is the most common cause of papilledema in young people. The field is that of a young woman and its occurrence is favored by obesity, or the taking of estrogen-progestogens. In cases of stasis OPB by secondary HIC, tumor causes are in the first line.

## REFERENCES

1. Elouarradi, H., & Daoudi, R. (2014). Œdème papillaire de stase bilatéral révélant une hypertension intracrânienne bénigne. *The Pan African Medical Journal*, 18, 96.
2. Tournaire-Marques, É., Rougier, M. B., Delyfer, M. N., & Korobelnik, J. F. (2012). Œdèmes papillaires unilatéraux: étude rétrospective observationnelle de 52 patients. *Journal français d'ophtalmologie*, 35(9), 678-683.
3. Rougier, M. B. (2010). Œdème papillaire bilatéral. Conduite diagnostique. *Journal français d'ophtalmologie*, 33(6), 424-429.
4. Friedman, D. I., Liu, G. T., & Digre, K. B. (2013). Revised diagnostic criteria for the pseudotumor cerebri syndrome in adults and children. *Neurology*, 81(13), 1159-1165.
5. Bielefeld, P., Legendre, M., Devilliers, H., Turcu, A., Muller, G., Vernier, N., ... & Besancenot, J. F. (2016). Œdème papillaire bilatéral secondaire à une hypertension intracrânienne dite idiopathique, ne pas oublier la sténose du sinus transverse. *La Revue de Médecine Interne*, 37, A164.
6. Marks, C., Vieville, C., Cantineau, D., Steiner, B., Rouland, J. F., & Labalette, P. (2008). Hypertension intracrânienne bénigne: étude rétrospective de 15 cas. *Journal Français d'Ophtalmologie*, 31(Supplement 1), 207.
7. Said, M. S., Babacar, W., Magatte, D., Fatou, D., Oulfath, A., Doumbe, N. M., Diaye, N. S., & Ndeye, N. G. (2021). Profil étiologique des œdèmes papillaires bilatéraux chez le noir africain; Communication orale Congrès SFO.
8. Deschamps, R., Dehais, C., Heran, F., Obadia, M., Laloum, L., Fechner, C., ... & Gout, O. (2008). Œdèmes papillaires bilatéraux: étude prospective de 50 patients. *Revue Neurologique*, 164(1), 42-46.
9. Rougier, M. B. (2017). Œdème papillaire bilatéral. *J Fr Ophtalmol*, 40, 422-429.
10. Wall, M. (2010). Idiopathic intracranial hypertension. *Neurol Clin*, 28, 593-617.
11. Makri, S., Abdellaoui, W., Oulbani, D., Salhi, S., & Boustil, K. (2009). Hypertension intracrânienne idiopathique avec selle turcique vide : A propos de deux observations, *Revue maghrébine de Neurosciences*, 4.
12. Ko, M. W., & Liu, G. T. (2010). Pediatric idiopathic intracranial hypertension (pseudotumor cerebri). *Hormone research in paediatrics*, 74(6), 381-389.
13. Biousse, V. (2012). Idiopathic intracranial hypertension: diagnosis, monitoring and treatment. *Revue neurologique*, 168(10), 673-683.