

Blindness by Mega Foreign Bodies During Work Accidents: about 2 Cases at CHU IOTA Bamako

Gounon Saye¹, Brainima Coulibaly^{1*}, Oumar Diallo², Modibo Sissoko¹, Mory Coulialy¹, Sogodogo Cheik¹, Aissatou Simaga¹, Nouhoum Guirou¹

¹University Hospital Center-IOTA, Bamako, Mali

²Ophthalmology Department, "Luxembourg" University Hospital Center in Bamako, Mali

DOI: [10.36347/sjmcr.2023.v11i06.063](https://doi.org/10.36347/sjmcr.2023.v11i06.063)

| Received: 24.05.2023 | Accepted: 20.06.2023 | Published: 24.06.2023

*Corresponding author: Brainima Coulibaly
University Hospital Center-IOTA, Bamako, Mali

Abstract

Case Report

Trauma is a frequent reason for consultation in ophthalmological emergencies. The intraocular foreign body (IEB) is the dreaded situation, which can go as far as the functional and even anatomical loss of the eye. The occurrence of ocular trauma as a result of a work accident is severe, often leads to temporary and sometimes permanent incapacity for work. We have reported two cases of foreign bodies; the first case, a 35-year-old woman consulted in our service for eye trauma by fish stoppage occurring as a result of housework; The second case, a 25-year-old young man consulted in emergency 4 days after an eye trauma by falling wood on his head in a traditional gold panning site. The intervention consisted in the extraction of the various foreign bodies.

Keywords: Trauma, foreign bodies, work accident, arrest, gold panning.

Copyright © 2023 The Author(s): This is an open-access article distributed under the terms of the Creative Commons Attribution 4.0 International License (CC BY-NC 4.0) which permits unrestricted use, distribution, and reproduction in any medium for non-commercial use provided the original author and source are credited.

INTRODUCTION

Eye injuries occurring in the workplace occupy an important place in ophthalmological emergencies [1, 2]. They hold a large share in morbidity and disability, coinciding with young age when professional activity is important. They therefore cause harm and functional, socio-professional and medico-legal repercussions.

Some traumas are minor and remain of good prognosis, others engage the anatomical and/or functional prognosis of the eye thus constituting real therapeutic emergencies, after the elimination of an associated vital emergency (cranial trauma).

The nature and circumstances of the accident should be determined by careful questioning. A rigorous ophthalmological examination is important to establish a complete lesional assessment.

The limited therapeutic management and the prognosis remains bleak in the face of serious ocular trauma, underlines the importance of prevention, which remains the only guarantee for combating this socio-economic scourge.

Through this work, we want to highlight the seriousness of eye injuries with CEIOs in the workplace and draw attention to the need for prevention.

Comments:

1st Case

A 35-year-old lady referred by her parents for a right ocular trauma by stopping fish that occurred one hour before admission following housework, while wanting to cut the wings of fish with a knife.

She has no history except that she is the mother of 04 children.

Visual acuity from afar was limited to light perception, the presence of an intra ocular fish stop foreign body measuring approximately 9cm (Fig 1) passing through the center of the cornea, affecting all the structures of the eyeball, obliteration of the anterior chamber, hernia of the iris and vitreous.

Treatment consisted of vaccination and anti-tetanus serum. In the operating room, after peribulbar anesthesia of the traumatized eye, we proceeded to the extraction of the foreign body of a bony nature (fish stop) (Fig 2) 10cm long of which 5mm was intraocular, suture of the corneal wound with 10/0 monofilament thread in 5 separate points.

Citation: Gounon Saye, Brainima Coulibaly, Oumar Diallo, Modibo Sissoko, Mory Coulialy, Sogodogo Cheik, Aissatou Simaga, Nouhoum Guirou. Blindness by Mega Foreign Bodies During Work Accidents: about 2 Cases at CHU IOTA Bamako. Sch J Med Case Rep, 2023 Jun 11(6): 1287-1290.

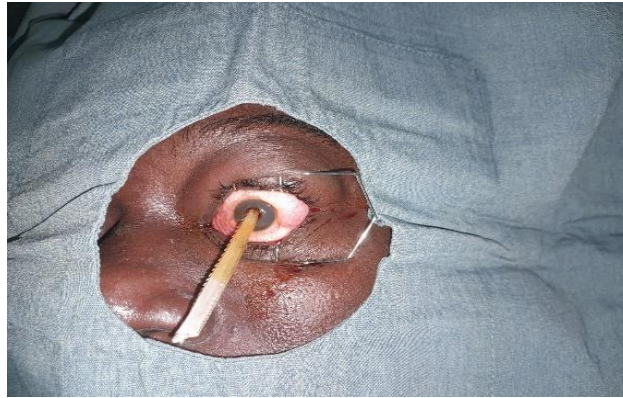

Figure 1: Foreign body by fish stop in a 35-year-old woman

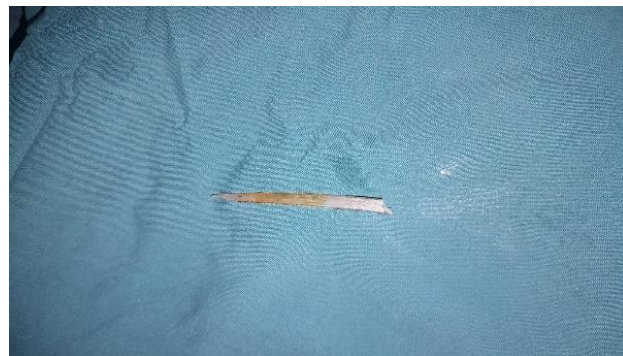

Figure 2: 10cm foreign body

2nd Case

A 26-year-old man working in a traditional gold panning site with no particular medical and surgical history, referred by a Reference Health Center for left eye trauma following a wood fall on his head, received 4 days after the trauma.

Visual acuity in the traumatized eye was limited to no light perception and 10/10 in the adept eye; there was a large full-thickness wound extending from the brow bone to the upper eyelid with the presence of a foreign body of vegetable nature (Fig 3) and significant edema of the upper eyelid.

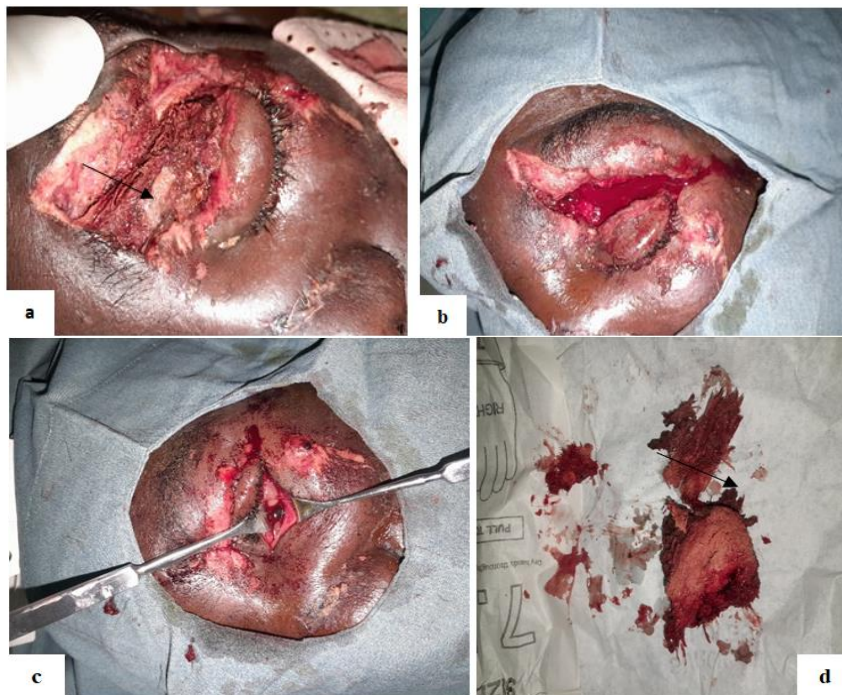


Figure 3: Palpebro-frontal vegetal foreign body in a 26-year-old man

A penetrating eyelid wound with a plant-like frontal palpebral foreign body, significant edema of the upper eyelid plus chemosis in 3600 making it difficult to access the eyeball in a context of ocular trauma by work accident

The orbito-cerebral CT performed in emergency, objectified at the orbital level, a fracture of

the left frontal bone radiating towards the anterior wall of the frontal sinus with hemosinus, a fracture of the internal wall of the orbit with homolateral pneumo orbit, probable aspect of the left eyeball in the left maxillary sinus, filling of the left orbital cavity with hyperdense wharf material and air bubbles related to a foreign body, elsewhere the eyeball and oculomotor muscles are normal in addition to the cerebral stage (Fig 4).

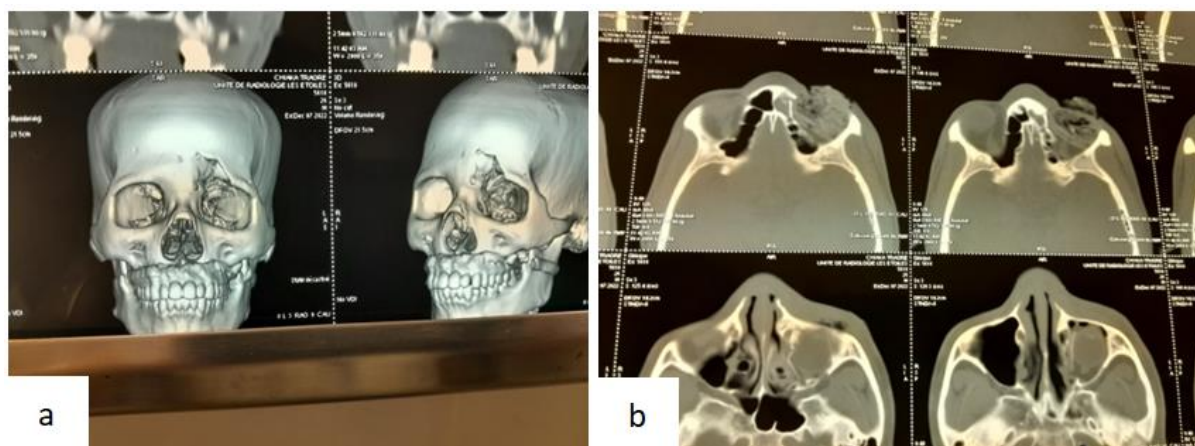


Figure 4: Orbito-cerebral CT scan of a 26-year-old subject

Treatment consisted of tetanus prevention (SAT, VAT), strong antibiotic therapy, extraction of the foreign body measuring 11 cm long and 6 cm wide; suture the wound in two planes with 5/0 vicryl under loco-regional anesthesia. In a second step, a multidisciplinary care grouping together: maxillofacial, ENT, neuro-surgeon and oculoplastician was requested.

DISCUSSIONS

The presence of a CEIO is manifested by extremely variable pictures depending on the CE itself (size, nature, site and speed of penetration, path and heat of the CE) and ocular lesions associated with the trauma. Schematically, we encounter two major situations: that of the penetrating wound with CEIO, accompanied by an inflammatory reaction and a major infectious risk, and that at a distance from an unrecognized CEIO manifesting itself by inflammatory, infectious, or toxic phenomena. depending on the nature of the EC [3].

The diagnosis and treatment of aCE intra-orbital vegetative are often difficult because the patient's history is sometimes misleading [5, 6]. Plant ECs have a high infectious potential of by their porous constitution which provides a good culture medium for bacterial agents [6, 7] and by the diagnostic delay because they are often very difficult to detect by imaging [8, 9].

The bodyIntraorbital foreign material can be associated with serious lesions of the orbital walls, the

eyeball, the optic nerve, the cavernous sinus and sometimes endocranial lesions [4].

Imaging has a major diagnostic role. Thereorbital computed tomography (CT) remains an excellent means, it must include coronal and horizontal incidences without omitting to explore the cranial cavity. It nevertheless has its limits for the detection of certain wooden foreign bodies which can be easily confused with the air in the orbit [10, 11].

The particularity of these two clinical cases was, the circumstances, the natures, the sizes and especially the intraocular and orbital palpebral location, requiring urgent care within a reasonable time to limit the complications of an infectious nature that can cause the visual prognosis and more serious the vital prognosis.

BIBLIOGRAPHY

1. Ngondi, C. E., Chastonay, P., & Dosso, A. (2010). Prévention des traumatismes oculaires professionnels (Genève, Suisse). *Journal Français d'Ophthalmologie*, 33(1), 44-49.
2. Zghal-Mokni. (2007). Epidemiology of occupational eye injuries. *Tunis Med*, 85(7).
3. Ducasse, A. (2001). Intraorbital foreign bodies. *J Fr Ophthalmol*, 24, 758-764.
4. Karim, A., Taha, I., & Tachfouti, S. (2006). Foreign bodyintra-orbital plant: about a case. *French Journal of Ophthalmology*, 29(10).
5. Jabaly-Habib, H. Y., Muallem, M. S., & Garzozi, H. T. (2002). Yearintraorbital injury from an occult

- wooden foreign body. *J pediatr ophthalmol strabismus*, 39, 300.
6. Cartwright, M. J., Kurumety, U. R., & Frueh, B. R. (1995). Intraorbital wood foreign body. *Ophthalmic Plastic & Reconstructive Surgery*, 11(1), 44-48.
 7. Mutlukan, E., Fleck, B. W., Cullen, J. F., & Whittle, I. R. (1991). Case of penetrating orbitocranial injury caused by wood. *British journal of ophthalmology*, 75(6), 374-376.
 8. D'hermies, F., Halhal, M., Morel, X., Meyer, A., & Renard, G. (2001). Corps étranger végétal intra-orbitaire. *Journal français d'ophtalmologie*, 24(5), 517-521.
 9. Weinacht, E., Zaunbauer, W., & Gottlob. (1998). Opticalatrophy induced by intra orbital wooden foreign body (1998): the role of CT and MRI. *J Pediat ophthalmol strabismus*, 35, 179-181.
 10. Roberts, C. F., & Leehey 3rd, P. J. (1992). Intraorbital wood foreign body mimicking air at CT. *Radiology*, 185(2), 507-508.
 11. Specht, C. S., Varga, J. H., Jalali, M. M., & Edelstein, J. P. (1992). Orbitocranial wooden foreign body diagnosed by magnetic resonance imaging. Dry wood can be isodense with air and orbital fat by computed tomography. *Survey of Ophthalmology*, 36(5), 341-344.