

Correlation of Umbilical Artery Doppler with placental Histomorphology in FGRManoj Kr. Mazumdar¹, Gokul Chandra Das², Shireen Mumtaz Barbhuiya^{3*}, Manjulachoudhury⁴¹Assistant Professor, Department of Obstetrics and Gynecology, Gauhati Medical College and Hospital, Assam, India²Postgraduate Trainee, Department of Obstetrics and Gynecology, Gauhati Medical College and Hospital, Assam, India³Professor, Department of Obstetrics and Gynecology, Gauhati Medical College and Hospital, Assam, India⁴Professor, Department of Pathology, Gauhati Medical College and Hospital, Assam, India**Original Research Article*****Corresponding author**

Shireen Mumtaz Barbhuiya

Article History

Received: 12.11.2017

Accepted: 18.11.2017

Published: 30.11.2017

DOI:

10.36347/sjams.2017.v05i12.002



Abstract: Doppler velocimetry (DV) is widely used to assess the vascular formation of the placenta in fetal growth restriction (FGR) and to estimate the haemodynamic condition of the growth-restricted fetus. Umbilical artery (UA) flow is essentially placental, rather than fetal. Hence, DV provides information about the fetal side of the placenta and, alongside placental histopathology; it could possibly help to decipher aetiopathogenesis in FGR cases. Objectives: To correlate UA DV findings occurring in FGR with placental findings. Methods- A total of 100 singleton FGR pregnancies (>28weeks) were included in the study. The placental lesions and neonatal outcomes were correlated with DV findings. We had 30 cases with normal UA Doppler velocimetry, 30 cases with low end diastolic flow (Increased S/D ratio or PI) and 40 cases of absent or reversed diastolic flow. Results- FGR pregnancies with AREDV had significantly lower mean birth weight i.e 1.14kg as compared with 1.59kg and 1.98kg in FGR with increased S/D or PI and normal UA Doppler velocimetry respectively. (P < 0.001).The placentas in AREDV weighed less, and had higher number of ischemic lesions. Among the lesions featuring under perfusion of placenta, 5 lesions i.e placental infarct(P<0.003), increased syncytial knots(p < 0.001) cytotrophoblastic proliferation, calcification and per villous fibrin deposition(p < 0.001) are present which are significantly higher in the abnormal Doppler group as compared with normal UA Doppler. Conclusion- There was a significantly higher number of maternal placental malperfusion lesions and poor perinatal outcome in SGA patients with abnormal UA Doppler velocimetry.

Keywords: FGR, Umbilical artery Doppler, absent or reversed diastolic umbilical artery flow, placental insufficiency in FGR, placental histomorphology.

INTRODUCTION

Intrauterine growth retardation is one of the main challenges in maternal care. It is a condition where the rate of growth of a fetus is less than normal for the growth potential of a fetus (for that particular gestational age) [1]. The most common cause of FGR is placental insufficiency followed by maternal conditions not associated with placental insufficiency, fetal chromosomal abnormalities, multifactorial fetal abnormalities and fetal infection [2]. Doppler flow studies are an important adjunct to fetal biometry in predicting the perinatal outcome. Society for maternal-Fetal Medicine guidelines (2012) on Doppler assessment of the growth-Restricted fetus recommends the use of Umbilical Doppler for the management of FGR as there is a good evidence to show that it decreases the risk of labour induction, caesarian section, and perinatal death [3].

Primary villus maldevelopment with evidence of reduced placental villus stem arteries and small, fibrotic, hypovascular terminal villi, have been shown in various pathological studies of the placenta of pregnancies complicated by fetal growth restriction (FGR) [4-7]. Clinically, many abnormal umbilical artery (UA) waveforms are associated with these pathological findings such as increased Doppler resistance, reduced flow, absent UA end diastolic flow (AEDF) or reversal of UA end diastolic flow (REDF) flow. We thought it worthwhile to carry out a study of UA Doppler velocimetry in FGR fetus and also, on the histopathology of placenta, so that it might give an insight into the etiopathogenesis of FGR.

MATERIALS AND METHODOLOGY

The study was conducted in the department of Obstetrics and gynecology department of GMCH in the year 2016 to 2017. Prior ethical committee clearance

and consent for the study was taken for the study. The inclusion criteria for the study was a singleton pregnancy at >28 weeks of gestation suspected of having FGR (sonographically estimated fetal weight <10th percentile for the gestational age). All these cases were confirmed postnatally as small for gestational age

(SGA) SGA was defined as actual birth weight <10th percentile for that gestational age. Pregnancies with an anomalous fetus or multiple pregnancies were excluded. A thorough history, general and systemic examination of patient was done. A standard protocol was followed to determine UA Doppler indices for all patients. Ultrasound was performed using a convex transducer at a frequency 3.5-5 MHz. The free-floating loop of the umbilical cord was selected for investigation. The angle of insonation was always kept lower than 30°. The S/D ratio and pulsatility index (PI) of the UA was determined and any absence or REDF in the UA was also recorded. After delivery of the FGR fetus, the placenta obtained was sent immediately in 10 % formalin to the lab for gross and histopathological examination by pathologist. Sections are taken from cord, membranes and parenchyma. Sections from membranes include the rupture site. These are rolled

and processed further. The sections from parenchyma include all relevant pathological areas and atleast one “normal” area. These are full thickness sections including the chorionic plate. The sections are further fixed overnight in 10% formalin and processed. Routine Hematoxylin and Eosin stains are employed for all sections. The following parameters are noted:

Placental weight and thickness, umbilical cord insertion and number of vessels, placental infarcts, and increased syncytial knots, perivillous fibrin deposition, villitis, villous thrombosis and retroplacental haematoma. The results obtained were analysed to study the correlation between placental findings and Doppler velocimetry. P < 0.05 was taken as critical level of significance.

RESULTS AND DISCUSSIONS

Of the total 100 FGR cases, on UA Doppler it is seen that 30% of cases had increased S/D ratio, 40% had AREDV and 30% of cases had normal UA Doppler. We have classified into 3 groups that is, Group I (Normal UA Doppler), Group II (Increased S/D ratio), Group III (AREDV)

Table-1: Comparison of demographic data among 3 different Doppler study groups

	Group I	Group II	Group III
Maternal age			
>34years	30%	63%	70%
Primigravida	33%	66%	75%
Pre-eclampsia	33%	66%	75%
Oligohydramnios	30%	63%	85%
Route of delivery	Vaginal	80%	66%
	CS	20%	34%
NICU Admission	23%	73%	100%

We have seen that majority of the patients with abnormal UA Doppler are primigravida with pre-eclampsia, similar to the studies of Jang DG *et al.* [8], Malikarjunappa *et al.* [9] and Varsdorp KH *et al.* [10].

Advanced maternal age (≥ 35years). advanced maternal age is an independent risk factor for FGR. This is in accordance with the study of Odibo AO *et al.* [11]. Advanced maternal age is associated with a decreased potential for fetal growth [12], possibly reflecting the biological aging of maternal tissues and system or the cumulative effect of diseases like pre-eclampsia. In our study we have seen that 70% of the cases with AREDV had age more than 34years.

70% of FGR with abnormal UA Doppler is associated with oligohydramnios. The studies of Deshmukh *et al.* [13] and K Gandhi *et al.* [14] had similar views on this. Highest incidence of

oligohydramnios is seen in cases with AREDV in our study.

Most of the babies with abnormal Doppler cannot withstand the stress and showed ominous sign during labour. 100% of the cases with AREDV ended up in CS due to fetal distress. The mean birth weight of the babies lowered with the worsening of UA Doppler. The average birth weight of the babies with normal Doppler is 1.98±0.205kg, average birth weight of the babies with increased S/D 1.57 ± 0.161kg and that of absent or reversed diastolic flow is 1.14±0.129kg. Feto placental ratio was apparently similar in all groups.

The babies with AREDV had poor Apgar score i.e 80% of FGR with absent or reversed diastolic flow have apgar score less than 7. 90% of the cases with increased AREDV were admitted in NICU in contrast with 23% of FGR with Normal UA Doppler. Siddiqui TS *et al.* [15], Deshmukh *et al.* [13] and Y Seyam *et al.* [16] had similar results with respect to poor perinatal morbidity of FGR fetus with abnormal UA Doppler.

Table-2: Comparison of placental pathologic features among 3 different Doppler study groups

	Group I	Group II	Group III	P value
Eccentricity of Umbilical cord	10	20	30	<0.01
Fetoplacental weight ratio	5.88	5.5	5.23	>0.8
Placental infarct	10	20	28	<0.01
Increased syncytial knots	4	9	32	<0.03
Perivillous fibrin deposition	1	4	12	<0.001
Cytotrophoblastic proliferation	2	7	20	<0.001
Calcification	11	23	25	<0.001
Villitis	0	0	2	0.81
Villous thrombosis	4	1	6	0.27
Retroplacentalhaematoma	4	0	4	0.31

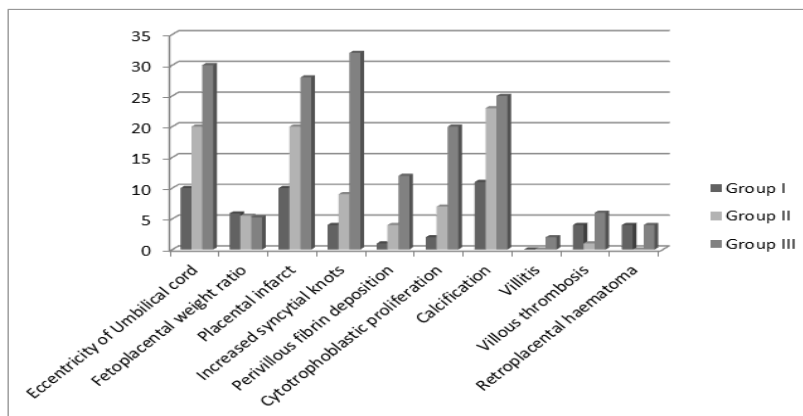


Fig-1: Comparison of placental pathologic features among 3 different Doppler study groups

We have seen that out of the 8 microscopic lesions in placenta, which are considered in the study, 5 lesions are seen more in FGR with abnormal Doppler’s infarct, increased syncytial knots, per villous fibrin deposition, cytotrophoblastic proliferation and calcification are more common.

In the FGR cases with abnormal UA Doppler, we have come across placental infarct (11 vs 48, p value <0.01), increased syncytial knots (4 vs 41, p value <0.03), perivillous fibrin deposition (1 vs 16, p value <0.001), cytotrophoblastic proliferation (2 vs 28, p < 0.001), and calcification (11 vs 48, p <0.001). However no statistically significant differences in cases of villitis, villous thrombosis and retroplacentalhaematoma. The findings of Jang DG *et al.* [8], Margaret *et al.*[17] and Thanapob *et al.*[18] are similar to the results of our study. The views of Madazli *et al.* [19] are also consistent with our findings to some extent. Madazli *et al.* [19] 2003, found FGR cases with abnormal umbilical artery Doppler velocimetry’s had a significantly increased number of villous infarcts, cytotrophoblast proliferation and thickening of the villous trophoblastic basal membrane (P=0.001, P=0.038 and P=0.02 respectively).

The clustering of specific placental lesions into the abnormal Doppler group raised the support for

maternal under perfusion features as the main aetiology for fetal growth restriction.

CONCLUSION

One of our principal aims in antenatal care is to identify the fetus that is at risks of hypoxic complications in the perinatal period. Placentas of FGR newborns with abnormal Doppler are smaller with more gross and histopathological findings than that of FGR with normal Doppler. Significant pathological findings are marginal cord insertion, infarction, increased syncytial knots and per villous fibrin deposition. These findings are more prominent in placenta with absent or reverse diastolic flow. The pathological findings are mostly due to chronic placental insufficiency. These suggest that as the placental insufficiency worsens the diastolic flow decreases, then becomes absent and then later reverses. Thus, the umbilical artery Doppler waveforms can identify the degree of pathological changes which occurred in placenta.

There were a higher number of maternal under perfusion placental histopathological lesions in FGR patients with abnormal Doppler findings supporting a maternal aetiology for FGR. This study therefore indicates that UA Doppler study should be done routinely as a surveillance of FGR to optimize the perinatal outcome.

REFERENCES

1. Saleem T, Sajjad N, Fatima S, Habib N, Ali SR, Qadir M. Intrauterine growth retardation--small events, big consequences. *Ital J Pediatr.* 2011;37:41.
2. Fernando Arias, Daftary SN. A Practical guide to Highrisk Pregnancy and Delivery. A southasian Perspective . 2013;3:4:106-108.
3. Berkley E, Chauhan SP, Abuhamad A. Doppler assessment of the fetus with intrauterine growth restriction. *Am J Obs Gynecol.* 2012;206(4):300-308.
4. Todros T, Sciarrone A, Piccoli E, Guiot C, Kaufmann P, Kingdom J. Umbilical Doppler waveforms and placental villous angiogenesis in pregnancies complicated by fetal growth restriction. *Obstet Gynecol.* 1999;93(4):499-503.
5. Kreczy A, Fusi L, Wigglesworth JS. Correlation between umbilical arterial flow and placental morphology. *Int J Gynecol Pathol.* 1995;14(4):306-309.
6. Kingdom J, Huppertz B, Seaward G, Kaufmann P. Development of the placental villous tree and its consequences for fetal growth. *Eur J Obstet Gynecol Reprod Biol.* 2000;92(1):35-43.
7. Biagiotti R, Sgambati E, Brizzi E. Placental morphometry in pregnancies complicated by intrauterine growth retardation with absent or reversed end diastolic flow in the umbilical artery. *Ital J Anat Embryol.* 1999;104(4):201-207.
8. Jang DG, Jo YS, Lee SJ, Kim N, Lee GSR. Perinatal outcomes and maternal clinical characteristics in FGR with absent or reversed end-diastolic flow velocity in the umbilical artery. *Arch Gynecol Obstet.* 2011;284(1):73-78.
9. Mallikarjunappa B, Harish H, Ashish SR, Pukale RS. Doppler changes in pre-eclampsia. *J Int Med Sci Acad.* 2013;26(4):215-216.
10. Karsdorp VHM, Dirks BK, Van Der Linden JC, Van Vugt JMG, Baak JPA, Van Geijn HP. Placenta morphology and absent or reversed end diastolic flow velocities in the umbilical artery: A clinical and morphometrical study. *Placenta.* 1996;17(7):393-399.
11. Odibo AO, Nelson D, Stamilio DM, Sehdev HM, Macones GA. Advanced maternal age is an independent risk factor for intrauterine growth restriction. *Am J Perinatol.* 2006;23(5):325-328.
12. Lee K sun, Ferguson RM, Corpuz M, Gartner LM. Maternal age and incidence of low birth weight at term: A population study. *Am J Obstet Gynecol.* 1988;158(1):84-89.
13. Deshmukh A, Soni N, Gokhale S. Significance of umbilical artery Doppler velocimetry in the perinatal outcome of the growth restricted fetuses. *J Obstet Gynecol India.* 2010;60(1):38-43.
14. Gandhi K, Vishal Mehta A, year resident rd, Professor A. Role of Doppler Velocimetry in growth restricted fetuses. <http://www.nhlmmc.edu.in/document/nhljms> Volume.4 Issue.1/27-30.pdf. Accessed September 12, 2017.
15. Siddiqui TS, Asim A, Ali S, Siddiqui TS, Tariq A. Comparison of perinatal outcome in growth restricted fetuses retaining normal umbilical artery Doppler flow to those with diminished end-diastolic flow. *J Ayub Med Coll Abbottabad.* 2014;26(2):221-224.
16. Seyam YS, Al-Mahmeid MS, Al-Tamimi HK. Umbilical artery Doppler flow velocimetry in intrauterine growth restriction and its relation to perinatal outcome. *Int J Gynaecol Obstet.* 2002;77:131-137.
17. Nordenvall M, Ullberg U, Laurin J, Lingman G, Sandstedt B, Ulmsten U. Placental morphology in relation to umbilical artery blood velocity waveforms. *Eur J Obstet Gynecol Reprod Biol.* 1991;40(3):179-190.
18. Thanapob Bumphenkiatikul MD, Trongpisutsak A, Tantbiroj P, Uerpairojkit B. Placental Pathology in Small-for-Gestational-Age Fetuses with Different Doppler Studies. *Thai J Obstet Gynaecol.* 2017;25(1):18-25.
19. Madazli R, Somunkiran A, Calay Z, Ilvan S, Aksu MF. Histomorphology of the placenta and the placental bed of growth restricted foetuses and correlation with the Doppler velocimetries of the urine and umbilical arteries. *Placenta.* 2003;24(5):510-516.