

Beauty, Where Nobody May See It: Female Intimate Jewellery

Erich Kasten*

Medical School Hamburg, Am Kaiserkai 1, D-20457 Hamburg, Germany

Review Article

*Corresponding author

Erich Kasten

Article History

Received: 22.12.2017

Accepted: 25.12.2017

Published: 30.12.2017

DOI:

10.36347/sjams.2017.v05i12.058



Abstract: Sexuality is one of the general motives of human behavior and people try to achieve a better appearance, with the genetically-deterministic goal, to catch the attention of the currently desired partner. Strangely enough, the desire to increase the attractiveness applies today even on body areas which hardly anyone sees. The article gives an overview about genital modifications in women as e.g.: shaving of pubic hair, intimate piercings and play piercings, flesh tunnel in the labia majora, genital tattoos, surgical changes in the genital area, shortening and enlargement of labia, designer vaginas and vaginal rejuvenation. Typical times of healing of genital body modifications, side effects and complications are reported. Main motives to bear the pain of getting such an intimate jewelry are increasing of attractiveness, erotic reasons. Another, at first glance rather astonishing reason from the spectrum of possible motivations is a kind of self-therapy. Many carrier hope to cope better with own problems, as e.g. lack of confidence, shyness, anxiety, depression or negative memories, e.g. in abused women.

Keywords: Sexual attractiveness, body modification, genital piercing, tattoo, implants, intimate jewellery, sexual abuse.

INTRODUCTION

More than hundred years ago Sigmund Freud recognized the Libido (sex energy) as one of the principal motives of behavior. Ultimately, with a variety of activities ranging from haircuts and beauty, about sports, body-building or diets to tattoos and piercings, humans try to achieve a better appearance, with the genetically-deterministic goal, to catch the attention of the currently desired partner.

Strangely enough, the desire to increase the attractiveness applies today even on body areas which hardly anyone sees. The desire for intimate embellishment can be so strong that the original biological motive is completely set aside; in some extreme forms of genital piercings a normal sexual intercourse is no longer feasible.

The idea of an increase of genital attractiveness is not new. Aglaja Stirn, one of the most famous international scientists in this area, published in 2008 an essay, in which she wrote that genital embellishments are widespread among native peoples, e.g. sheaths for the male penis were phallic or fertility symbols for centuries in tropical Africa, South America, and Melanesia [26]. Nowadays, the ways to make the female genital area more attractive includes, for example, shaving, piercings, tattoos, and surgical procedures such as shortening of the inner labia, "designer vagina" or "vaginal rejuvenation". Within the field of sadomasochistic methods occur temporary and usually under pain inserted body jewelry such as the so-called "play piercings". Moreover, there are some strange techniques such as the sewing up of the vagina

or injections of saline to increase the size of the labia. While on the one hand the piercing trend elsewhere in the body had had its peak around the turn of the millennium and abates in recent years steadily, on the other hand a study of van der Meer *et al.* [34] in the Netherlands found a continuously increasing demand for intimate jewelry.

Shaving

Hair removal in the pubic area is an ancient fashion, about which exists surprisingly little scientific research. In addition to shaving, depilation, wax-removal of hairs and chemical methods, a long-term removal by destroying the hair roots with a laser is state of the technique. Borkenhagen and Brähler [6] quoted several studies in which 60% of American women are "bikini shaved" and 30% totally shaved in their genital area. Disproportionately, these are, however, young women: In the age group of young women (20-30 years) 84% remove their pubic hair, compared to only 55% of women between 40-50 years.

Today, intimate shaving seems not only to appear in women. Borkenhagen and Brähler [6] also cited surveys that a quarter of German men don't like

hairs in their trunks. Kuehne [16] found in 2008 that 87.7% of women performed a genital shaving, but also 67.4% of male students used a razor in the region of their underpants. However, all participants in this study were about 20 years old and mostly students. In 2009, in a more representative larger population sample, Brähler could not replicate these high frequencies. As a result of this study, only about half of women aged 18 to 25 years confessed intimate shaving, the proportion among men was slightly lower {1}. More than 60% of participants gave hygienic reasons for the shaving; about 70% of women just liked their naked pubic area better. Around a quarter of men admitted openly, they found hairless sex more stimulating. In an interview Brähler said: *"The results of our studies shows a formation of new beauty standards particularly among women due to hairless aesthetics in the genital area. The female genital is increasingly more visible and no longer subject of privacy. Nowadays, many women see their genital with others eyes. Not only breasts or buttocks, but also the pubic region is now subject for an imperative of design."*{2}

Intimate piercings

Piercings and tattoos have already made their way into the private parts. Such Body Modifications, i.e. body jewelry due to painful procedures, are by far not a modern invention, even not for parts below the waistline. Innumerable older photos from the 30s and 40s years of the last century show for example a wealth of jewelry on the penis. Particularly gay men had drawn small silver chains through their foreskin [13, 14, 21, 26]. Today we have a multiplicity of names for piercings in the genital area, so one can have the impression that there are more species here than on the entire remnant of the body. In men these are called, depending on the position, with sound-full names as Apadravya, Ampallang, Dydoe, Frenum, Guiche, Hafada or Prince Albert. Often, for example, piercings were stung through the glans of the penis. Women also designate their genital jewelry with lovely names like "Christina" or "Lady Diana". According to data from Kuehne [16] at least 0.5% of the 20-year-old students have a piercing in the genital area, women were overrepresented. 2.1% of men and 1.0% of women had a nipple piercing. Stirn (26) gave results of other studies, in which the proportion of genital piercings was

around 2% of the respondents; about half of those were women. The average age for the acquisition of such a jewel in the genital area was about 24 years; about 3% of younger women between 20 and 29 years of age wished a genital piercing.

Owner of genital piercings hope usually not only for a genital beautification due to their jewelry, but also for an increase of erotic pleasure. In particular, men with piercing rings in the penile shaft or rods through their glans want to raise the intensity of feeling of their beloved woman. The trend goes towards very thick pieces of jewelry. Herman, a tattoo artist from "Paint it black" in Bargteheide, wrote that men easily are able to exercise sexual intercourse with 5 mm thick rings, but rings having a thickness of more than 8 to 10 mm in diameter reach a limit (of course depending on the wishes of the partner). Some women refuse to have intercourse with such a decorated man; others see it as an enrichment of eroticism. However, smaller rings in the foreskin or penile shaft can demolish during sex. This risk prevents some men not to develop an addictive-like behavior for piercings in the genital area. In the book "Piercing intim" of Feige & Krause [8] are photos of men wearing more than 20 metal rings in their genital. Here, normal sexual intercourse is no longer possible; body jewelry has become an end in itself.

Data published in 2004 by Brähler and co-authors [3] show that piercings are worn more often by women than by men, in the age group of 14-24-year-olds, for example, was the relationship 38% to 16%. Men prefer tattoos (20% men to 14% women in the youngest age group). These findings do not apply to the frequency of genital piercings; here women are more moderate than men. With body jewelry overloaded vaginas are found rarely, while in relevant websites one can see penises looking like a Christmas tree. However, women more often use the small metal rings definitely for sexual stimulation. Specifically balls in the clitoral hood and even rings through the clitoris itself arise sexual feelings even in everyday situations. Some women estimate their inner labia as ugly, especially if they are very long, and embellish them compensatory with such body jewelry. Countless examples of this can be found in the book by Feige and Krause [8] about genital piercing.

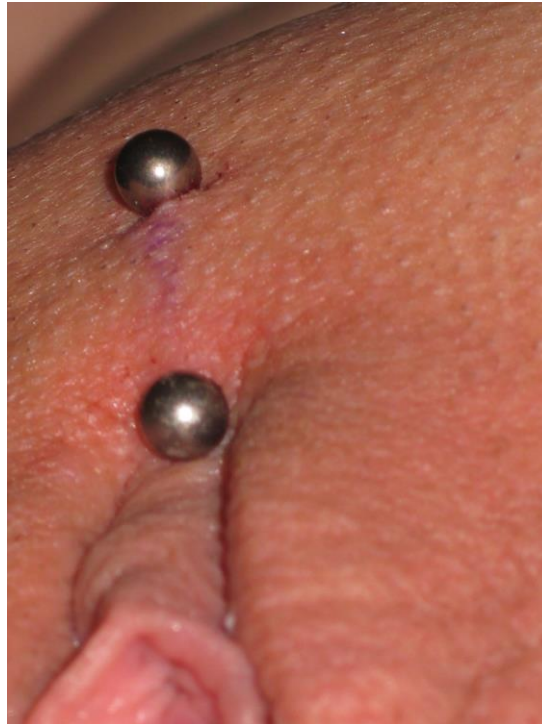


Fig-1: Female genital piercing called “Christina”

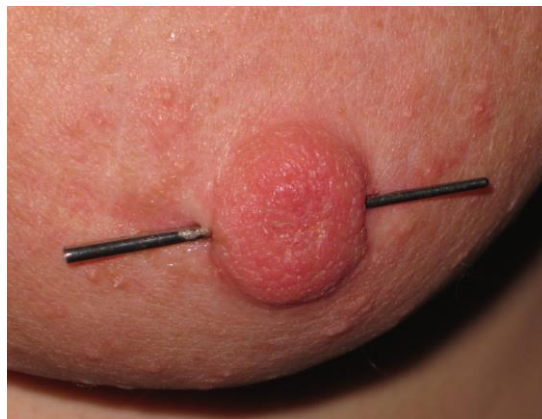


Fig-2: Nipple piercing

Play Piercings

For "play piercings" the metal parts are employed only temporarily. Used are syringe needles or normal piercing rings. Several dozens of these form pattern through the skin, for example, ring-shaped on the back [13, 14]. Often these were decorated with colorful ribbons. Play piercings are used to make unusual experiences or as a daring for adolescents. Comparatively often such painful gimmicks occur in the area of sadism/masochism where needles are engraved in the breasts, through the nipple or the penis, also through the glans. For example, in the internet one can find pictures with several parallel sets of rings through the labia majora, then crosswise a ribbon was pulled through these rings to close the vagina in a ornately-romantic way.

Flesh tunnels

Using conical pegs, piercing holes especially in the earlobe were already stretched in primitive cultures in ancient times. A stretching taper, which is secured with two rubbers against slipping, is the modern way to do this [13]. Also genital piercings are often stretched to deploy larger jewelry rings. From a certain size these are called "flesh tunnel". If women have relatively long inner labia, they can decorate them with large metal eyelets.

Intimate tattoos

Tattoos in the genital area are rare in both genders. Sometimes men have a tattooed penis. In women, tattoos usually are in the amount of the pubis; extremely rare, the labia majora are tattooed. The Internet contains pictures of female genitals with butterfly tattoos whose wings are drawn on the right and left labia majora. The Social Anthropology

promotes little historical precursors. About hundred years ago, Reitzenstein [24] reported about a culture on the Palau Islands in Pacific Micronesia, where, at the time of puberty, the genital area of girls was decorated with patterns by introducing black pigments into the skin with thorns. In adolescent woman the "telengékel" was tattooed, a narrow strip on both sides of the genital area up to the anus.

Semi-surgery

Due to the high risk of infections, among ancient primitive cultures semi-surgical interventions in the genital are very rare. Only the Aborigines in Australia are known to apply "Hypospadiasis", a technique in which the lower side of the penis was surgically opened up to the urethra [13]. In annually returned rituals, this hole was prolonged. The reasons are unclear; one suspects a kind of contraception, because not only urine, but during sexual intercourse also the semen emerges below the glans and does not reach the woman's vagina. Today this technique is found in rare cases of the extreme scene of Body Modification. Some men cut a finger-long artificial opening on the underside of their penis, which can then be used as an artificial vagina during homosexual intercourse. Other men split their glans and penile shaft. For this procedure often a hot electric cutter is used, so that the cut is nearly sterile. Gradually the penis then was splitted in two halves [13]. Mostly these rare modifications of the genitals are found in male homosexuals.

Since the turn of the millennium, piercings and tattoos are a modern trend under millions of people, and, following this trend, even the generation of over-fifties increasingly desired to get a tattoo. Therefore the avant-garde must develop new and more extreme techniques. The latest trend of this body cult is the implantation of objects under the skin, in the jargon of the BodMod scene called "implants" [13, 14]. Here, the skin is cutted surgically and so far detached from the subcutaneous tissue that one can slide the desired object into this hole. Then the usually very small incision is sutured. Popular are e.g. small horns on the forehead. Others have Titanium rods planted in the lower arm, result is an android-like appearance. Occasionally men wear implants in the genital area. E.g. "genital beads" are pearls or metal beads which are implanted underneath the foreskin to enhance sexual stimulation [13]. Other men wear implanted metal rods along the penile shaft. Pictures of women with such "implants" in the genital area can be found in the internet, but are extremely rare.

Another technique of body modification, but only of temporary nature, is the injection of saline in different body parts, „bagle heads“ for instance. In the genital area, the user injects this liquid with sterile syringes e.g. into the labia, scrotum, penis or in the

female breast. This leads to a bulging of this part of the body [13], increasing to double or triple thickness.

Shortening and enlargement of labia, designer vaginas and vaginal rejuvenation

According to an article of Borckenhagen and Brähler [6] shaving of pubic hair serves as "infantilization" i.e. the total shaved vagina resembles that of a child and is an attempt to conjure eternal youth. Little girls have hardly developed inner labia; they will grow in puberty to their full length. Therefore, small inner labia are seen as a sign of virginity and a surgical shortening of the inner labia has an increasing demand. Borckenhagen [5] pointed out that many women are ashamed due to the appearance of their genitals. In a century in which shaved vaginas and oral stimulation are an integral part of sexual intercourse, this can lead to fearful crises. In contrast, in African countries or on the islands in the South Pacific long labia are considered as signs of fertility. In several ancient African cultures this was seen as ideal of vaginal beauty and was supported artificially by constantly pulling and plucking of the labia since childhood. Reitzenstein presented in 1923 a discussion whether masturbation may have played a role in this behavior [24].

"Not only the face, legs, breasts, stomach and buttocks, today even the vagina must always look attractive, visually appealing and young", wrote Stirn in the book of Turkof *et al.* [32]. In the survey "International Vaginal Dialogue" in 9,441 women between 18 and 44 years from 13 countries 61% expressed concern about the appearance of their vagina and thereof 47% due to the size of their own labia [4]. The great majority of women undergo labiaplasty for purely aesthetic reasons, because they do not like the appearance of their external genitals. From a medical point of view, these operations are rarely necessary, but usually more a desire to improve the satisfaction with the own body.

In men, the trend clearly is to have an enlarged penis and a wealth of equipment promise help here [13]. Also, some women experience long labia as interesting and try to prolonge them, similar to the penis enlargement, usually by attaching weights. Clips hurt after a short time; therefore often piercing holes are used, due to the attached weights an extension of the tissue occurs.

There is no knowledge in the scientific literature, whether men like short or long labia minora (or whether ultimately it does not matter). But for an embellishment of their genital area, the majority of women in high-tech countries concentrate more on the shortening of their labia. Many women estimate long inner labia as ugly and can show considerable suffering [32]; as physical reasons for a surgical intervention often chafing while cycling or painful involving during

intercourse was reported. If the desire to shorten the labia has more psychological or actual medical reasons, is often difficult to decide.

In US-America already several clinics promise with large advertising campaigns a "vaginal rejuvenation"; here, the customer can select a designer vagina from a catalogue. Normally, in the process of aging disappear some parts of the fat tissue in the upper skin layers and the skin became wrinkled, this also applies to the genital area. Own fat cells from other parts of the body can be injected into the labia majora, these results in a blazing look. But since the fat is reabsorbed over time, the effect lasts only around half a year. Alternatively, commonly known from breast augmentation, silicone pads are used even for the vagina. According to Lloyd and co-authors „labia hypertrophica“ is a phenomenon, which has its origin only in an underdeveloped self-esteem [17]. Compared with the solution by scalpel, psychotherapy or an understandful partner would be preferable, especially since many men find large labia exciting and erotic [3].

Another area are surgical hymen corrections. Here, especially fathers from the Middle East try to restore the virginity of their stumbled daughters. In 2008 Borckenhagen named in one of her articles two further fields of application: Shortening of the foreskin of the clitoris to increase erotic stimulation during intercourse; and some surgeons even offer the injections of autologous fat in the so-called G-spot, thereby increasing sexual stimulation [5].

Side effects and complications

Usually, body jewelry makes relatively few problems with healing if the piercer understands his craft and most people can go to work the next day. Especially with genital jewelry the pain often is interpreted as erotic. But in unfavorable cases a piercing through the female labia can need several months until it is completely healed. During this time there has to be costly wound care, sometimes tight clothing cannot be worn and sexual intercourse is not possible. Depending on the body jewelry the time for a completed healing needs between four weeks up to half a year; if complications occur sometimes considerably longer [13].

In England Bone and colleagues [4] noted in a survey of over 10,000 people (age 16 y. and older) that approximately 10% of the total sample of all ages wore a piercing. Highest rates were found in young women, almost half of the 16-24 year olds was pierced; 31.0% reported of complications, 15.2% needed medical help and 0.9% had to be hospitalized.

In 2003 Stirn described a plethora of diseases that can occur as a result of piercing [28]. Probably for genital jewelry the frequencies for infections are increased because pathogens proliferate well in the warm, humid area of the genitals and the often several

centimeters long skin tube in which the small metal tube of the piercing is sitting, hardly can be cleaned totally. In 2001 Kaatz described a number of cases in which women had become sterile as consequence of infections of genital piercings [12]. Sexual intercourse before total healing of the wound was the highest risk factor for an infection. Among others, studies refer colonization with genital warts, condyloma [1] and vaginitis due to genital piercing [2]. An article of Modest & Fangman [19] reported hyperprolactinemia after a nipple piercing. Ochsenfahrt and co-authors observed endocarditis, which was associated with a nipple piercing [20]. Several other authors found in their studies correlations between piercings and endocarditis as a result of penetration of bacteria into the bloodstream [18, 22, 30, 31]. Several articles reported significantly increased risks of becoming infected due to genital piercings with pathogens [9, 10]. Javaid & Shibu referred an inflammation after nipple piercing in a woman who already wore a breast implant [11].

Motivs

By definition the application of a body modification caused pain and in addition includes several risks of illness. Why do people this? With the help of text analysis of reports a variety of motivations could be found [13, 14, 28, 29]. A hitherto unpublished study by Müller, Prassl, Schachner & Roth in Austria found these motifs: Body art (30%), increasing of attractiveness (22%), identity-increase + standing out of the crowd (13%), dare + sensation seeking (12%), marking a period of life (11%), role of models + peer pressure + imitation (9%), protest + rebellion (6%), borderline experiences (5%), growing-up + becoming independent (5%), body control (4%), sexual motifs (4%), religious motifs + spiritual meaning (2%), increase of sensibility (2%), love + love affliction (1%), fetishism + exhibitionism + S / M (1%) and other (4%).

Of course, the embellishment of the genital area has primarily sexual reasons. Borckenhagen and Brähler [6] cited studies showing that two-thirds of the surveyed young girls, shaved their pubic hair because they estimated it as "beautiful", 41% named hygienic reasons and one in five girls openly admitted to shave their genital area because her boy liked it better. The authors assume that a visual and tactile barrier is removed by the shaving; stroking can be felt more intensively, the female genital is visible and allows the woman to be more aware of her sexuality. Regarding genital piercing Stirn [26] wrote that women with body jewelry demand their body more as their property than other women, and often the ability to achieve an orgasm was considerably increased. She cited studies that women with genital piercings are less sexually uptight and show less negative emotions than women without body jewelry. However, the proportion of homosexual and bisexual women in the group of modified is higher

and there is even a stronger tendency to sadomasochistic techniques.

According to Stirn [26], genital piercings are primarily intended to improve the sexuality and the increase of their own body image. In 2008 Rohr had an interesting article, indicating that piercings and tattoos are for adolescents a conviction of their own identity [25]. The desire for autonomy and self-empowerment is particularly evident by opting for permanent body jewelry. Another, at first glance rather astonishing reason from the spectrum of possible motivations is a kind of self-therapy. Many carrier hope to cope better with own problems, as e.g. lack of confidence, shyness, anxiety, depression or negative memories.

To get a body modification is always associated with pain and can thus for many young people be a kind of modern daring [15], they provide evidence that he or she can endure pain. In this respect genital jewelry can have psychotherapeutic effects. In my book about body modification (13) extreme cases were reported. In one example tells a teen that she was sexually abused, an event from which she mentally could not dissolve for years and which shadowed her life. She decided for a piercing, which should mark the end of a negative and the start of a positive development for her. While the needles were stung, she kept thinking about her past after. After a while, the piercer said to her, "*Remember, this is something you do for you and not for anything from your past.*" In this moment tears broke out of her eyes, she wrote: "*At this moment, I felt safe and secure and was ready to let the tears out, which I had closed in me long eleven years. I was just myself. I had the intense feeling of liberation.*"

ACKNOWLEDGMENTS

I thank Herman of "Paint it black" in Bargteheide for his insider informations and the tattoo artist Tracy Duggan from Lübeck for their help in finding photos for the image material contained in this article. I thank Melanie and Veronica for their pictures of body areas which you do not show everybody.

REFERENCES

1. Altman JS, Manglani KS. Recurrent condyloma acuminatum due to piercing of the penis. *Cutis*. 1997 Nov;60(5):237-8.
2. Amsel R, Totten PA, Spiegel CA, Chen KC, Eschenbach D, Holmes KK. Nonspecific vaginitis: diagnostic criteria and microbial and epidemiologic associations. *The American journal of medicine*. 1983 Jan 1;74(1):14-22.
3. Brähler E, Stirn A, Brosig B. Verbreitung von Körperschmuck und Inanspruchnahme von Lifestylemedizin in Deutschland. Ergebnisse zweier Repräsentativerhebungen.
4. Bone A, Ncube F, Nichols T, Noah ND. Body piercing in England: a survey of piercing at sites other than earlobe. *bmj*. 2008 Jun 19;336(7658):1426-8.
5. Borkenhagen A. Designervagina--Enhancement des weiblichen Lustempfindens mittels kosmetischer Chirurgie. *Zur sozialen Konstruktion weiblicher kosmetischer Genitalchirurgie. Psychosozial*. 2008; (112):23.
6. Borkenhagen A, Brahler E. Die nackte Scham--theoretische und empirische Aspekte des aktuellen Trends zur weiblichen Teil- bzw. Vollintimrasur. *Psychosozial*. 2008; (112):7.
7. Dirie W. *Desert Flower*. Virago Press. 1999.
8. Feige M, Krause B. *Piercing intim: mein kleines Geheimnis*. Schwarzkopf & Schwarzkopf; 2004.
9. Willmott FE. Body piercing: lifestyle indicator or fashion accessory? *International journal of STD & AIDS*. 2001 Jun 1;12(6):358-60.
10. Fiumara NJ, Capek M. The bustwarze, or nipple ring. *Sexually transmitted diseases*. 1982 Jul 1;9(3):138-9.
11. Javaid M, Shibu M. Breast implant infection following nipple piercing. *British journal of plastic surgery*. 1999 Dec;52(8):676-7.
12. Kaatz M. Ein Trend und seine Komplikationen: Piercing. *Kosmet Medizin*. 2001;4:188-93.
13. Kasten E. Body-Modification: psychologische und medizinische Aspekte von Piercing, Tattoo, Selbstverletzung und anderen Körperveränderungen. Ernst Reinhardt; 2006.
14. Kasten E. Körperveränderung--Mein Körper gehört mir. *Psychologie heute*. 2007;34(2):64.
15. Kasten E. BodyModification als modernes Mannbarkeitsritual. *psychosozial*. 2007(110):117.
16. Kühne TN. Subklinische und persönlichkeitspsychologische Determinanten von Menschen mit Körpermodifikationen. Diplomarbeit, Universität Leipzig Fakultät für Biowissenschaften, Pharmazie und Psychologie Institut für Psychologie II. 2007.
17. Lloyd J, Crouch NS, Minto CL, Liao LM, Creighton SM. Female genital appearance: 'normality' unfolds. *BJOG: An International Journal of Obstetrics & Gynaecology*. 2005 May 1;112(5):643-6.
18. Millar BC, Moore JE. Antibiotic prophylaxis, body piercing and infective endocarditis. *Journal of Antimicrobial Chemotherapy*. 2004 Feb 1;53(2):123-6.
19. Modest GA, Fangman JJ. Nipple piercing and hyperprolactinemia. *New England Journal of Medicine*. 2002 Nov 14;347(20):1626-7.
20. Ochsenfahrt C, Friedl R, Hannekum A, Schumacher BA. Endocarditis after nipple piercing in a patient with a bicuspid aortic valve. *The Annals of thoracic surgery*. 2001 Apr 30;71(4):1365-6.
21. Preuss R. *Sexuelle Sensationen*. Flensburg: Stephenson Verlag. 1983.

22. Raja SG, Shad SK, Dreyfus GD. Body piercing: a rare cause of mitral valve endocarditis. *Journal of heart valve disease*. 2004 Sep 1;13(5):854-6.
23. Ramage I, Wilson N, Thomson R. Fashion victim: infective endocarditis after nasal piercing. *Archives of disease in childhood*. 1997 Aug;77(2):183.
24. Reitzenstein F. *Das Weib bei den Naturvölkern - Eine Kulturgeschichte der primitiven Frau*. Berlin: Neufeld & Henius. 1923.
25. Rohr E. Körpermanipulationen in der weiblichen Adoleszenz am Beispiel von Piercings und Tattoos. *Psychosozial*. 2008(112):13.
26. Stirn A. Intimpiercing. In: Ada Borkenhagen und Elmar Brähler (Hrsg.) *Intimmodifikationen*. *Psychosozial*. 2008; 112, 65-76.
27. Stirn A, Decker O, Brähler E. Körperkunst und Körpermodifikation. *Psychosozial*, Gießen. 2003.
28. Stirn A. Body piercing: medical consequences and psychological motivations. *The Lancet*. 2003 Apr 5;361(9364):1205-15.
29. Stirn A. Motivation von Tätowierten und Gepiercen für die Körpermodifikationen. Ergebnisse einer ersten deutschen Fragebogenerhebung. *Zeitschrift für Klinische Psychologie, Psychiatrie und Psychotherapie*. 2004; 52(1), 43-58.
30. Strom BL, Abrutyn E, Berlin JA, Kinman JL, Feldman RS, Stolley PD, Levison ME, Korzeniowski OM, Kaye D. Dental and cardiac risk factors for infective endocarditis: a population-based, case-control study. *Annals of Internal Medicine*. 1998 Nov 15;129(10):761-9.
31. Tronel H, Chaudemanche H, Pechier N, Doutrelant L, Hoen B. Endocarditis due to *Neisseria mucosa* after tongue piercing. *Clinical Microbiology and Infection*. 2001 Jun 1;7(5):275-6.
32. Turkof E, Sonnleitner E. & Stirn A. *Schamlippenkorrektur*. Wien: Maudrich-Verlag, 2008.
33. Utz-Billing I, Kentenich H. Weibliche Genital verstümmelung--eine Intimmodifikation mit langer Tradition. *Psychosozial*. 2008(112):31.
34. Van der Meer GT, Schultz WC & Nihman JM. Intimate body piercings in woman. *Journal psychosomatic Obstetrics Gynaecology*. 2008;29(4), 235-239.

Internetsources

- {1} <http://www.zeit.de/2009/29/Schoenheit?page=all>
- {2} <http://www.yaacool.com/index.php?article=1541>
- {3} <http://www.urbia.de/archiv/forum/th-2292270/Umfrage-an-die-Maenner-findet-Ihr-grosse-Schamlippen-erotisch.html>