

Original Research Article

## A Prospective Study of Open Reduction and Internal Fixation of Complex Acetabular Fractures

Dr. Praveen. S.K<sup>1</sup>, Dr. Venkatachalam. K<sup>2</sup>, Dr. Mani.A<sup>1</sup>, Dr. Prakash Karrun<sup>1</sup>, Dr. B. Bheeshma<sup>1</sup>

<sup>1</sup>Final Year M.S. Ortho PG, <sup>2</sup>Professor

Department of Orthopaedics, Sree Balaji Medical College and Hospital, No. 7, Works Road, New Colony, Chromepet, Chennai- 600044, Tamilnadu, India.

### \*Corresponding author

Dr. Venkatachalam K

Email: [sairam137@yahoo.co.in](mailto:sairam137@yahoo.co.in)

**Abstract:** Acetabular fractures being intra-articular, on a major weight bearing joint-the hip; pose major surgical challenges, especially the complex ones. This prospective study done at the Department Of Orthopaedics, Sree Balaji Medical College and Hospital, Chromepet, Chennai from July 2013 to August 2016 analysed 38 cases of complex fractures of acetabulum, occurring in the age group of 18 to 60 years. The open reduction internal fixation functional outcome results were analysed using the modified Merle's Aubigne and Postel grading system and the radiological outcome by the Mattas' criteria. In our study 94% of patient had satisfactory result and 58% had excellent results as per Mattas' radiological criteria.

**Keywords:** Complex acetabular fractures, Merle'd Aubigne and Postel grading system, Matta's radiological criteria, Kocher-langenbeck approach, ilioinguinal approach

### INTRODUCTION:

Only 10% of the pelvic disruptions involve the acetabulum. Posterior wall fractures are by far the most common, comprising 24% of acetabular fractures. The primary cause in younger individuals is high-velocity trauma. Acetabular fractures generally occur in conjunction with other fractures. The treatment of acetabular fractures is an enigmatic area of orthopaedics that is being continually refined. It involves a definite learning curve. Patient age, fracture stability, the presence of co-morbidities and osteoporosis, combined with surgeons experience all influence treatment options and the final outcomes. The goals of the treatment should be anatomic reconstruction of articular surface and early non-weight bearing mobilisation. This goal can be achieved only when acetabulum is rigidly internally fixed. Displaced fractures of the pelvis that involve the acetabulum are difficult to treat. With closed methods, it is difficult, if not impossible, to restore the articular surfaces completely and obtain sufficient stability for early motion of the hip [1].

Treatment of complex Acetabular fracture is difficult as it involves both the column of the acetabulum, for reduction and fixation; both columns have to be manipulated and fixed. The purpose of this study is to analyse the results and functional outcome of open reduction and internal fixation of fracture

involving both acetabular columns (Complex Acetabular Fractures) with the use of Kocher Langenbeck, ilioinguinal or both surgical approaches. Fractures involving both acetabular columns are complex Acetabular Fractures [2] (AO Type B & C). Based on Judet and Letournel classification, the fractures included are:

- Transverse fracture
- Transverse with posterior wall fracture
- T type fracture
- Anterior wall or column with posterior hemi transverse fracture.
- Both column fractures.

### MATERIALS AND METHODS:

This is a prospective study done to assess the functional outcome of complex acetabular fractures treated by open reduction and internal fixation in 38 patients over the period of three years from July 2013 to August 2016 at Sree Balaji Medical College And Hospital, Chromepet, Chennai.

#### Age greater than or equal to 18 years.

1. Closed fractures.
2. Transverse fractures.
3. Transverse with posterior wall fracture.
4. T Type fracture.

5. Anterior column or wall with posterior hemi transverse fracture.
6. Both column fractures.

**Exclusion criteria are:**

1. Open fractures.
2. Simple fractures.
3. Fracture older than 3 weeks.

After haemodynamic stabilization of the patients, a detailed clinical examination and radiological assessment was done. Patients were put on upper tibial skeletal pin traction. Patients were operated between 3 to 7 days based on principles of Damage Control Orthopaedics.

**FRACTURE CLASSIFICATION ADOPTED:**

Classification of acetabular fractures is a key element in understanding the injury and is the first stage of surgical planning. Decisions concerning the choice of approach and the alternative fixation techniques available require full appreciation of the fracture anatomy. In this study we followed the Judet and

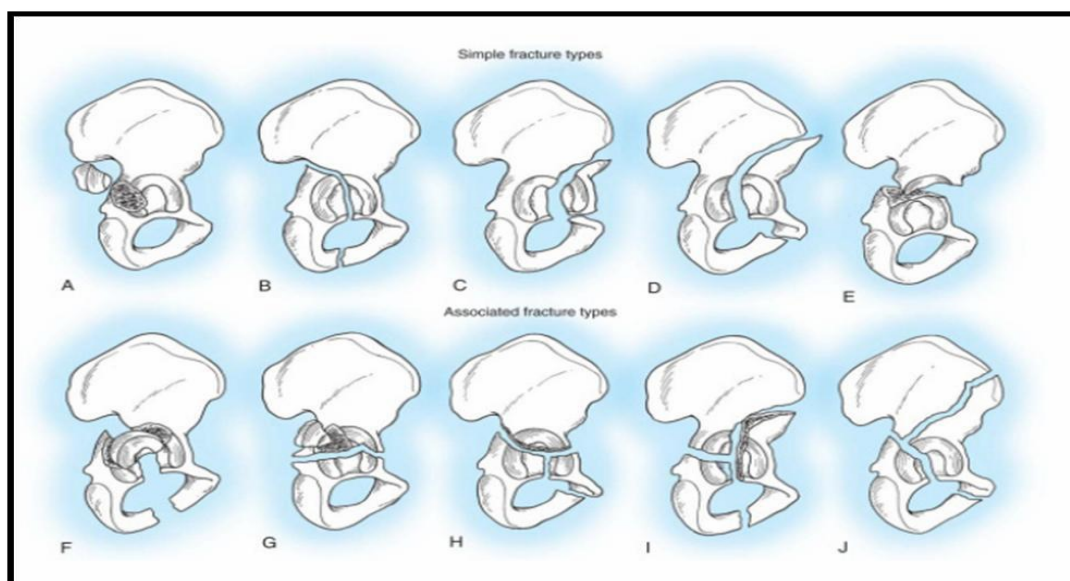
Letournel [3-5]. Classification because it is simple and useful in planning the treatment. Letournel and Judet's anatomical classification is divided into two groups: elementary and associated fractures, with five patterns in each. JUDET AND LETOURNEL CLASSIFICATION [13].

**ELEMENTARY TYPES:**

- Posterior wall.
- Posterior column.
- Anterior wall.
- Anterior column and.
- Transverse fractures.

**ASSOCIATED FRACTURE TYPES:**

- T type fractures.
- Combined fractures of the posterior column and wall.
- Combined transverse and posterior wall fractures.
- Anterior column fractures with a hemi-transverse posterior fracture.
- Both-column fractures.



**Letournel and Judet classification**

**CLINICAL AND RADIOLOGICAL ASSESSMENT:**

On arrival at the trauma centre, the general condition was assessed rapidly. Primary survey of Airway, Breathing and hemodynamic status was assessed and resuscitation measure were done. Secondary survey was done in detail which includes complete skeletal examination, examination of abdomen and pelvis and CNS. Detailed History was taken as the mode of injury gives the magnitude of force and its direction, upon which depends the pattern, displacement and comminution of fracture. A thorough physical examination includes inspection for external injuries, wounds, contusions and bruises. Special attention was given to look for Morel Levelle lesion [6],

bleeding per urethral meatus, rectal tear and other perineal injuries. Attitude of the injured limb and its distal neurovascular status was assessed. Rectal examination was done to rule out rectal tear and central dislocation of head of femur which is palpated as a globular mass [7].

**RADIOLOGICAL INVESTIGATIONS:**

After clinical assessment, and haemodynamic stabilization, patient was shifted for radiological assessment. Three radiographic views of acetabulum and CT scan form the standard protocol.

- Anteroposterior pelvis
- Judet views- obturator and iliac oblique views.
- CT scan – with 3D reconstruction.

**CT SCAN:**

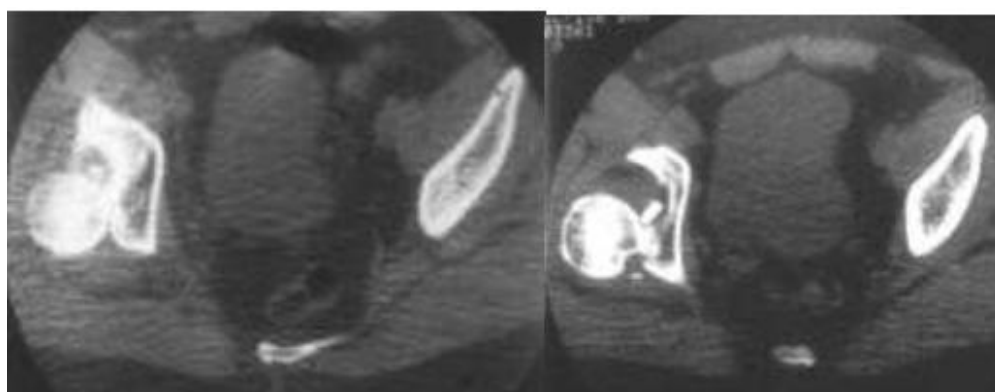
CT scan helps in identification of fracture lines not visualized by radiographs. Orientation of fracture line, vertical portion of T- type acetabular fracture and rotation of fracture fragments are well made out. CT scan may give additional informations regarding

- Intra-articular loose fragments.
- Marginal impacted fragment.
- Degree of fracture comminution.
- Position of the femoral head.
- Femoral head lesions.

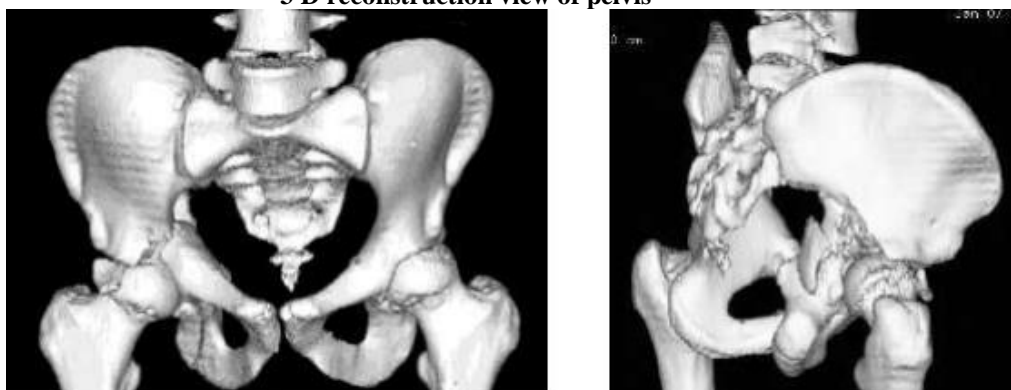- Joint Congruence.
- Sacroiliac joint and the posterior pelvic ring.

**3-D CT SCAN:**

It is converted from 2 dimensional CT scan data. 3D CT allows for subtraction of femur and varying degree of rotation of pelvis which provide a good overall picture of the fracture configuration [8].



3 D reconstruction view of pelvis



CT cuts of Acetabulum

**TREATMENT PROTOCOL:**

**AFTER INITIAL ASSESSMENT:**

Closed reduction was done in dislocated patients under i.v sedation and skeletal traction was applied in all patients.

**TIME OF SURGERY:** Open reduction and internal fixation was done within 2 to 7 days of injury.

**PRE OPERATIVE PLANNING:**

After completing clinical and radiological examination pre-operative planning regarding approach and implant to be used was made on basis of fracture type, displacement and associated injuries.

**SURGICAL EXPOSURE:**

Surgical exposure was decided preoperatively based on fracture displacement. Kocher Langenbeck

approach was used for posterior fractures and anterior ilioinguinal approach was used for anterior fractures. After reducing and fixing one column the reduction of other column was assessed by image intensifier and the need for exposing the other column was made.

**SURGICAL EXPOSURES:**

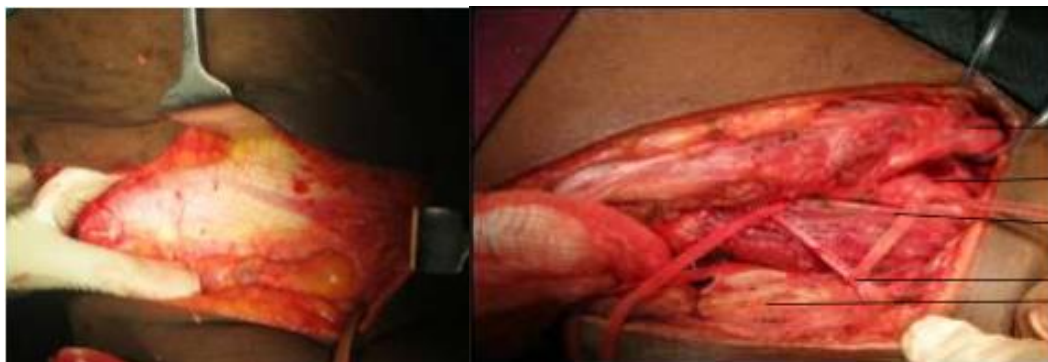
Surgical exposure is of great value in acetabular fracture, surgery as accurate reduction and fixation can only be possible with good surgical exposure. Extensile approaches like extended iliofemoral and triradiate have unwanted complications like skin necrosis, vascular compromise to abductors and heterotopic ossification in particular. We had used non extensile approaches either alone or in combination.

1. Anterior ilioinguinal approach [9].
2. Posterior Kocher Langenbeck approach [10].

**Anterior ilioinguinal Approach:**

Patient was placed on radiolucent operating table in supine position. Skin incision was placed in midline 2 fingerbreadths above the symphysis pubis, extended to the anterior superior iliac spine and then continued posteriorly along the line of the iliac crest. The aponeurosis of the external obliquus was incised in line with the skin incision. An incision was carefully made along the inguinal ligament from its medial attachment to the pubis to the anterior superior iliac spine along its fibres. Three windows were created for

visualization. The first window was formed by medial retraction of the iliopsoas and femoral nerves allowing visualization of the entire internal iliac fossa, the sacroiliac joint, and the pelvic brim. After mobilizing the iliopsoas muscle, Iliopectineal fascia was palpated and their medial and lateral surface was defined before its division. Blunt dissection was continued below the vessels. The second window was created by lateral retraction of the iliopsoas and femoral nerve, combined with medial retraction of the external iliac vessels and third window by lateral retraction of the vessels. Ilioinguinal approach.



**Oblique fibres of external oblique muscle:**

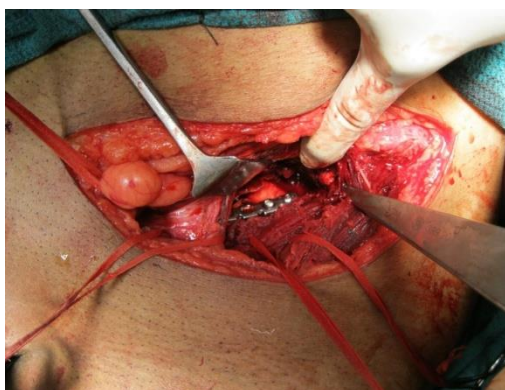
**From down upward:**

Structure dividing three windows –iliac crest, lateral cutaneous nerve of thigh, iliopsoas femoral nerve, femoral vessels and spermatic cord.

**Posterior Kocher Langenbeck Approach:**

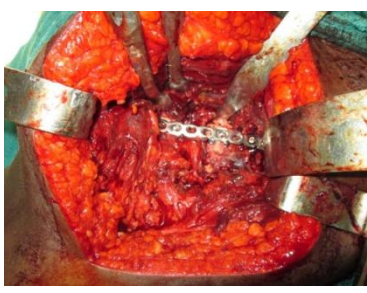The patient was usually positioned in a prone position on radiolucent table. Skin incision was placed lateral to the posterior superior iliac spine, extended to the greater trochanter, and then continued along the axis of the femur to almost the midpoint of the thigh. The sciatic nerve was identified on the posterior surface of

the quadratus femoris and followed proximally until it disappears beneath the piriformis. The tendons of the piriformis and obturator internus are transected at their trochanteric insertion and retracted posteriorly, exposing the greater and lesser sciatic notch. Subperiosteal elevation was done to expose the inferior aspect of the iliac wing. A trochanteric osteotomy can help in further visualization of the inferior iliac wing and the interior of the joint. Alternatively, the tendon of the gluteus medius can be partially transected. The gluteus maximus tendon was transected at its femoral insertion if needed.

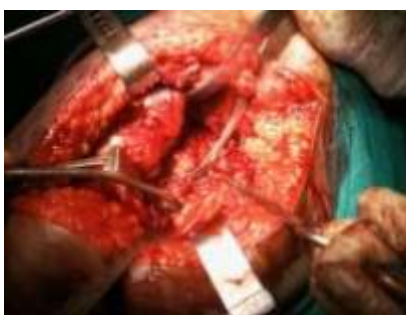

**Anterior ilioinguinal approach with its three windows after plating**

**Kocher Langenbeck Approach**



**Posterior Kocher Langenbeck approach exposed short external rotators.**

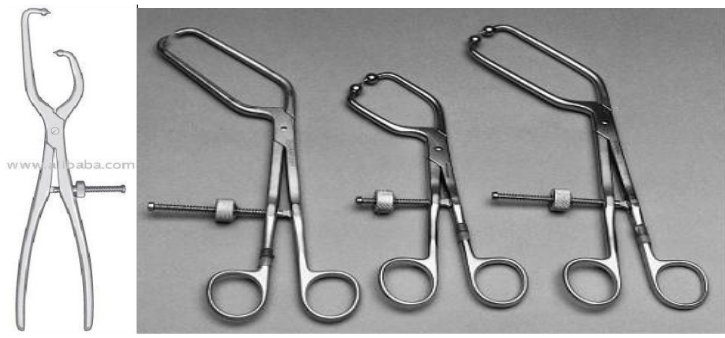


**Posterior Kocher Langenbeck approach after putting lag screws and buttress plate**

**REDUCTION TECHNIQUES:**

After exposure reduction poses the challenge. Reduction can't be achieved easily as in any long bones and manoeuvres are not the same. In posterior approach, Schanz pins are placed in trochanter, ischial tuberosity and iliac crest for simultaneous manipulation. Various reduction clamps are available to facilitate reduction and holding. In anterior approach a Farabeuf

clamp or a schanz pin are placed in iliac crest to manipulate and reduce. Matta's Quadrangular clamp of various sizes and with offsets and Picador ball spike pusher are very important instruments in Acetabular surgery. Reduction was fixed with lag screws whenever possible. Lagging was done with 4mm cancellous screws or 3.5 mm cortical screw with washer. 3.5mm Reconstruction plates are used as neutralization plate.



**Matta's Quadrangular clamps**



Farabeuf clamps



Multipurpose plate bender for recomplete



Picador ball spike pusher with pusher

**POST OPERATIVE PROTOCOL:**

- All patients were given pre-operative antibiotics which was continued post operatively for 5days.
- Drain removal was done 2<sup>nd</sup>post-operative day.
- Suture removal was done alternatively on post-operative day 12 and 14.
- Indomethacin 75mg SR OD was prescribed orally for 6 weeks from next day after surgery.
- Low molecular weight heparin was given for 7 days when anterior approach is used as a DVT prophylaxis.
- Passive mobilization was started from 2<sup>nd</sup> post-operative day.
- Active assisted movements of the lower limb started gradually in accordance with the pain tolerance.

- Weight bearing was allowed as the fracture consolidates mostly by the 3<sup>rd</sup> or 4<sup>th</sup> month. Radiological and functional examination was done on a monthly basis for first 6 months and once in two months.

**OUTCOME ASSESMENT TOOLS AND CRITERIA:**

Patients in our study were analysed by the Matta's radiographic assessment post operatively and modified Merle d'Aubigné and Postel Hip Score at each follow up.

Functional Outcome: Modified Merle'd Aubigné And Postel Grading System:

| <b>Matta reduction criteria</b>      |  |
|--------------------------------------|--|
| <b>Anatomical</b>                    | zero to one millimetre of displacement |
| <b>Imperfect</b>                     | two to three millimetres               |
| <b>Poor</b>                          | more than three millimetres            |
| <b>Surgical secondary congruence</b> |  |

| <b>Matta radiographic criteria at follow-up</b> |   |
|---|---|
| <b>Excellent</b>                                | Normal appearance of the hip;   |
| <b>Good</b>                                     | Mild changes, small osteophytes, moderate (1 mm) narrowing of joint & minimum sclerosis;  |
| <b>Fair</b>                                     | Intermediate changes, moderate osteophytes, moderate (<50%) narrowing of joint & moderate sclerosis;                                  |
| <b>Poor</b>                                     | Advanced changes, large osteophytes, severe (>50%) narrowing of the joint, collapse or wear of the femoral head, and acetabular wear. |

| <b>Merle d' Aubigne and Postel criteria</b>   |          |
|---|----------|
| <b>Pain</b>                                   |          |
| None  | 6        |
| Slight or intermittent                        | 5        |
| After walking but resolves                    | 4        |
| Moderately severe but patient is able to walk | 3        |
| Severe, prevents walking                      | 2        |
| <b>Walking</b>                                |          |
| Normal  | 6        |
| No cane but slight limp                       | 5        |
| Long distance with cane or crutch             | 4        |
| Limited even with support                     | 3        |
| Very limited                                  | 2        |
| Unable to walk                                | 1        |
| <b>Range of motion</b>                        |          |
| 95-100%                                       | 6        |
| 80-94%  | 5        |
| 70-79%  | 4        |
| 60-69%  | 3        |
| 50-59%  | 2        |
| <50%  | 1        |
| <b>Clinical grade</b>                         |          |
| Excellent                                     | 18       |
| Good  | 15,16,17 |
| Fair  | 13,14    |
| Poor  | <13      |

**RESULTS:**

**Table 01: Age Distribution**

| Age            | No of Patients | Percentage |
|----------------|----------------|------------|
| < 20 Years     | 05             | 13.16 %    |
| 21 to 30 Years | 12             | 31.58%     |
| 31 to 40 Years | 10             | 26.32%     |
| 41 to 50 Years | 06             | 15.78%     |
| 51 to 60 years | 05             | 13.15%     |
| TOTAL          | 38             | 100%       |

The Mean age of the patients was 35.45 year ranging from 18 to 60years.

**Table 02: Sex Incidence**

| SEX    | MALES | FEMALES | TOTAL |
|--------|-------|---------|-------|
| NUMBER | 33    | 5       | 38    |

Males dominated in our study (86.84%) with M: F ratio of 33:5.

**Table 03: Mode Of Injury**

| Mode of injury   | No. of Patients | Percentage |
|------------------|-----------------|------------|
| RTA              | 30              | 78.95%     |
| Fall from height | 8               | 21.05%     |
| TOTAL            | 38              | 100%       |

Majority of the patients suffered Road Traffic Accidents followed by fall from height

**Table 04: Fracture Type Distribution**

| Fracture type ( Judet and Letournal)           | No. of Patients | Percentage |
|--|-----------------|------------|
| Transverse                                     | 18              | 47.37%     |
| Transverse with posterior wall                 | 6               | 15.78%     |
| Anterior column with posterior hemi transverse | 5               | 13.16%     |
| T type   | 5               | 13.16%     |
| Both column                                    | 4               | 10.52%     |
| TOTAL  | 38              | 100%       |

**Table 05: Associated Injuries**

| Associated injuries                             | No. of Patients |
|---|-----------------|
| Fracture of clavicle                            | 1               |
| Fracture of Distal radius                       | 2               |
| Fracture of superior pubic rami B/L             | 1               |
| Fracture of Inferior pubic rami B/L             | 1               |
| Fracture Neck Of contra lateral Femur           | 1               |
| Intertrochanteric Fracture of ipsilateral Femur | 1               |
| Fracture shaft of contralateral Femur           | 1               |
| Fracture supracondylar femur ipsilateral side   | 1               |
| Fracture both bone contralateral leg            | 6               |
| Fracture Medial malleolus contralateral side    | 1               |
| Fracture Metacarpal                             | 1               |
| Sciatic Nerve palsy                             | 4               |
| Urethral injury                                 | 1               |
| TOTAL   | 22              |

In our study 22 patients had associated injuries.

**Table 06: Surgical Approaches Used**

| Procedure  | No.of Patients | Percentage |
|--|----------------|------------|
| Kocher Langenbeck Approach                                   | 24             | 63.16%     |
| Ilioinguinal Approach  | 6              | 15.79%     |
| Ilioinguinal approach Followed by Kocher langenbeck Approach | 3              | 7.89%      |
| Kocher Langenbeck Approach followed by ilioinguinal approach | 5              | 13.16%     |
| TOTAL  | 38             | 100%       |

**Table 07: Radiological (Mattas') And Clinical (MERLE *et al.*;) Criteria Outcome**

| OUTCOME          | RADIOLOGICAL n (%) | CLINICAL n (%) |
|------------------|--------------------|----------------|
| <b>EXCELLENT</b> | 16 (42.1)          | 21 (55.26)     |
| <b>GOOD</b>      | 6 (15.8)           | 15 (39.46)     |
| <b>FAIR</b>      | 8 (21.05)          | 1 (2.64)       |
| <b>POOR</b>      | 8 (21.05)          | 1 (2.64)       |
| <b>TOTAL</b>     | 38                 | 100            |

**Table 08: Mattas' Reduction Criteria**

| OUTCOME               | NUMBER OF PATIENTS |
|-----------------------|--------------------|
| ANATOMICAL(0 TO 1 mm) | 22                 |
| IMPERFECT (2 TO 3mm)  | 8                  |
| POOR (>3mm)           | 8                  |
| TOTAL                 | 38                 |

38 patients with complex acetabular fractures were treated surgically and analysed with average follow up of 16.8months ranging from 12 months to 40 months. The following observations were made:

1. Maximum number of patients were in the 3<sup>rd</sup> decade (31.58%) followed by patients in the 4<sup>th</sup> decade (26.32%).
2. Males dominated our study group with a ratio of 33:5
3. Road traffic accidents contributed to the injury in (78.95%) of our patients and rest sustained by fall from height.
4. Transverse fracture was the most common type in our study (47.37%, 18 cases). Both column

fractures were least common type (10.52% 4cases).

5. 22 patients had associated skeletal injuries. Four patients had sciatic nerve injury and one patient had urethral injury.
6. Most of the patient were operated by Kocher langenbeck approach (63.16%, 24 patients). Six patients were operated by ilioinguinal approach (15.79%). Eight patients were operated by combined approach (21.05%).
7. All patients were hemodynamically stable at the time of admission.
8. In our study the average surgical time delay was 4.6 days ranging from 2 to 10 days.
9. The average surgical time was 132 minutes ranging



from 90 minutes to 180 minutes.

10. Fourteen patients have encountered post-operative complications.
11. Eight patient operated by ilioinguinal approach had superficial infection which settled with antibiotics.
12. One patient had a deep circumflex vein tear managed by ligation following which he developed DVT that resolved with heparin.
13. One patient was found have intraarticular screw after being operated via anterior approach, but he had good functional outcome.
14. Four patients operated by posterior Kocher langenbeck approach developed sciatic nerve palsy.
15. No patient had sacroiliac disruption or pubic diastasis.
16. No patient died during treatment or follow up.
17. According to Mattas' criteria, 22patients had anatomic reduction, 8patients had satisfactory reduction and 8patients had poor reduction (>3mmgap).
18. Out of 38 patients as per Merle et al criteria, 14 patients had excellent, 12 patients had well, 9 patients had fair and 3 patients had poor results.
19. Mattas' radiological outcome and Merle critical outcome do not coincide. Thus we conclude that radiological outcome as interpreted by Mattas' criteria, does not having an outcome bearing when

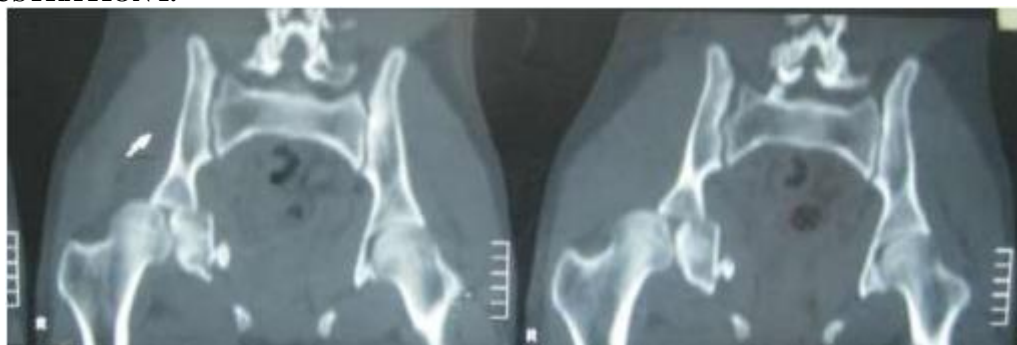
evaluated for clinical outcome as per Merle et al's criteria.

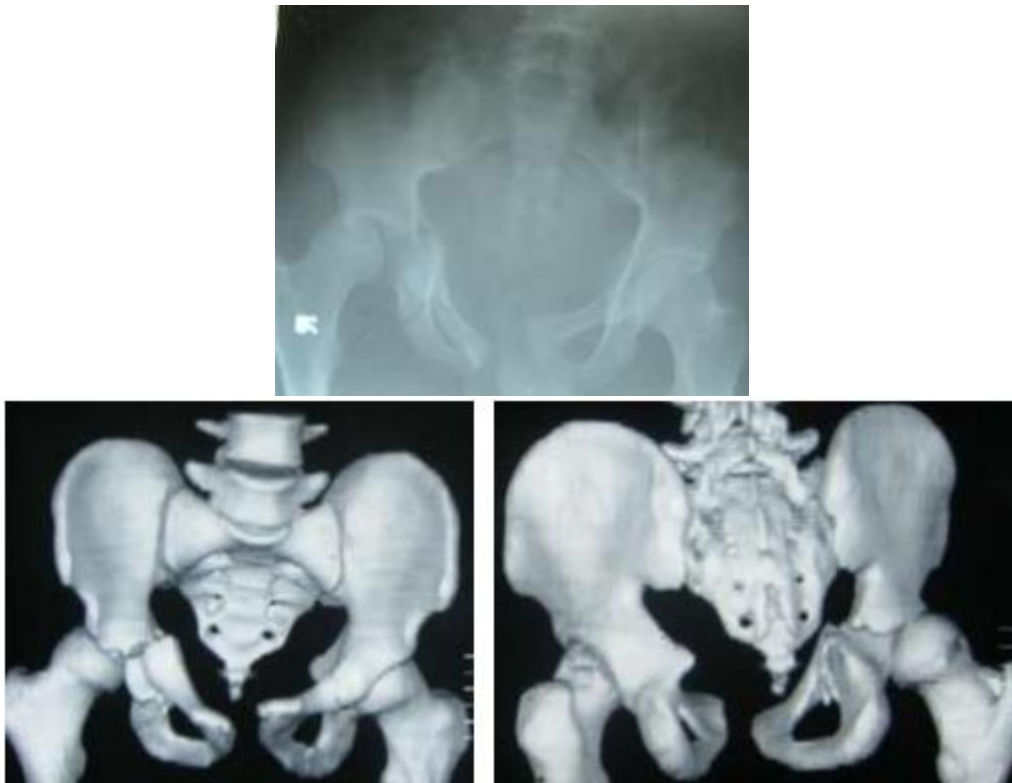20. 60% patient is having near normal life and 94% patient is having satisfactory result in our study.
21. Merle *et al.*; function outcome score for the patients ranged from 10 to 18 (Maximum Score-18). Mean score was 15.8.
22. The poor result (Score-10) in one patient was due to avascular necrosis of femoral head. Patient had transverse with posterior wall fracture operated by posterior Kocher Langenbeck approach. Total hip replacement was done for this patient at 13months after surgery.
23. There are 18 patients with transverse fracture. All patients with transverse fracture had excellent or good result except 4 patients who had fair result due to associated multiple skeletal injuries in the ipsilateral lower limb. 4 patients with both column fractures were operated by anterior Ilioinguinal approach and 2 patients had excellent and other 2 had good result.
24. Associated posterior wall fracture had reduced the outcome score.
25. T type fracture, anterior column with posterior hemi transverse and Transverse with posterior wall fracture had reduced outcome score than other two types.

**Table 9: Distribution of Fracture Pattern and Merle *et al.*; Functional Outcome Criteria**

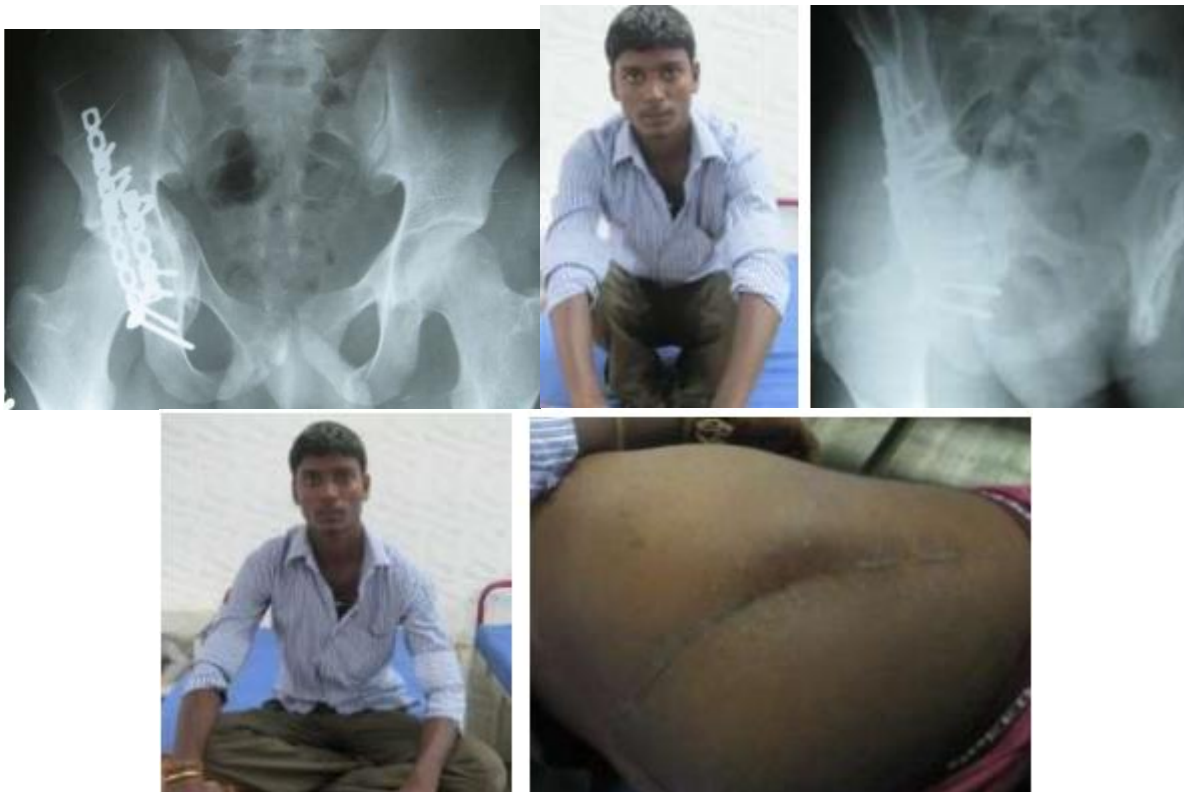| Fracture pattern                               | No. of cases | Average score out of 18 | Excellent | Good | Fair | Poor |
|--|--------------|-------------------------|-----------|------|------|------|
| Transverse                                     | 18           | 16.3                    | 9         | 5    | 4    | 0    |
| Transverse with posterior wall                 | 6            | 14.2                    | 0         | 4    | 1    | 1    |
| Anterior column with posterior hemi transverse | 5            | 14.0                    | 0         | 3    | 2    | 0    |
| T type   | 5            | 15.3                    | 1         | 1    | 3    | 0    |
| Both column                                    | 4            | 16.8                    | 2         | 2    | 0    | 0    |
| TOTAL  | 38           |                         | 12        | 15   | 10   | 1    |

**CASE ILLUSTRATION I:**

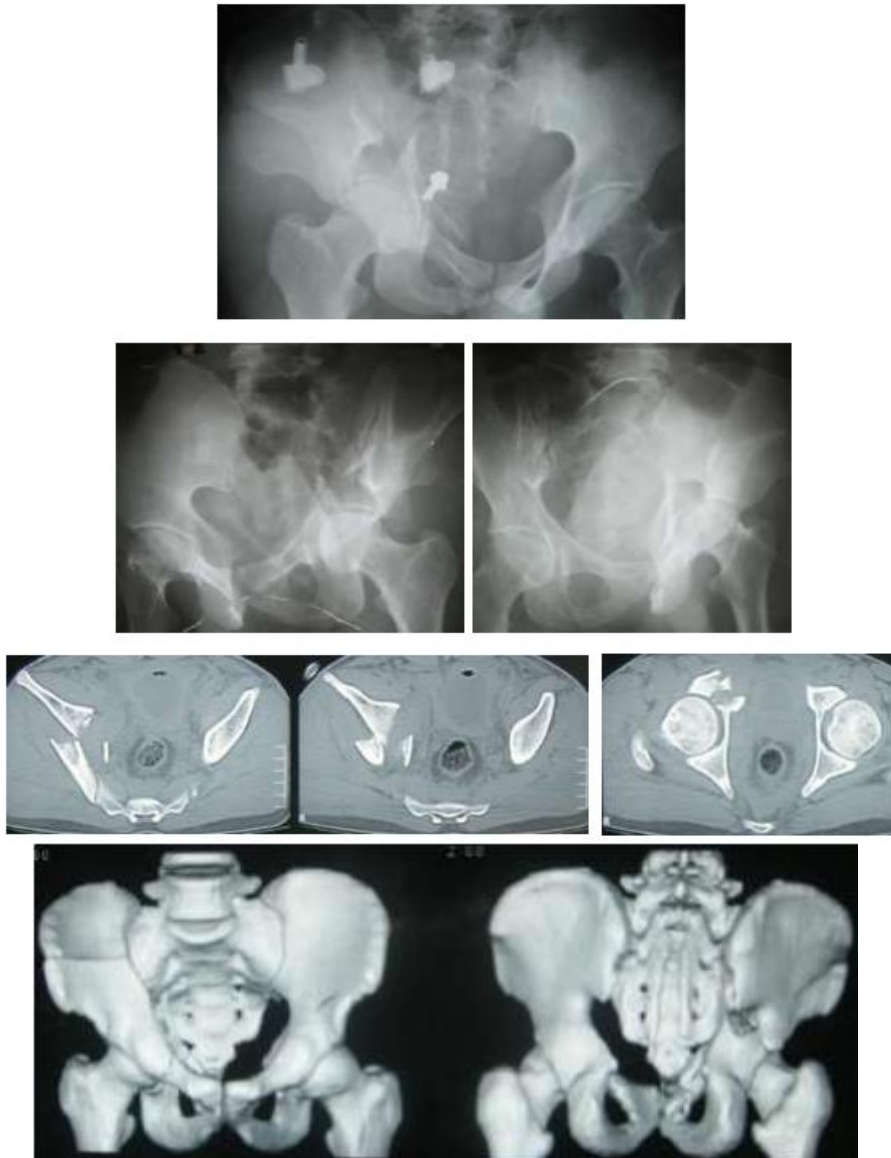




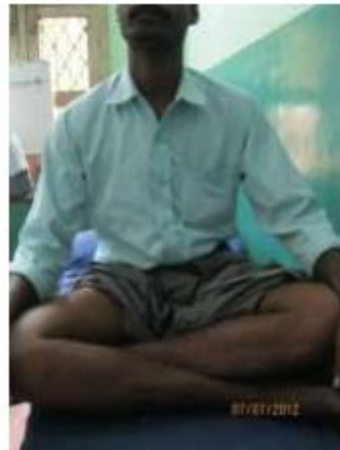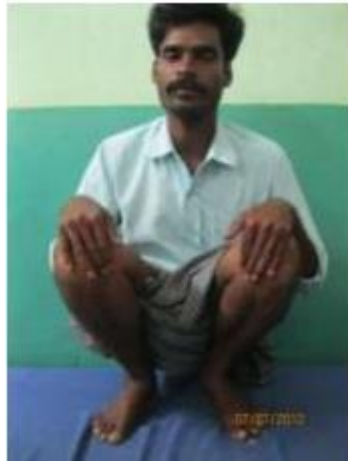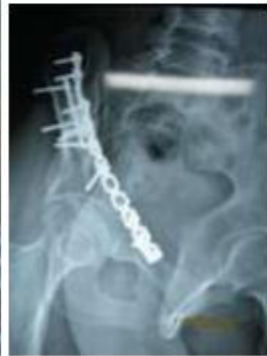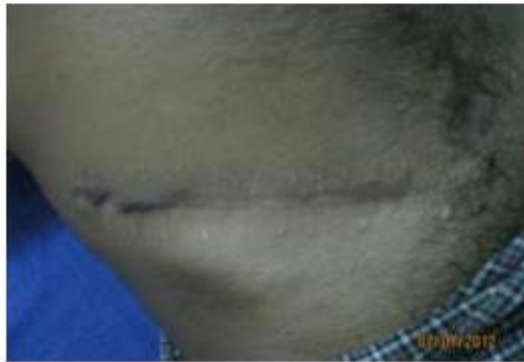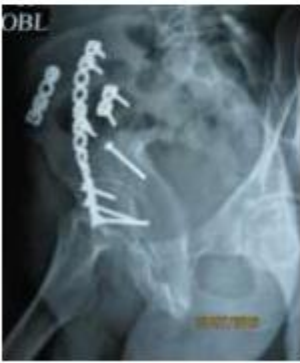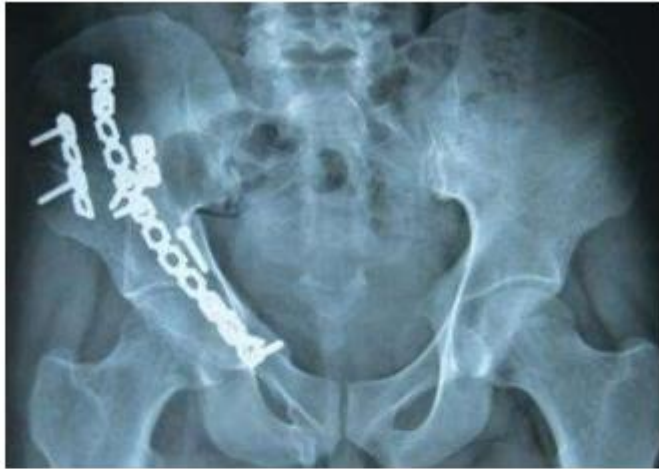**ONE YEAR FOLLOW UP:**



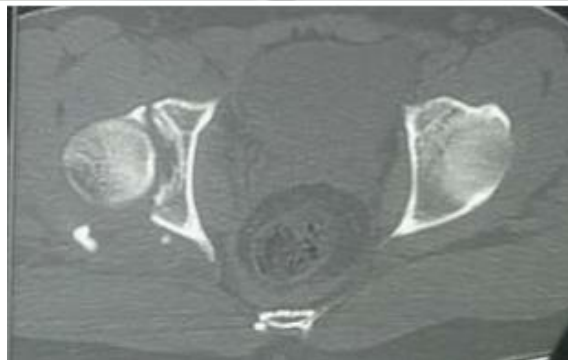
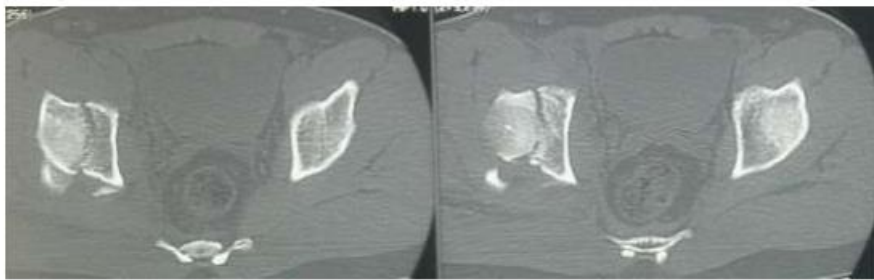
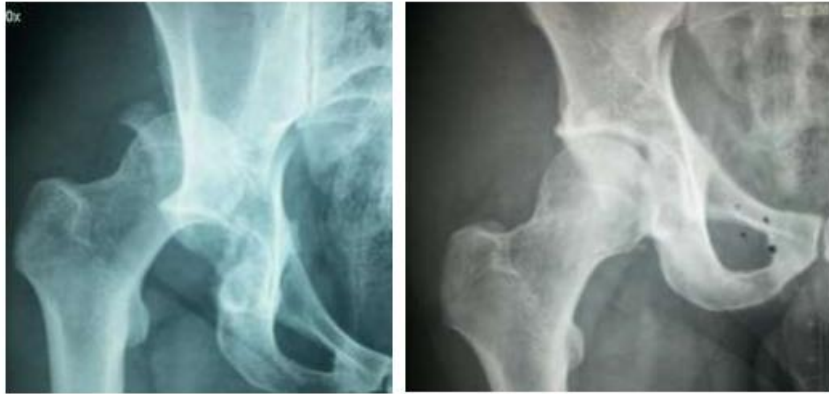**CASE ILLUSTRATION – II:**



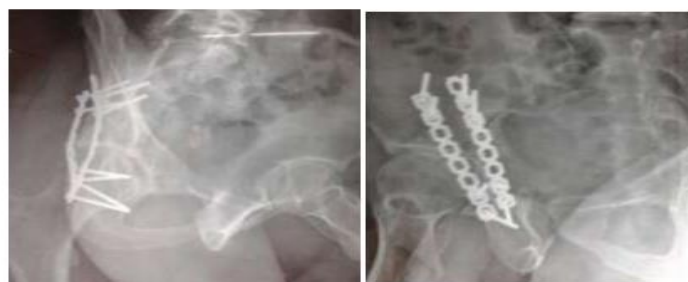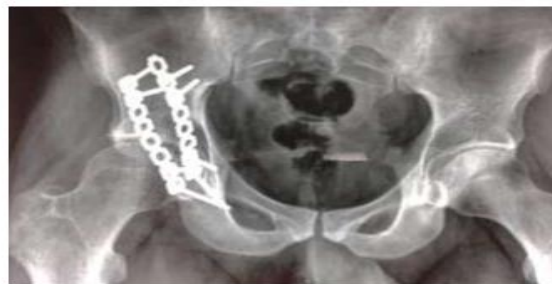**ONE AND HALF YEAR FOLLOW UP:**

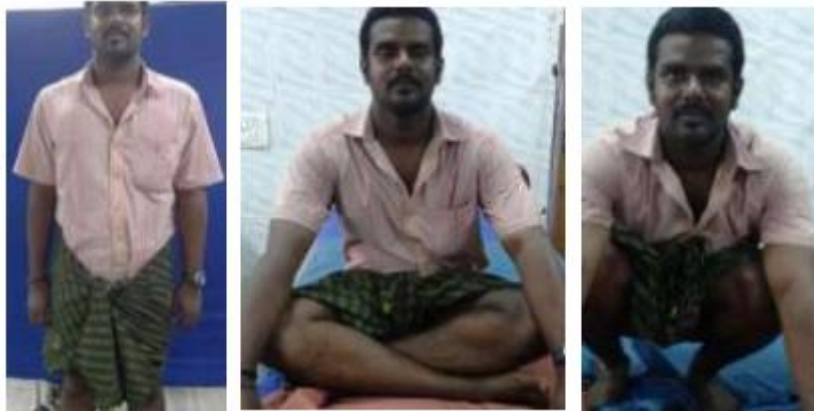

**CASE ILLUSTRATION – III:**

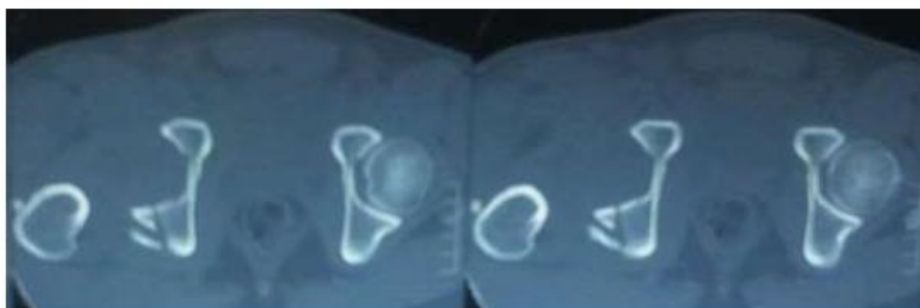
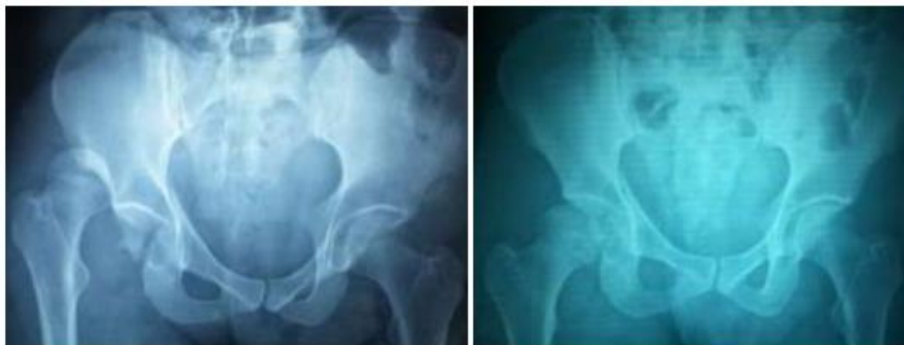
**NINE MONTH POST OP:**

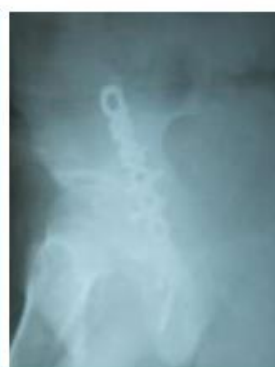
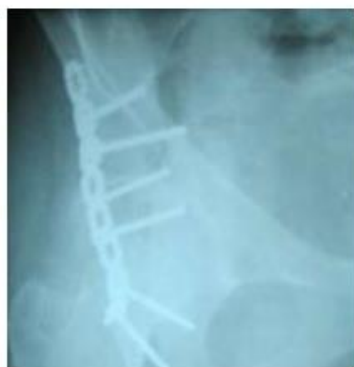
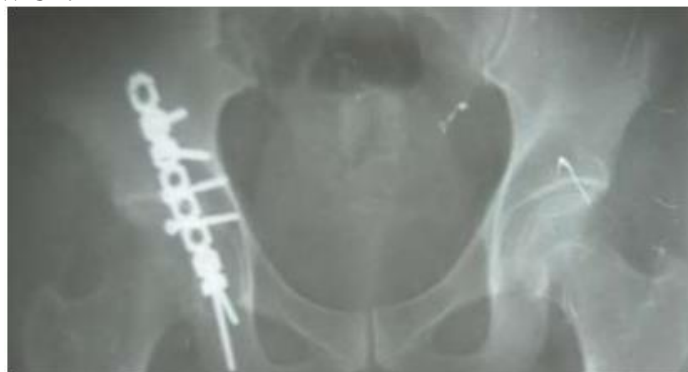

CASE ILLUSTRATION – IV:



**TEN MONTHS FOLLOW UP:**



**DISCUSSION:**

The options for treatment of complex acetabular fractures are wide and are continuously refined over time. The treatment of complex acetabular fracture is difficult because it involves both the columns and reduction of the FRACTURE both by single or double approach is must. The mean age group in our study was 31.2 years which is comparable with Swiontkowski *et al.*; [2] on complex acetabular fracture. Males predominated as in other studies [2]. Road traffic accident formed the major mode of injury. The highlight of open reduction and internal fixation is anatomic reduction, rigid fixation and early

mobilization which will keep the joint functional as described by Matta [5]. Pennal *et al.*; [18] reported that the quality of the clinical result depends directly on the quality of the reduction that was achieved when open reduction and internal fixation were performed. In our study, there is decreased mean functional score (14.5) in the fracture group with poor reduction compared to the rest (Anatomical Reduction 15.8 and Imperfect reduction -15.1). Management of displaced acetabular fracture requires adequate exposure with minimal morbidity. An ideal approach should allow visualization of both columns and the joint surface with minimal complications. We used only two non-extensile

approaches - Posterior Kocher Langenbeck approach and Anterior Ilioinguinal approach. We used single approach in most of the patients. With this single approach we are able to get 65% of satisfactory reduction and 94% of favorable result in short term. According to Tile, even with best hands depending on the type and complexity of fracture, anatomic reduction can be obtained in 70% cases of acetabular fractures. In our study we included only complex fractures and we were able to get satisfactory reduction in 68% patients. H. J. Kreder *et al.*; listed factors influencing the outcome [19] degree of initial displacement, damage to the superior weight bearing dome or femoral head, degree of hip joint instability caused by posterior wall fracture, adequacy of open or closed reduction and late complications like AVN, heterotrophic ossification, chondrolysis or nerve injuries are assessed. In our study associated posterior wall fracture had reduced the functional outcome.

Giannoudis *et al.*; [20] in his meta-analysis reported 5.6 % of AVN in posterior approaches. In our study, we had a case of avascular necrosis of femoral head leading to poor outcome (2.63%). Patient came with AVN at 13 months follow up for which total hip replacement was done. Extensile approaches around the hip joint have reported a high rate of complications. Alonso *et al.*; reported 53% incidence of heterotopic ossification with Triradiate approach and 86% incidence with the use of extended iliofemoral approach. No case of heterotopic ossification has been encountered till date in our study. Heterotopic ossification was reported as high as 20% in non-extensile approaches used for complex fractures according to Jiong Jiong Guo, *et al.*;. We report Indomethacin (75mg SR OD) for all patients for 6 weeks post operatively, as a prophylaxis for heterotopic ossification.

Giannoudis *et al.*; [20] reported 8% of iatrogenic sciatic nerve palsy in posterior approaches. In Our Study, We encountered 4 cases of sciatic nerve palsy in posterior approach (10.53%). Swiontkowski *et al.*; [2] also showed 8.3 % iatrogenic sciatic nerve palsy in his study. We encountered one case of DVT in the anterior ilioinguinal approach. We had a case of intra articular screw penetration in anterior approach, but the patient was asymptomatic and had excellent functional outcome.

The complication rate is relatively low when compared to Matta [5] and Swiontkowski studies [2]. Then non-extensile approaches which we adopted and advocate have operating time and average blood loss which are similar to those reported by others (Matta *et al.*; 1986; Goulet and Bray 1988; Reinert *et al.*; 1988; Routt and Swiontkowski 1990; Helfet *et al.*; 1992).

The mean functional outcome score in our study was 15.4 ranging from 10 to 18 (Maximum—18). The least score is seen in a patient with transverse with posterior hemi transverse fracture operated by Kocher langenbeck approach and which developed avascular necrosis of femoral head. According to Marwin M Tile, Transverse has the best and T Type and anterior column and posterior hemi transverse fracture has worst prognosis. In our study also Transverse fractures and both column fractures showed better results. T Type and anterior column with posterior hemi transverse had guarded outcome. Even though our study comprised of small group of 38 patients with good pre-operative planning, use of non-extensile approaches and early rehabilitation, we have been able to produce 94 % good to satisfactory results according to modified Merle d Aubigne and Postel scoring systems.

#### CONCLUSION:

From our study, we conclude that: Complex acetabular fractures treated by open reduction and internal fixation have a satisfactory functional outcome provided every effort is done to restore near anatomical reduction at the time of surgery. Use of non-extensile approaches itself is sufficient to produce adequate fracture reduction with acceptable complication rates. Rigid fixation and early non weight bearing mobilization must be done for better function which is not achievable by conservative means. Treatment of acetabular fractures is a challenging task for any orthopaedic surgeon. With definite learning curve, proper preoperative planning, non-extensile exposure, accurate reduction, rigid fixation and early rehabilitation, it is possible to produce a satisfactory outcome.

#### REFERENCES:

1. Schmidt CC, Gruen GS. Non-extensile surgical approaches for two-column acetabular fractures. *Bone & Joint Journal*. 1993 Jul 1; 75(4):556-61.
2. Routt ML, Swiontkowski MF. Operative treatment of complex acetabular fractures. Combined anterior and posterior exposures during the same procedure. *J Bone Joint Surg Am*. 1990 Jul 1; 72(6):897-904.
3. Kreder HJ, Rozen N, Borkhoff CM, Laflamme YG, McKee MD, Schemitsch EH, Stephen DJ. Determinants of functional outcome after simple and complex acetabular fractures involving the posterior wall. *Bone & Joint Journal*. 2006 Jun 1; 88(6):776-82.
4. Letournel E, Judet R, Elson RA. Classification. In *Fractures of the Acetabulum* 1993 (pp. 63-66). Springer Berlin Heidelberg.
5. Matta JM. Fractures of the acetabulum: accuracy of reduction and clinical results in patients managed operatively within three weeks after the injury. *J Bone Joint Surg Am*. 1996 Nov 1; 78(11):1632-45.
6. Sen RK, Nagi ON. Anterior fractures of



- acetabulum. Indian Journal of Orthopaedics. 2002 Jan 1;36(1):22.
7. Griffin DB, Beaulé PE, Matta JM. Safety and efficacy of the extended iliofemoral approach in the treatment of complex fractures of the acetabulum. *Bone & Joint Journal*. 2005 Oct 1;87(10):1391-6.
  8. Matta JM. Fractures of the acetabulum: accuracy of reduction and clinical results in patients managed operatively within three weeks after the injury. *J Bone Joint Surg Am*. 1996 Nov 1; 78(11):1632-45.
  9. Matta JM. Fractures of the acetabulum: accuracy of reduction and clinical results in patients managed operatively within three weeks after the injury. *J Bone Joint Surg Am*. 1996 Nov 1;78(11):1632-45.
  10. Moed BR, Paul HY, Gruson KI. Functional outcomes of acetabular fractures. *J Bone Joint Surg Am*. 2003 Oct 1; 85(10):1879-83.
  11. Murphy D, Kalisz M, Rice J, McElwain JP. Outcome after acetabular fracture: prognostic factors and their inter-relationships. *Injury*. 2003 Jul 31; 34(7):512-7.
  12. Green DP. Rockwood and Green's fractures in adults. Rockwood CA, Bucholz RW, Heckman JD, Tornetta P, editors. Lippincott Williams & Wilkins; 2010.
  13. Guyton JL, Perez EA. Fractures of acetabulum and pelvis. *Campbell's Operative Orthopedics*. 10th ed. St Louis, Mo: Mosby. 2003:2939-84.
  14. Amaravati RS, Phaneesha MS, Rajagopal HP, Reddy R. Treatment of acetabular fractures. *Indian Journal of Orthopaedics*. 2005 Jan 1;39(1):26.
  15. Moore KD, Goss K, Anglen JO. Indomethacin versus radiation therapy for prophylaxis against heterotopic ossification in acetabular fractures. *Bone & Joint Journal*. 1998 Mar 1; 80(2):259-63.
  16. Olson SA. Diagnosis and Treatment of Acetabular Fractures: Historic Review. *Fractures of the Pelvis and Acetabulum*. 2007 Jun 12:127.
  17. Heeg M, Oostvogel HJ, Klasen HJ. Conservative treatment of acetabular fractures: the role of the weight-bearing dome and anatomic reduction in the ultimate results. *Journal of Trauma and Acute Care Surgery*. 1987 May 1; 27(5):555-9.
  18. Kreder HJ, Rozen N, Borkhoff CM, Laflamme YG, McKee MD, Schemitsch EH, Stephen DJ. Determinants of functional outcome after simple and complex acetabular fractures involving the posterior wall. *Bone & Joint Journal*. 2006 Jun 1; 88(6):776-82.
  19. Giannoudis PV, Grotz MR, Papakostidis C, Dinopoulos H. Operative treatment of displaced fractures of the acetabulum. *Bone & Joint Journal*. 2005 Jan 1; 87(1):2-9.