

Original Research Article

## **Is Bone Grafting necessary following open reduction and internal fixation of supracondylar/intercondylar femur fracture with locking compression plate?**

**Dr. J. Alphonse Mariadoss<sup>1</sup>, Dr. Anil Gowtham Manivannan<sup>2</sup>, Dr. Sathya Vijayan<sup>3</sup>, Dr. Sakthivel Annamalai<sup>4</sup>**

<sup>1</sup>Professor of Orthopaedics, <sup>2</sup>Senior Registrar of Orthopaedics, <sup>3</sup>Senior Resident, <sup>4</sup>Professor and Head

Department of Orthopaedics

K.G. Hospital and post graduate medical institute, Coimbatore, India.

### **\*Corresponding author**

Dr. Anil Gowtham Manivannan

Email: [anilthambu91@yahoo.com](mailto:anilthambu91@yahoo.com)

---

**Abstract:** The common problems seen in distal femoral fractures are comminution, articular surface involvement, fractures in multiple planes and bone loss in compound fractures. They present a challenge to the surgeon to achieve stable fixation and union. With different methods of internal fixation available, the common complications encountered with distal femoral fractures are malunion, varus collapse, delayed union, implant failure and shortening of the limb etc. This necessitates the option of primary bone grafting in treating such fractures. Here, we are presenting our results of 38 cases of distal femoral fractures treated with locking compression plates without primary bone grafting. The functional outcome was excellent in 18 cases and good in 16 cases as per Neer's rating system. We obtained union in all cases without any primary bone grafting.

**Keywords:** Distal femur fractures, Bone grafting, locking compression plate, Fracture union.

---

### **INTRODUCTION:**

Distal femoral fractures constitute a challenge to the operating surgeon because of the difficulties encountered due to comminution, displacement of the fragments, fractures in multiple planes, involvement of the articular surface etc. There are various methods available with which these fractures can be treated namely retro grade nailing, blade plate, dynamic condylar screw, condylar buttress plate and locking compression plate and screws. There is an on-going debate whether primary bone grafting should be done in comminuted distal femoral fractures to prevent complications like non-union, varus collapse and malunion, when these fractures are treated with locking compression plates. We are presenting our results of distal femoral fractures treated with locking compression plates in 38 patients where primary bone grafting was not done. Our results show that routine primary bone grafting is not necessary when locking compression plates were used.

### **MATERIAL AND METHODS:**

From June 2010 to December 2012, 38 patients with fractures of distal femur, treated with open reduction and internal fixation with locking compression plate at our hospital are included in this study, where no primary bone grafting was done. In patients admitted to our hospital with distal femur

fractures, history regarding mode of injury, physical examination, imaging (Antero posterior and lateral radiographs of femur and knee), CT scan for multi-fragmentary fractures with intra-articular extension were done. The fractures were classified according to AO classification. All the patients were treated with locking compression plates. All cases were available for follow up at regular intervals, once monthly up to 3 months, once in 3 months for next 6 months and once in six months thereafter. Neer's scoring system was used to evaluate the functional outcome.

### **PROCEDURE:**

All the patients were operated by the same set of two orthopaedic trauma surgeons. The patient is put on a radiolucent table with a sand bag under the ipsilateral hip. Through lateral approach, the fractures site exposed. The main medial and lateral femoral condyles are reduced and fixed with k wires first and then with 6.5 mm cancellous screws. Articular fragments are fixed with 3.5 mm/4 mm cancellous screws wherever required. Any Hoffa fragment if present, is then fixed with either 6.5 mm or 4 mm cancellous screws. The supra condylar element of the fracture is then reduced and fixed with an appropriate length locking compression plate and screws. The whole procedure is monitored under image intensifier.

The stability of the fracture fixation is then tested and if stable, wound is closed with drains.

**RESULTS:**

The study population (n = 38) comprised of 27 males and 11 females of varying age groups (Table 1). Most of the individuals were found to be young in their third and fourth decade of life (Table 2). The mean age was 42.86 years. All the 38 patients were grouped under AO/OTA classification (Table 3). Type A3 (6 cases), type C1 (7 cases), type C2 (10 cases) and type C3 (15 cases). The common mode of injury is road traffic accidents following high velocity trauma (84%) and fall from height (16%). Out of these, 4 cases had grade III A open fractures and 2 cases presented with grade III B open fractures with bone loss. In our study, 15 cases (type C3) had severe comminution which includes the two grade III B open fractures. We followed Neer's scoring system for functional evaluation which gives equal importance to subjective (pain, disability), clinical

(shortening, knee flexion) and radiological (angulation) features. The average mean duration for fracture healing took 14 weeks. The functional outcome of fixation was graded with Neer's rating system at 12<sup>th</sup> week. 18 cases had excellent and 16 cases had good outcome (Table 4). The mean range of knee motion was 70° - 130°. The mean Neer's score was 15.15 and was found to be statistically significant (p < 0.005). Good outcome in 16 cases was attributed to moderate knee motion. Fair outcome in 2 cases was due to poor knee motion due to non-compliance of patients and limb shortening. Failure in 2 cases in our series was due to infection and angulations. Two cases that were compound which had deep infection and required repeated debridement and irrigation, ultimately ended in delayed union (failure). Two cases had varus collapse with 2cm and 3cm limb shortening each. Though they had a poor (5%) clinical outcome, with orthotic footwear modification they were able to carry out activities of daily living.

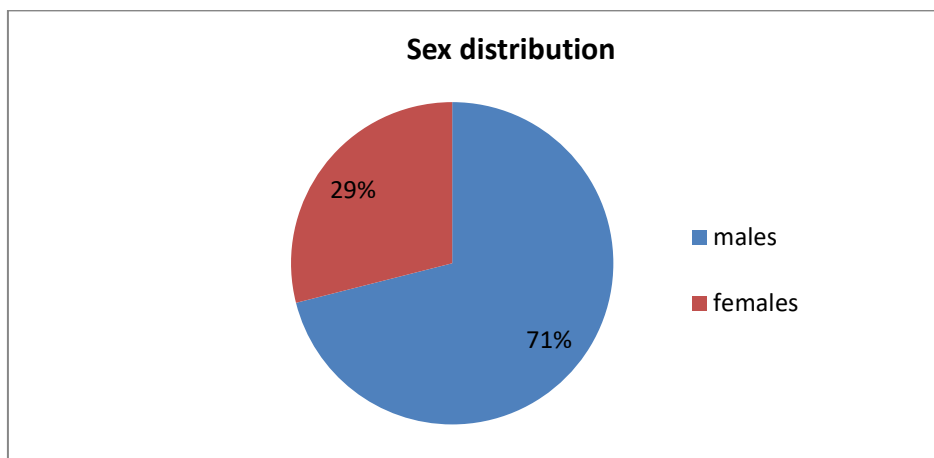


Fig-1: Sex distribution

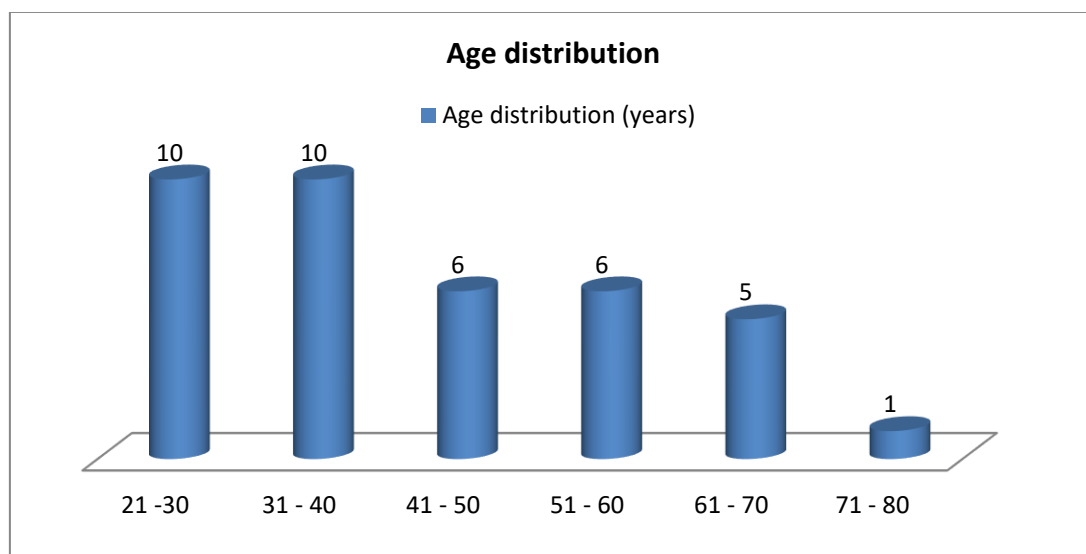


Fig-2: Age distribution

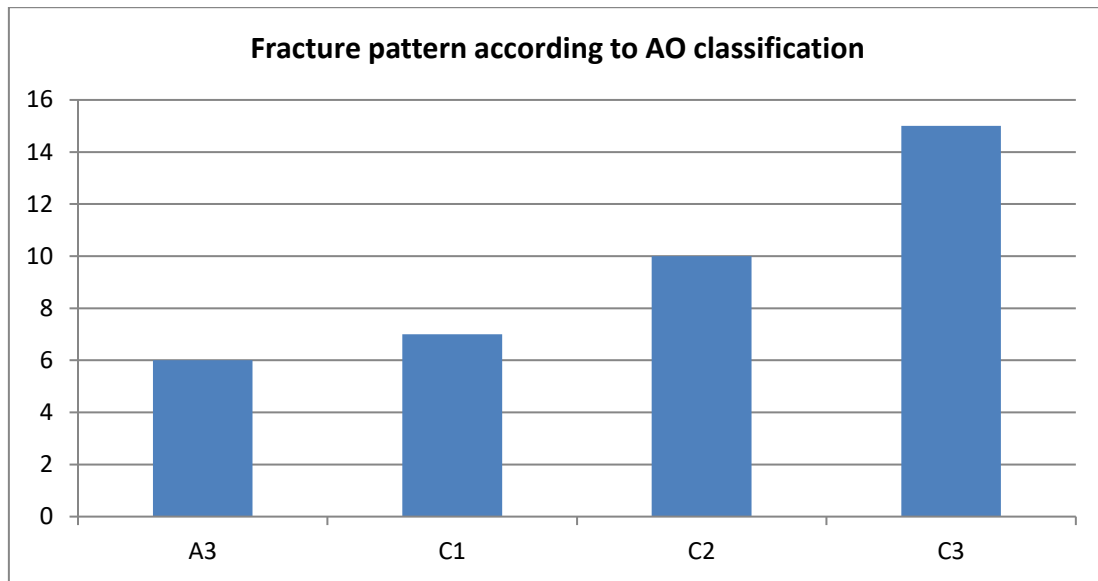


Fig-3: Fracture pattern according to AO classification

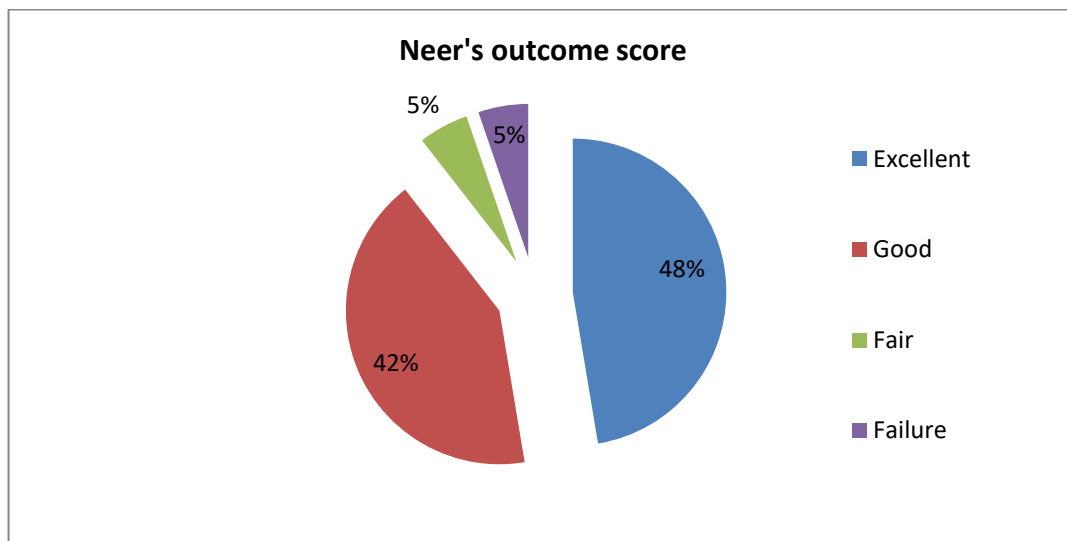


Fig-4: Neer's outcome score

**DISCUSSION:**

The aim of this study is to assess whether primary bone grafting is needed routinely to obtain union in fractures of distal femur managed with locking compression plate. In a study by Schandelmaier *et al.*; [1], patients were treated with locking compression plate for distal femoral fractures, out of 54 fractures, 6 patients had bone grafting and mean range of movements is 104°. Most of the fractures were type C and 78% of patients had good functional results by Neer's knee score. 13 patients had malalignment. Siliski [2] in 1989 evaluated 52 intercondylar femoral fractures (AO type C) treated with 95° condylar blade plate, condylar buttress plates, T-plates and straight plates. Cancellous bone graft was used. Average time of

healing was 13.6 weeks. Seven fractures healed in 4° to 8° of varus-valgus malalignment and three fractures healed in 5° to 10° of recurvatum. Shortening of 1 to 3 cm occurred in 15 patients. The average eventual arc of motion of the knee was 107 degrees, with an average knee motion being 113° for C1 fractures and 99° for C3 fractures. Overall C1 fractures resulted in good or excellent outcome in 92% of cases, whereas C2 and C3 fractures resulted in 77% excellent or good result.

Chapman MW *et al.*; [3] states that rigid plate fixation and autologous bone-grafting is an effective technique for the treatment of non-union of the supracondylar region of the femur but not for primary fracture fixation. Nayak *et al.*; [4] support the use of

LCP locking plates for extra-articular fractures, reporting union in all cases, good recovery of alignment and high quality function. An autologous graft was not necessary with the mini-invasive technique, postoperative pain was reduced and the rate of union was high. Kolb *et al.*; [5] confirmed these results in a retrospective series of 50 fractures. Functional recovery was found to be very good with 80% of good and very good results. They concluded that the locking plate system allows early mobility, rapid functional recovery and good radiological results with low morbidity, even though these were intra-articular fractures.

Ostrum *et al.*; [6] treated thirty supra condylar/intercondylar fractures of the distal femur using an indirect reduction technique, and fixation with a distal lateral plate without stripping of the medial soft tissues and without bone graft. With this technique, 86.6% excellent satisfactory results were achieved using the Neer's rating system. Bolhofner *et al.*; [7] reported the results of 57 Type A and Type C fractures of distal femur, using biologic reduction technique, without bone grafting. They assessed the outcomes using a modified schatzker scoring system and reported 84% good to excellent results. They achieved union in an average time of 10.7 weeks.

Barei DP *et al.*; [8] stated, despite metaphyseal bone loss, locking plates obviate the need for routine bone grafting of some open distal femur fractures and that those with radiographic posterior cortical contact are strongly correlated with primary union. They hypothesized that locking plates maintain alignment and decrease the need for subsequent bone grafting and that immediate post fixation radiographic features predict primary union. Wanq JW *et al.*; [9] treated 13 cases of established non-union of distal femur fracture which showed complete healing with an average of about five months. They concluded that Open reduction and internal fixation supplemented with allograft struts and autogenous bone graft is an effective treatment for non-union of the distal part of the femur but not for primary fixation. Kregor *et al.*; [10] in his large case series of 123 distal femur fractures concluded that treatment of

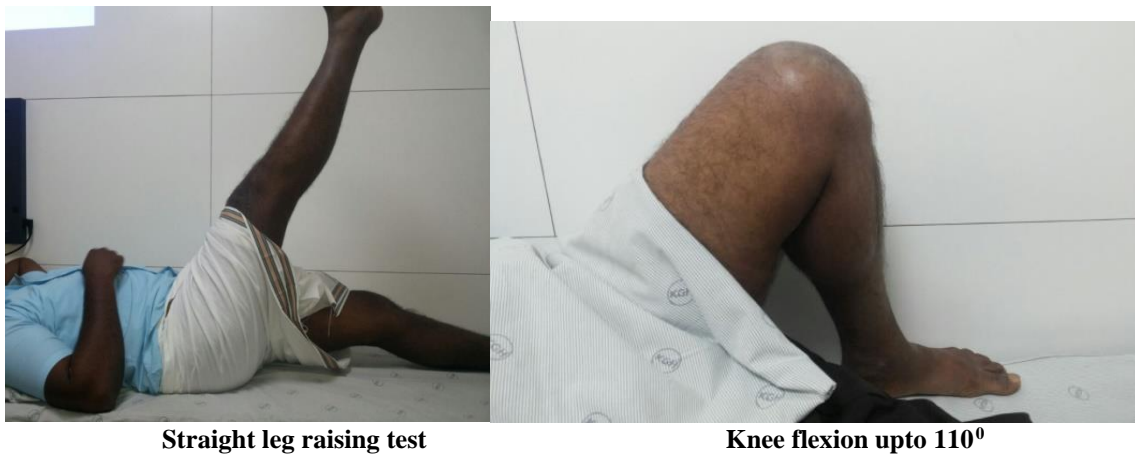
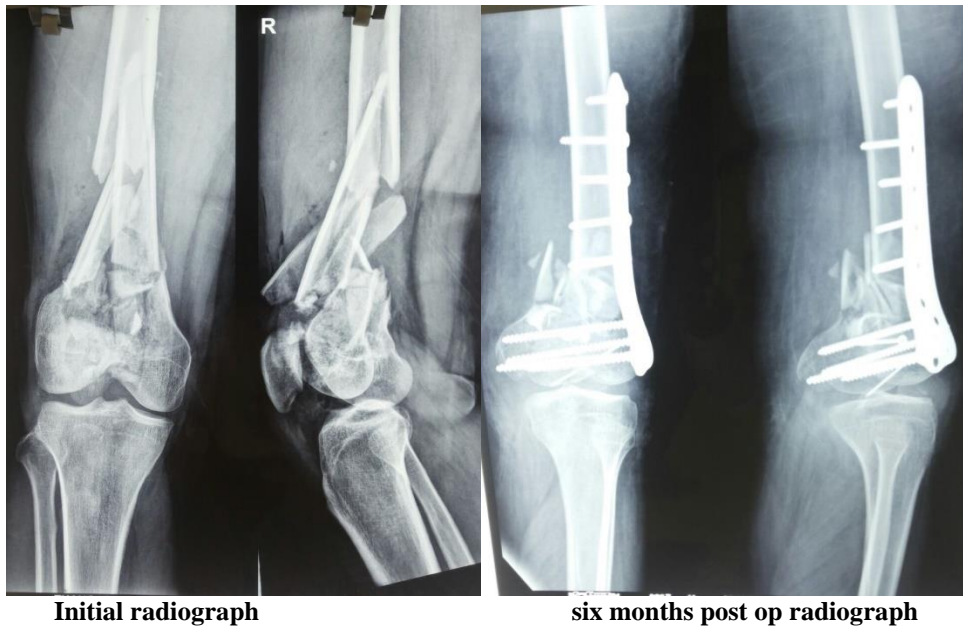
distal femur fractures with the LISS is associated with high union rates without autogenous bone grafting (93%), a low incidence of infection (3%), and maintenance of distal femoral fixation (100%). Iannacone *et al.*; [11] treated 41 distal femur fractures with supracondylar intramedullary nail without any primary bone grafting, out of which 22 were open and 19 were closed fractures. Except 4 cases which required revision internal fixation and bone grafting, all other cases healed with a mean range of motion of 90°.

Schiitzl and Müller [12] described that minimally invasive stabilisation system for distal femur fractures in difficult case scenarios with conservation of intact soft tissue and fragment vascularity does not require any primary cancellous bone grafting. It promotes union in almost all distal intra-articular multi fragmentary fractures of the femur and peri prosthetic fractures. Syed and Giannoudis *et al.*; [13] studied 29 patients with distal femoral fractures stabilised using the less invasive stabilisation system. All of the acute cases united without the need for bone grafting. The average time for union in 22 cases was 3.5 months (range 2 - 5 months), the rest seven cases required multiple limb salvage procedures.

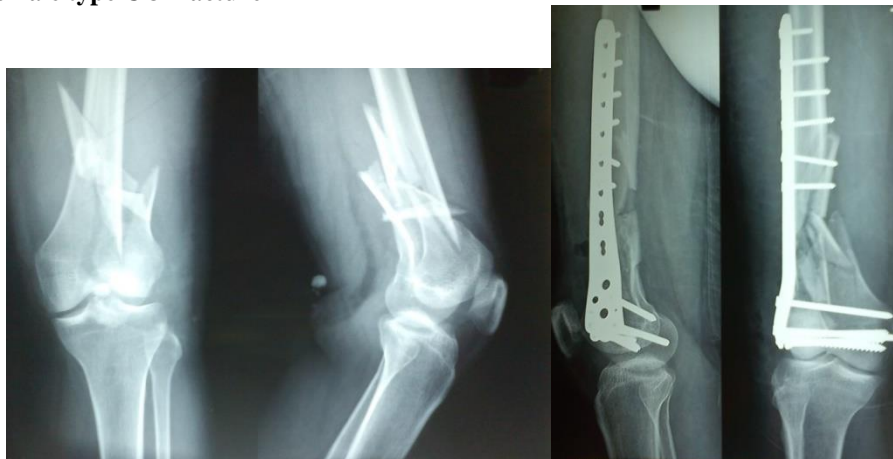The management of distal femoral fractures has progressed from internal fixation with angled blade plate, dynamic condylar screw, condylar buttress plate and locking compression plate with better results with each new method. Most of the comminuted type C fractures treated with the earlier methods required primary or secondary bone grafting to obtain union without loss of fixation, and to prevent varus collapse, malunion, non-union and implant failure. The use of locking compression plate because of the structural stability provided by the fixed angle screws configuration maintains alignment until fracture healing and obviates the need for primary bone grafting. The meticulous surgical technique with minimal soft tissue handling preserving soft tissue attachments of the fracture fragments helps in preservation of blood supply to the fragments thus enhancing union.

Case capsules:

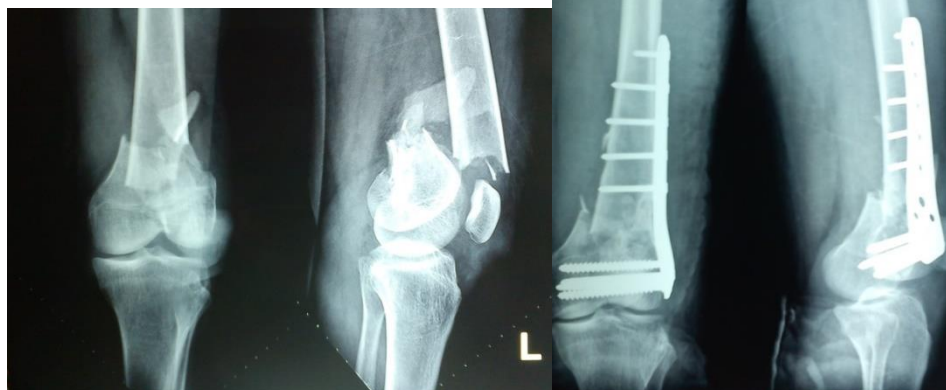Case 1: 33 year male with type C 3 distal femur fracture



Case 2: 33 year female type C 3 fracture



Case 3: 40 year female with type C 3 fracture



**CONCLUSION:**

In our series of 38 cases of distal femoral fractures, treated by a locking compression plate, we have not done primary bone grafting in any of the cases. We have achieved union in all 38 cases. Two cases of delayed union which are Type C3, Grade III B distal femoral fractures required secondary bone grafting. But the patients were not willing for any further surgical intervention and were more satisfied with conservative care. Our results show that routine bone grafting as a primary procedure was not required for obtaining union when distal femoral fractures were treated by locking compression plate. The availability of locking compression plate has helped the surgeon to achieve consistently good results with better range of motion and function of knee. Treatment of type III C distal femoral fractures is a technically demanding procedure which tests the experience and skill of the operating surgeon. Because of the good results obtained by using the locking compression plate, in the treatment of distal femoral fractures, we conclude that routine primary bone grafting is not necessary in the management of distal femoral fractures.

**REFERENCES:**

1. Krettek C, Schandelmaier P, Miclau T, Bertram R, Holmes W, Tschern H. Transarticular joint reconstruction and indirect plate osteosynthesis for complex distal supracondylar femoral fractures. *Injury*. 1997 Jan 1; 28:A31-41.
2. Siliski JM, Mahring MA, Hofer HP. Supracondylar-intercondylar fractures of the femur. Treatment by internal fixation. *J Bone Joint Surg Am*. 1989 Jan 1; 71(1):95-104.
3. Chapman MW, Finkemeier CG. Treatment of supracondylar nonunions of the femur with plate fixation and bone graft. *The Journal of Bone & Joint Surgery*. 1999 Sep 1; 81(9):1217-28.
4. Nayak RM, Koichade RM, Umre AN, Ingle MV. Minimally invasive plate osteosynthesis using a locking compression plate for distal femoral fractures. *Journal of Orthopaedic Surgery*. 2011 Aug; 19(2):185-90.
5. Kolb W, Guhlmann H, Windisch C, Marx F, Kolb K, Koller H. Fixation of distal femoral fractures with the Less Invasive Stabilization System: a minimally invasive treatment with locked fixed-angle screws. *Journal of Trauma and Acute Care Surgery*. 2008 Dec 1; 65(6):1425-34.
6. Ostrum RF, Geel C. Indirect reduction and internal fixation of supracondylar femur fractures without bone graft. *Journal of orthopaedic trauma*. 1995 Aug 1; 9(4):278-84.
7. Bolhofner BR, Carmen B, Clifford P. The results of open reduction and internal fixation of distal femur fractures using a biologic (indirect) reduction technique. *Journal of orthopaedic trauma*. 1996 Aug 1; 10(6):372-7.
8. Barei DP, Beingessner DM. Open distal femur fractures treated with lateral locked implants: union, secondary bone grafting, and predictive parameters. *Orthopedics*. 2012 Jun 1; 35(6):e843-6.
9. Wang JW, Weng LH. Treatment of distal femoral nonunion with internal fixation, cortical allograft struts, and autogenous bone-grafting. *J Bone Joint Surg Am*. 2003 Mar 1; 85(3):436-40.
10. Kregor PJ, Stannard JA, Zlowodzki M, Cole PA. Treatment of distal femur fractures using the less invasive stabilization system: surgical experience and early clinical results in 103 fractures. *Journal of orthopaedic trauma*. 2004 Sep 1; 18(8):509-20.
11. Iannacone WM, Bennett FS, DeLong Jr WG, Born CT, Dalsey RM. Initial experience with the treatment of supracondylar femoral fractures using the supracondylar intramedullary nail: a preliminary report. *Journal of orthopaedic trauma*. 1994 Aug 1; 8(4):322-7.

12. Schuetz M, Müller M, Krettek C, Höntzsch D, Regazzoni P, Ganz R, Haas N. Minimally invasive fracture stabilization of distal femoral fractures with the LISS: A prospective multicenter study results of a clinical study with special emphasis on difficult cases. *Injury*. 2001 Dec 1; 32:48-54.
13. Syed AA, Agarwal M, Giannoudis PV, Matthews SJ, Smith RM. Distal femoral fractures: long-term outcome following stabilisation with the LISS. *Injury*. 2004 Jun 30; 35(6):599-607.