

## Outcome of Single Level Instrumented Posterior Lumbar Interbody Fusion (PLIF) Using Corticocancellous Bone Chips and Cages in Spondylolisthesis

Mohammed Mohsin Reza<sup>1\*</sup>, Abdullah Al Mamun Choudhury<sup>2</sup>, Md. Hossain Rasel<sup>1</sup>, Abul Kalam Azad<sup>3</sup>, Humayun Kabir Reza<sup>4</sup>

<sup>1</sup>Assistant Registrar (Ortho), National Institute of Traumatology & Orthopaedic Rehabilitation (NITOR), Sher E Bangla Nagar, Dhaka-1207, Bangladesh

<sup>2</sup>Medical Officer (Ortho), National Institute of Traumatology & Orthopaedic Rehabilitation (NITOR), Sher E Bangla Nagar, Dhaka-1207, Bangladesh

<sup>3</sup>Junior Consultant (Ortho), 250 Bed General Hospital, Netrokona, Bangladesh

<sup>4</sup>Medical Officer, OSD, Directorate General of Health Services (DGHS), Dhaka, Bangladesh

DOI: [10.36347/sjams.2020.v08i01.001](https://doi.org/10.36347/sjams.2020.v08i01.001)

| Received: 09.12.2019 | Accepted: 22.12.2019 | Published: 08.01.2020

\*Corresponding author: Mohammed Mohsin Reza

### Abstract

### Original Research Article

**Background:** A Posterior Lumbar Interbody Fusion (PLIF) procedure allows the surgeon to insert bone graft and cage into the disc space from a unilateral approach. PLIF fuses the anterior (front) and posterior (back) columns of the spine through a single posterior approach. By using cage, restoration of disc height and indirectly foraminal height can occur. Pedicle screws and rods give immediate stability. **Objective:** To determine the clinical outcomes of posterior lumbar interbody fusion (PLIF) using cage combined with decompression and stabilization of lumbar spine for spondylolisthesis. **Methods:** This prospective observational study was conducted in the National Institute of Traumatology Orthopedic and Rehabilitation from July 2015 to June 2017. All spondylolisthetic patients of both sexes age above 18 years were included in this study. A total number of 20 patients were enrolled as per inclusion and exclusion criteria. Diagnosis of spondylolisthesis and instability was made by history, clinical examination and X-ray. Magnetic resonance imaging (MRI) of the lumbosacral spine was done routinely to delineate the intra-spinal pathoanatomy. Surgery was done by posterior lumbar interbody fusion using cage, bone graft and stabilization by pedicle screws and rods. Preoperative and postoperative pain status was recorded by self-evaluated Visual Analog Score (VAS) and disability by Oswestry Disability Index (ODI). **Results:** Total number of patients were 20 where male was 5(25.0%) and female found 15(75.0%) and mean age group was 43.8±9.7 years. Twelve patients (60%) had spondylolisthesis at L4/L5 level and 8(40%) patients had at L5/S1 level. Regarding clinical assessment, the ODI percentage has been decreased from 58.2±1.6 to 18.2±4, VAS for back pain has come down from 7.0±0.46 to 2.25±0.55 and VAS for leg pain has come down from 6.6±0.51 to 1.3±0.46 six months after surgery. According to Macnab criteria the overall functional outcome was, 18(90%) found excellent and only 2(10%) found good. Regarding radiological variables of the of the study patients, pre-operatively, mean slip angle was found 15.1±1.2 degree, total lumbar angle 21.0±3.0 degree and mean measurement of slip 31.4%±2.3%. Six months after surgery, mean slip angle 7.6±1.1 degree, total lumbar angle 21.0±3.0 degree and mean measurement of slip was 12.7%±1.0%. There was significant increase in disc space height and foraminal height post-operatively (p value< 0.05). Fusion rate was 100% according to Hackenberg criteria. **Conclusion:** This study permits to conclude that spondylolisthesis lumbar spine can be treated with posterior lumbar interbody fusion and spinal stabilization. This method enhances neurological recovery, reduce pain and improve working status with early rehabilitation.

**Keywords:** Spondylolisthesis, surgery outcome, Surgical Anatomy, pre-operative level.

**Copyright © 2020:** This is an open-access article distributed under the terms of the Creative Commons Attribution license which permits unrestricted use, distribution, and reproduction in any medium for non-commercial use (NonCommercial, or CC-BY-NC) provided the original author and source are credited.

## INTRODUCTION

Herbiniaux, a Belgian obstetrician, noted a bony prominence in front of sacrum that caused problems in delivery generally is credited with having first described Spondylolisthesis. The term spondylolisthesis was used by Kilian in 1854 is derived

from Greek spondylos, meaning 'vertebra' and olisthenein meaning 'to slip'. Spondylolisthesis is defined as anterior or posterior slipping of one segment of spine on the next lower segment [1]. In 1989, Wiltse and Rothman separated the post-surgical type from the pathologic type producing 6 different classifications that is congenital, isthmic, degenerative, traumatic,

pathologic and post-surgical, which is the common form used today [2, 3]. Compression of spinal nerve roots by lumbar spinal stenosis (LSS) in spondylolisthesis is a major clinical problem associated with intermittent claudication, pain, numbness, and lack of normal sensitivity. Such compression has been shown to induce neurophysiologic dysfunction, degeneration, and reduced blood flow in nerve roots in animal models and human as well. Reduced blood flow in nerve roots induces neurogenic intermittent claudication [4]. The prevalence of spondylolisthesis and spondylolysis in general population is 6% [5]. Controlled clinical studies comparing conservative and surgical treatment are rare and there are few reports on long-term results. The outcome of those studies favors surgical management over conservative treatment [4]. The most widely used surgical techniques are all based on the principles of decompression and fusion, with or without instrumentation [10]. Lumbar spinal fusion has been established as an effective treatment modality for proper patients with low back and leg pain suffering from degenerative lumbar spinal disorder. Numerous efforts have been undertaken to fulfill the aim of spinal fusion procedure, which is a solid arthrodesis of unstable segment finally relieving patients from pain and restoring their global spinal function. Among various techniques introduced so far, posterior lumbar interbody fusion (PLIF) with instrumentation is considered as one of most solid and biomechanically sound methods for fusion [11]. Several procedures have been described for interbody fusion with or without instrumentation: posterior lumbar interbody fusion (PLIF), anterior lumbar interbody fusion (ALIF), circumferential 360° fusion (front and back) and more recently, the transforaminal lumbar interbody fusion (TLIF) [9]. A posterior lumbar interbody fusion (PLIF) has the advantages of spinal canal decompression, anterior column reconstruction, decompression of foraminal stenosis, and reduction of the sagittal slips from a single posterior approach. The PLIF using double cage has been a standard practice till recently. However, there are many studies now with PLIF using single cages with comparable results and lesser complications [12]. Degenerative spondylolisthesis is a common condition which occurs most frequently in the lower lumbar spine, most commonly at the level of L4/L5. The extent of the slip is usually graded using the Meyerding classification with grades I and II representing upto 25% and 50% displacement respectively. These are referred to as low-grade slips. The initial management of the condition is non-operative. However, should this fail surgical intervention is then considered. Posterolateral Fusion (PLF) and Posterior Lumbar Interbody Fusion (PLIF) are procedures that can be undertaken for the surgical management of degenerative low grade spondylolisthesis. With additional instrumentation and posterolateral fusion, the overall fusion rate has been high, ranging from 96% to 100%, and the clinical success has been satisfactory as reported in the

literature. In practice, several kinds of bone grafts have been used for interbody fusion. Aim of the presented study was to evaluate whether the PLIF with cage and instrumentation is effective regarding clinical and functional outcome, fusion rate, structural restoration and complications in treatment of spondylolisthesis. A review by [6], suggested that the indications for surgical treatment are; persistent or recurrent back and/or leg pain or neurogenic claudication, with significant reduction of quality of life, despite a reasonable trial of non-operative treatment (a minimum of 3 months); progressive neurological deficit and bladder or bowel symptoms and symptomatic instability (1998). Did an experimental clinical study of angulatory and translational lumbar spine intervertebral motion using flexion-extension radiographs obtained the lateral plane [7]. These "bending" films were obtained from 59 asymptomatic individuals undergoing routine pre-employment examination. Results indicate that there is 7 to 10 degrees of angulatory motion present in the lumbar spine but a large range of values exist so that norms of angulatory motion cannot be more precisely defined. There is 2 to 3 mm of translational motion present in the lumbar spine at each intervertebral level (1989). Showed a translation greater than 3 mm and angular motion beyond 10° were defined as being unstable, which required surgical treatment (2013) [3]. Conducted a study on a total of 72 patients who underwent posterior lumbar interbody fusion (PLIF) for the management of spondylolisthesis [8]. The first is the method of Meyerding. The anteroposterior (AP) diameter of the superior surface of the lower vertebral body is divided into quarters and a grade of I–IV is assigned to slips of one, two, three or four quarters of the superior vertebra, respectively [14]. The second method, first described by Tailard expresses the degree of slip as a percentage of the AP diameter of the top of the lower vertebra Tailard [15]. Method of measuring slip grading in lateral view x-ray (1977). Shown in a retrospective study from one-hundred forty patients lumbar interbody fusion with metallic cages, resulted in a statistically significant ( $p < 0.01$ ) improvement in foraminal dimensions postoperatively [16, 17], have described the technique of measurement of foraminal height pre-operatively and post-operatively in a degenerative disc disease patient (2015). Showed, for studies of patients with low back problems, the Oswestry Disability Index (ODI) may be a sufficient measure of health status and patient function, without the need for additional condition-specific instruments [18].

## OBJECTIVES

### A. General Objective

1. To determine the clinical outcomes of posterior lumbar interbody fusion (PLIF) using cage combined with decompression and stabilization of lumbar spine for spondylolisthesis.

**B. Specific Objectives**

1. To determine the frequency of postoperative back pain in patients of spondylolisthesis.
2. To find out the functional outcome of surgery.
3. To assess the recovery rate from disability.
4. To find out operative complication (per-operative and post-operative).

**METHODS**

This prospective observational study was conducted in the National Institute of Traumatology Orthopedic and Rehabilitation from July 2015 to June 2017. All spondylolisthetic patients of both sexes age above 18 years were included in this study. A total number of 20 patients were enrolled as per inclusion and exclusion criteria. Diagnosis of spondylolisthesis and instability was made by history, clinical examination and X-ray. Magnetic resonance imaging (MRI) of the lumbosacral spine was done routinely to delineate the intra-spinal pathoanatomy. Surgery was done by posterior lumbar interbody fusion using cage, bone graft and stabilization by pedicle screws and rods. Preoperative and postoperative pain status was recorded by self-evaluated Visual Analog Score (VAS) and disability by Oswestry Disability Index (ODI). Radiologically preoperative and post-operative disc height, foraminal height, angle of total lumbar lordosis and slip reduction, preoperative pelvic parameters (Pelvic tilt, pelvic incidence and sacral slope) were measured in standing lateral films. Hackenberg criteria were used for assessment of bony fusion. The overall functional outcome was assessed by Macnab's criteria.

**Analytic Frame Work**

Data was processed and analyzed using computer software program Microsoft Excel 2010. The data present on categorical scale was expressed as frequency and corresponding percentage, while the quantitative data was presented as mean and standard deviation (SD). Comparison between preoperative and postoperative data was done. Post-operative final outcome was evaluated using student t-test. For all analyses level of significance will be set at 0.05 and p-value <0.05 was considered significant.

**RESULTS**

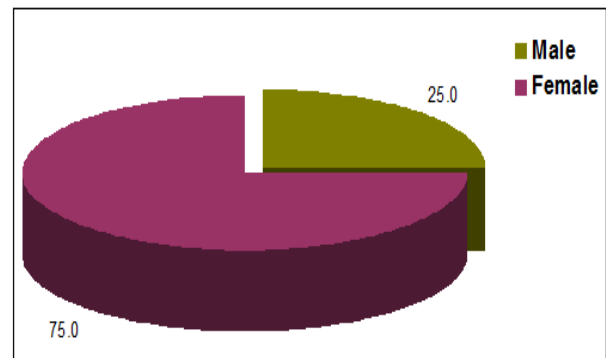
Total number of patients were 20 where male was 5(25.0%) and female found 15(75.0%) and mean age group was 43.8±9.7 years (Table-1). Twelve patients (60%) had spondylolisthesis at L4/L5 level and 8(40%) patients had at L5/S1 level. Regarding clinical assessment, the ODI percentage has been decreased from 58.2±1.6 to 18.2±.4, VAS for back pain has come down from 7.0±0.46 to 2.25±0.55 and VAS for leg pain

has come down from 6.6±0.51 to 1.3±0.46 six months after surgery.

**Table-1: Distribution of patients according to Age (n=20)**

Age	Number	Percentage
30-34	3	15.0
35-39	4	20.0
40-44	2	10.0
45-49	6	30.0
> 50	5	35.0
Total	20	100.0
Mean age= (43.8±9.7) years; range= (30-65) years		

Out of 20 patients, 3(15.0%) was 30-34 years old, 4(20.0%) was 35-39 years old, 2(10.0%) was 40-44 years old, 6(30.0%) was 45-49 years old and 5(25.0%) was above 50 years. The mean age was 43.8±9.7 years and the lowest and highest ages were 30 and 65 years respectively.



**Fig-1: Distribution of patients according to sex (n=20)**

Shows in regarding the sex distribution of the study patients, male was found in 5(25.0%) cases and female was found in 15(75.0%) cases (Figure-1).

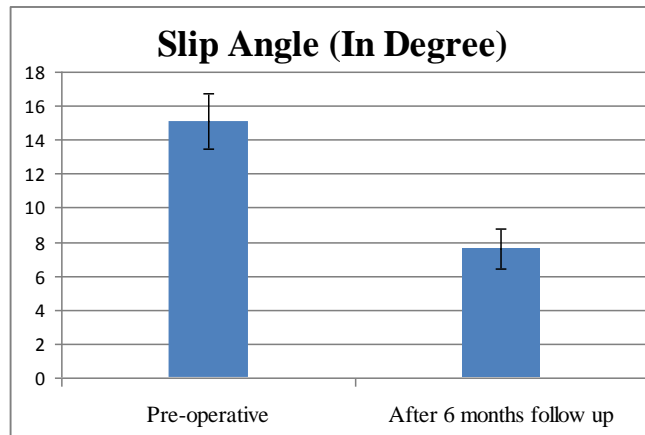
**Table-2: Distribution of patients according to level of spondylolisthesis (n=20)**

Level of spondylolisthesis	Number	Percentage (%)
L4/L5	12	60.0
L5/S1	8	40.0
Total	20	100.0

Regarding the pre-operative level of spondylolisthesis grading of the study patients 12(60.0%) patients were found at L4/L5 and 8(40.0%) patients found spondylolisthesis level at L5/S1 (Table-2).

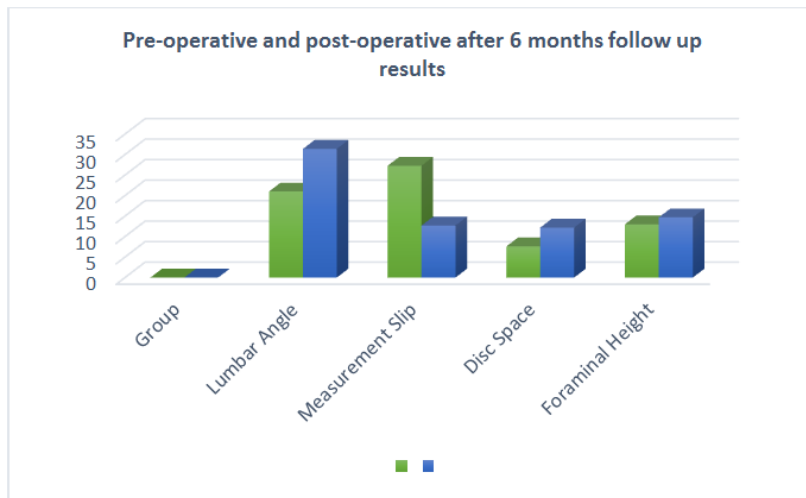
**Table-3: Radiological variables of all study samples (n=20)**

Sl. No	Slip Angle (Degree)		Total Lumbar Angle (Degree)		Measurement of slip %		Disc Space Height mm		Foraminal Height mm		Fusion
	Pre	Post	Pre	Post	Pre	Post	Pre	Post	Pre	Post	
Mean	15.1	7.6	21.0	31.4	27.3	12.7	7.6	12.2	13.0	14.7	Fused
SD	1.6	1.2	3.0	2.3	1.9	1.0	1.1	1.7	0.8	0.93	
P value	<0.001*		<0.001*		<0.001*		<0.001*		<0.001*		



**Fig-2: Results of slip angle (in degree) pre-operatively and 6 months after surgery (n=20)**

Slip angle of the patients pre-operatively was 15.1±1.6. Six months after operation, it came down to 7.6±1.2 degree. P value is <0.05 (Table-3 & Figure-2).



**Fig-3: Lumbar angle, Slip, disc space height and Foraminal height pre-operatively and post-operative after 6 months follow up (n=20)**

After six months follow up, the total lumbar angle in degree increased from 21.0<sup>0</sup>±3.0<sup>0</sup> to 31.4<sup>0</sup>±2.3<sup>0</sup>. Slip percentage of the patients pre-operatively was 27.3±1.9%. Six months after operation, it came down to 12.7±1.0%. Here, p value is <0.05. Mean disc space

height of the patients pre-operatively was 07.6±1.1mm. Six months after operation, it increased to 12.2±1.7mm. Foraminal height of the patients pre-operatively was 13.0±0.8mm. Six months after operation, it increased to 14.7±0.93mm (Figure-3).

**Table-4: Pelvic parameters of all study samples (n=20)**

Sl. No	Pelvic Incidence (PI)		Sacral slope (SS)		Pelvic tilt (PT)	
	Pre	Post	Pre	Post	Pre	Post
Mean	69.6	47.5	53.3	40.5	16.6	11.6
SD	7.3	5.7	5.2	2.5	3.3	1.3
p value	<0.001*		<0.001*		<0.001*	

Evaluating the pre-operative and post-operative (6 months after operation) mean pelvic incidence (PI) has come down from  $69.6 \pm 7.3$  to  $47.5 \pm 5.7$ . Here, the P value is  $<0.05$ . Evaluating the pre-operative and post-operative (6 months after operation) mean sacral slope (SS) has come down from

$53.3 \pm 5.2$  to  $40.5 \pm 2.5$ . Here, the P value is  $<0.05$ . Evaluating the pre-operative and post-operative (6 months after operation) mean Pelvic tilt (PT) has come down from  $16.6 \pm 3.3$  to  $11.6 \pm 1.3$ . Here, the P value is  $<0.05$  (Figure-4 & Table-4).

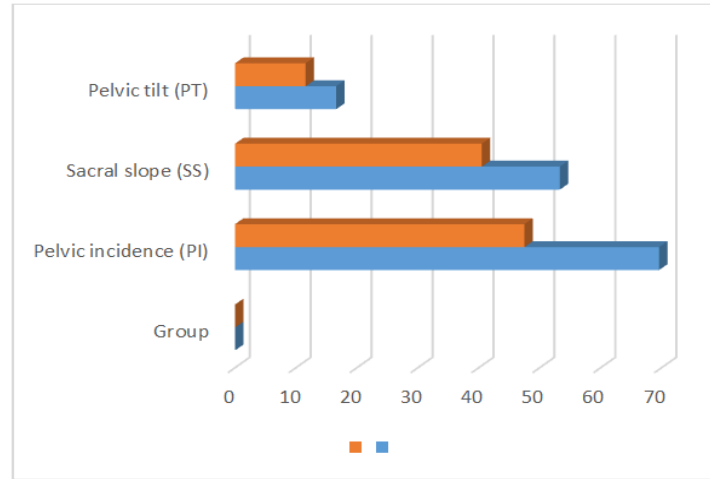


Fig-4: Evaluating the pre-operative and post-operative (6 months after operation) mean pelvic incidence (PI), sacral slope (SS) and Pelvic tilt (PT) after 6 months surgery (n=20)

Table-5: Clinical Variables of all study samples (n=20)

Sl. No	Visual Analog Score Back Pain		Visual Analog Score Leg Pain		Oswestry Disability Index (ODI)	
	Pre	Post	Pre	Post	Pre	Post
Mean	7.0	2.25	6.6	1.3	58.2	18.2
SD	0.46	0.55	0.51	0.47	1.6	4.4
P value	$<0.001^*$		$<0.001^*$		$<0.001^*$	

NB: FHL= Flexor Hallucis Longus, EHL= Extensor Hallucis Longus, TA= Tibialis Anterior

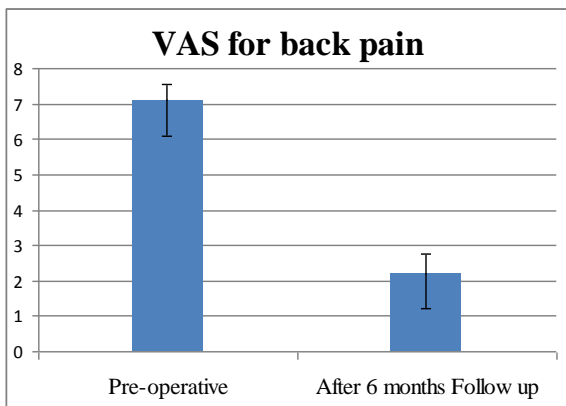


Fig-5: Results on back pain evaluation by VAS between 0 and 10 pre-operatively and six months after surgery (n=20)

Evaluating the pre-operative and post-operative (6 months after operation) mean visual analog score (VAS) for back pain, the VAS has come down from  $7.0 \pm 0.46$  to  $2.25 \pm 0.55$ . Here, the P value is  $<0.05$  (Figure-5).

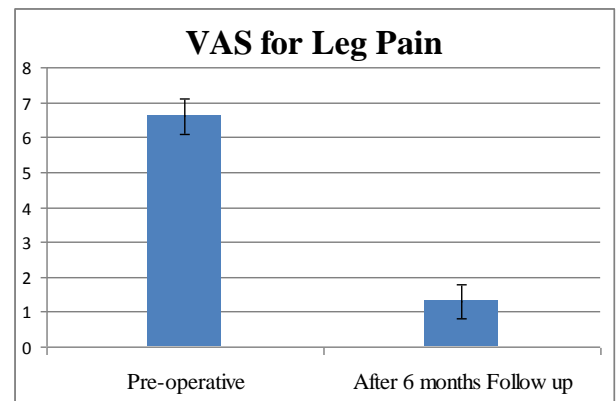
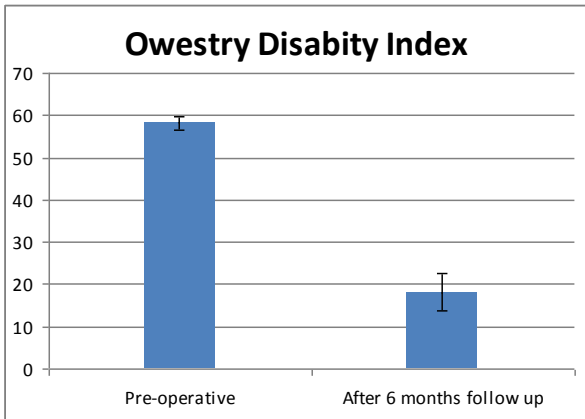


Fig-6: Results on leg pain evaluation by VAS between 0 and 10 pre-operatively and six months after surgery (n=20)

In the study, the pre-operative VAS for leg pain is  $6.6 \pm 0.51$  and after 6 months follow up is  $1.3 \pm 0.47$ . Again, the p value is  $<0.05$  (Figure-6).





**Fig-7: Results on functional outcome measurement by ODI (%) pre-operatively and six months after surgery**

The pre-operative ODI of the sample is 58.2%±1.6%. Six months after operation, the ODI reduced to 18.2%±4.4% (Figure-7).

**Table-6: Results on motor function assessment pre-operatively and six months after surgery (n=20)**

Motor deficit	No of patients	Percentage
Pre-operative Present	12	60.0
Pre-operative Absent	8	40.0
6 months after operation Present	2	10.0
6 months after operation Absent	18	90.0

Pre-operatively, 12(60.0%) patient had motor deficit (assessed clinically according to MRC grading). After six months of operation, it reduced to 2 (10.0%) (Table-6).

**Table-7: Incidence of Major and Minor Operative Complications (n=20)**

Complications	Frequency	Percentage
Minor complication	2	10.0
Major complication	0	0%

In terms of complications, 02 (10.0%) of the patients developed minor complications and none of the patients developed major complication (Table-7).

**Table-8: Results on post-operative functional outcome by Macnab criteria (n=20)**

Post-operative Modified Macnab criteria	Number	Percentage
Excellent	18	90.0
Good	2	10.0
Fair	0	0.0
Poor	0	0.0

Regarding the modified Macnab criteria of the study patients, 18(90%) was found excellent in final follow up and only 2(10.0%) found good (Table-8). So, among the population we will find almost 76.87% to 103.14% satisfactory result by this procedure. So, this procedure can say an effective procedure. According to

Macnab criteria the overall functional outcome was, 18(90%) found excellent and only 2(100%) found good. Regarding radiological variables of the of the study patients, pre-operatively, mean slip angle was found 15.1±1.2 degree, total lumbar angle 21.0±3.0 degree and mean measurement of slip 31.4%±2.3%. Six months after surgery, mean slip angle 7.6±1.1 degree, total lumbar angle 21.0±3.0 degree and mean measurement of slip was 12.7%±1.0%. There was significant increase in disc space height and foraminal height post-operatively (p value< 0.05). Fusion rate was 100% according to Hackenberg criteria.

## DISCUSSION

In present study, out of 20 patients, 3(15.0%) was 30-34 years old, 4(20.0%) was 35-39 years old, 2(10.0%) was 40-44 years old, 6(30.0%) was 45-49 years old and 5(25.0%) was above 50 years. The mean age was 43.8±9.7 years and the lowest and highest ages were 30 and 65 years respectively. Male was found in 5(25.0%) cases and female was found in 15(75.0%) cases. Reported in a related study mean age 59.4±12.3 years and male 37.5% male and 62.5% female [19]. The concept of lumbar spinal instability has received an increased attention from the clinicians and researchers as a potential cause of chronic low back pain, which has been commonly associated with spondylolisthesis [20]. Restoration of the segmental stability by adequate neural decompression, fusion, and stabilization helps to improve clinical symptoms and achieve normal spinal anatomy. Failure of restoration can result in inadequate clinical improvement potentially leading to poor long term results Panjabi [21]. Significant clinical improvement was observed in posterior lumbar interbody fusion techniques in different spinal disorders including spondylolisthesis and found to be superior due to proper neural decompression, structural restoration, and segmental stabilization that ultimately lead to improved pain, disability, and functional capability [22]. In literatures, evaluation of PLIF in spondylolisthesis spine had been done. Both showed highly significant improvement of pain and disability status [8, 23]. The traditional posterior lumbar fusion has demonstrated acceptable rates of fusion, it requires an extensive incision to retract the posterior muscles and expose the transverse processes adequately. By achieving interbody fusion, a PLIF may be performed without the need for a posterolateral fusion, thereby reducing the amount of muscle retraction without sacrificing the goals of the traditional procedure. By reducing retraction, immediate postoperative pain control has been easier to achieve [24]. In this series improvement of pain status measured by Visual Analog Score (VAS) is, back pain improvement from (07.0±0.46 to 02.25±0.55) and leg pain improvement from (06.6±0.51 to 01.3±0.47), p value of both of which is <0.05 which is statistically significant. In initial series [22], the improvement of VAS score of back pain was (07.18 ± 01.09 to 01.84 ± 0.91) and leg pain improvement was (06.88 ± 01.21 to 01.34 ± 0.97) both

of which is comparable to this study. In this series improvement of disability measured by Oswestry Disability Index (ODI %) is  $(58.2 \pm 01.6$  to  $18.2 \pm 4.4)$  after 6 months of follow-up, here also p value is  $<0.05$  which is statistically significant. In the study [25], it was showed that, in 54 patient series Oswestry Disability Index (ODI %) was  $60.00 \pm 01.21$  pre-operatively and  $17.09 \pm 0.97$  after 6 months of follow-up, which is comparable to this study [25]. According to excellent outcome had been observed around 70% cases in PLIF by using Macnab criteria, which was also comparable to this study where excellent outcome is 90% and 10% is good [26]. The overall satisfactory clinical outcome was not measured by the same criteria in different literatures but even then, the overall outcome had also been similar [27]. Interbody cages are used to restore the disc height, foraminal height and stabilize the affected segment [28]. These parameters have significant correlation regarding structural restoration and maintenance of stability [29]. From this study a significant increase of disc and foraminal height as well as neurological improvement. This study revealed a significant ( $P < 0.05$ ) rise of mean disc height from  $07.6 \pm 1.1$  to  $12.2 \pm 1.7$  mm. The mean foraminal height (MFH) increase was recorded from  $13.0 \pm 0.8$  to  $14.7 \pm 0.93$  mm, which was also significant ( $P < 0.05$ ). In [27], of mean disc height (MDH) raised from  $07.76 \pm 02.77$  to  $12.24 \pm 01.89$  mm and mean foraminal height (MFH) increase was recorded from  $13.30 \pm 1.55$  to  $17.50 \pm 01.87$  mm in their 26 patient series, which is comparable to this study. The increased foraminal height effectively decompresses the nerve roots [29] and restores lumbar lordosis which ultimately maintains the lumbar sagittal profile. Restoration of local and regional lordosis ultimately achieves clinical and biomechanical stability [30, 11] recommended to place the graft anterior to the cage and [28], recommended to apply compression using the graft and cage as a fulcrum to achieve the desired lordosis. Interbody fusion with cage has been well accepted for its superior fusion results [33]. In our study, the PI in the spondylolisthesis group was higher than that in the normal group ( $69.6^\circ$  and  $47.5^\circ$ , respectively,  $p < 0.01$ ), the SS in the spondylolisthesis group was higher than in the normal group ( $53.3^\circ$  and  $40.5^\circ$ , respectively,  $p < 0.01$ ) and the PT in the spondylolisthesis group was higher than in the normal group ( $16.6^\circ$  and  $11.6^\circ$ , respectively,  $p < 0.01$ ). These results were in accord with the other reported results [31], conclusion that the SS of the spondylolisthesis group was higher than that of the normal group was supported by our results. The pelvic incidence was suggested by [32], to be an anatomical parameter that is correlated with such positional parameters as the sacral slope and pelvic tilt. Therefore, as the PI is increased, the PT and SS will be increased. Among 72 study subjects, 20 male and 52 female and the age ranges from 15 to 68 years with the mean age being 44.38 years were included in the study. Thirty (41.66%) patients had isthmic spondylolisthesis, 26 (36.12%) had congenital spondylolisthesis, and 16 (22.22%) cases had

degenerative spondylolisthesis. There were 38 (52.77%) cases of grade I, 14 (19.44%) cases of grade II and 20 (27.77%) cases of grade III according to the grading criteria of Meyerding. According to the evaluation criteria used by Stauffer and Coventry, 59 patients (81.94%) got good results, eight patients (11.11%) belonged to the fair group and five cases (6.94%) had the poor results. This study showed that PLIF is one of the effective and reliable techniques for the management of spondylolisthesis. Shown when interbody fusion procedures used in conjunction with a rigid posterior instrumentation system, significantly increasing the initial stiffness of the fused segment above all other constructs [36]. Autografts had been the gold standard for achieving fusion. Placement of autografts anteriorly and impacted before the introduction of cage in all the cases of PLIF with a theoretical background of anterior column load transmission (80%) and enhancement of fusion [33]. The biomechanical concept of "fusion stability" is assessed postoperatively to determine the achievement of stability of fusion area and biomechanically stable spine is achieved only when solid fusion is achieved [34]. Development of pseudarthrosis is one of the most common (range, 05-45%) complications of interbody fusion. In this study, we have achieved 100% fusion rate by using Hackenberg criteria which is comparable to [35] where Pseud arthrosis was present in two (2.60%) patients in their series. In terms of complications, 10% of the patients developed minor complications in current series. 1% reported implant failure rate like screw breakage, screw back up, screw loosening and rod slippage in his large multicentre studies and [36] reported the implant failure in his series of 5%. The implant failure was four (5.55%) [8]. The wound infection rate in this study was 2 cases (10%), which was superficial and treated with regular dressing and intravenous antibiotics. 6.6% of infection in his study on PLIF group and reported wound complications rate was 0.6% to 5%, which was comparable with our result [19, 20, 36]. The criteria used to analyse the overall outcome was proposed by Macnab criteria which is based on relief of back and leg pain, return of employment, restriction of physical activities and use of analgesics for lumbar spine fusion. In this series 18 patients (90%) got excellent results, 2 (10.0%) belonged to the good results. Stauffer got 81% good results with satisfactory clinical outcome which is comparable with our results. Similar study done [37] reported 80% excellent results with satisfactory clinical outcome [38], reported 80% excellent results. To conclude, Posterior Lumbar Interbody Fusion (PLIF) method is effective in relieving symptoms, achieving stability and fusion and lesser complication rates in surgical management of spondylolisthesis.

## CONCLUSION

From the above study result, we can say that PLIF is a cost effective, reasonably easy procedure for the management of spondylolisthesis by enhancing

neurological recovery reduction of pain and make the patients able to return to work comfortably.

## REFERENCES

- Warner WC, Sawyer JR, Kelly DM. Scoliosis and kyphosis. Campbell WC, Canale ST, Beaty JH, editors. Campbell's operative orthopaedics. 2013;2:1739-1740.
- Wiltse LL, Winter RB. Terminology and measurement of spondylolisthesis. JBJS. 1983 Jul 1;65(6):768-72.
- Jeong HY, You JW, Sohn HM, Park SH. Radiologic evaluation of degeneration in isthmic and degenerative spondylolisthesis. Asian spine journal. 2013 Mar;7(1):25-33.
- Ohtori S, Yamashita M, Murata Y, Eguchi Y, Aoki Y, Ataka H, Hirayama J, Ozawa T, Morinaga T, Arai H, Mimura M. Conservative and surgical treatment improves pain and ankle-brachial index in patients with lumbar spinal stenosis. Yonsei medical journal. 2013 Jul 1;54(4):999-1005.
- Kalichman L, Hunter DJ. Diagnosis and conservative management of degenerative lumbar spondylolisthesis. European Spine Journal. 2008 Mar 1;17(3):327-335.
- Fritz JM, Erhard RE, Hagen BF. Segmental Instability of Lumbar Spine. journal of American Therapy Association, 1998;78:889-896.
- Hayes MA, Howard TC, Gruel CR, Kopta JA. Roentgenographic evaluation of lumbar spine flexion-extension in asymptomatic individuals. Spine. 1989 Mar;14(3):327-331.
- Devkota P, Shrestha SK, Krishnakumar R, Renjithkumar J. Posterior lumbar interbody fusion for the management of spondylolisthesis. Nepal Med Coll J. 2011 Mar;13(1):46-49.
- Fathy M, Fahmy M, Fakhri M, Aref K, Abdin K, Zidan I. Outcome of instrumented lumbar fusion for low grade spondylolisthesis; Evaluation of interbody fusion with & without cages. Asian journal of neurosurgery. 2010 Jan;5(1):41-47.
- Gelalis ID, Stafilas KS, Korompilias AV, Zacharis KC, Beris AE, Xenakis TA. Decompressive surgery for degenerative lumbar spinal stenosis: long-term results. International orthopaedics. 2006 Feb 1;30(1):59-63.
- Kim H, Choon-Ki Lee, Jin-Sup Yeom, Jae-Hyup Lee, Ki-Ho Lee, and Bong-Soon Chang 2012. The efficacy of porous hydroxyapatite bone chip as an extender of local bone graft in posterior lumbar interbody fusion. *Eur Spine J*, vol. 21(7), pp. 1324–1330.
- Sanganagouda S Patil, Saurabh Rawall, Premik Nagad, Bhavin Shial, Uday Pawar, and Abhay M Nene 2011. Outcome of single level instrumented posterior lumbar interbody fusion using corticocancellous laminectomy bone chips. *Indian J Orthop*, vol. 45(6), pp. 500–503.)
- Wang ST, Goel VK, Fu CY, Kubo S, Choi W, Liu CL, Chen TH. Comparison of two interbody fusion cages for posterior lumbar interbody fusion in a cadaveric model. International orthopaedics. 2006 Aug 1;30(4):299-304.
- Pope MH, Hanley EN, Matteri RE, Wilder DG, Frymoyer JW. Measurement of intervertebral disc space height. Spine. 1977 Dec 1;2(4):282-286.
- Taillard W. Le spondylolisthesis chez l'enfant et l'adolescent. Acta Orthop Scand. 1954;24:115-44-144.
- Çelik SE, Kara A, Çelik S. A comparison of changes over time in cervical foraminal height after tricortical iliac graft or polyetheretherketone cage placement following anterior discectomy. Journal of Neurosurgery: Spine. 2007 Jan 1;6(1):10-16.
- Phan K, Mobbs RJ, Rao PJ. Foraminal height measurement techniques. Journal of Spine Surgery. 2015 Dec;1(1):35-43.
- Walsh TL, Hanscom B, Lurie JD, Weinstein JN. Is a condition-specific instrument for patients with low back pain/leg symptoms really necessary?: the responsiveness of the Oswestry Disability Index, MODEMS, and the SF-36. Spine. 2003 Mar 15;28(6):607-615.
- Akamaru T, Kawahara N, Yoon ST, Minamide A, Kim KS, Tomita K, Hutton WC. Adjacent segment motion after a simulated lumbar fusion in different sagittal alignments: a biomechanical analysis. Spine. 2003 Jul 15;28(14):1560-1566.
- Fujiwara A, Tamai K, An HS, Kurihashi A, Lim TH, Yoshida H, Saotome K. The relationship between disc degeneration, facet joint osteoarthritis, and stability of the degenerative lumbar spine. Clinical Spine Surgery. 2000 Oct 1;13(5):444-450.
- Panjabi MM. Clinical spinal instability and low back pain. Journal of electromyography and kinesiology. 2003 Aug 1;13(4):371-379.
- Yan DL, Pei FX, Li J, Soo CL. Comparative study of PILF and TLIF treatment in adult degenerative spondylolisthesis. European Spine Journal. 2008 Oct 1;17(10):1311-1316.
- Cole CD, McCall TD, Schmidt MH, Dailey AT. Comparison of low back fusion techniques: transforaminal lumbar interbody fusion (TLIF) or posterior lumbar interbody fusion (PLIF) approaches. Current reviews in musculoskeletal medicine. 2009 Jun 1;2(2):118-126.
- Khoo LT, Palmer S, Laich DT, Fessler RG. Minimally invasive percutaneous posterior lumbar interbody fusion. Neurosurgery. 2002 Nov 1;51(suppl\_2):S2-166.
- Hackenberg L, Halm H, Bullmann V, Vieth V, Schneider M, Liljenqvist U. Transforaminal lumbar interbody fusion: a safe technique with satisfactory three to five year results. European Spine Journal. 2005 Aug 1;14(6):551-558.
- Audat Z, Moutasem O, Yousef K, Mohammad B. Comparison of clinical and radiological results of posterolateral fusion, posterior lumbar interbody



- fusion and transforaminal lumbar interbody fusion techniques in the treatment of degenerative lumbar spine. Singapore medical journal. 2012 Mar 1;53(3):183-187.
27. Sakeb N, Ahsan K. Comparison of the early results of transforaminal lumbar interbody fusion and posterior lumbar interbody fusion in symptomatic lumbar instability. Indian journal of orthopaedics. 2013 May;47(3):255-263.
  28. Hsieh PC, Koski TR, O'Shaughnessy BA, Sugrue P, Salehi S, Ondra S, Liu JC. Anterior lumbar interbody fusion in comparison with transforaminal lumbar interbody fusion: implications for the restoration of foraminal height, local disc angle, lumbar lordosis, and sagittal balance. Journal of Neurosurgery: Spine. 2007 Oct 1;7(4):379-386.
  29. Osman SG, Nibu K, Panjabi MM, Marsolais EB, Chaudhary R. Transforaminal and posterior decompressions of the lumbar spine: a comparative study of stability and intervertebral foramen area. Spine. 1997 Aug 1;22(15):1690-1695.
  30. Klemme LW, Owens CB, Dhawan CA, Zeidman MS, Polly Jr DW. Lumbar sagittal contour after posterior interbody fusion: threaded devices alone versus vertical cages plus posterior instrumentation. Spine. 2001 Mar 1;26(5):534-537.
  31. Labelle H, Roussouly P, Berthonnaud É, Transfeldt E, O'Brien M, Chopin D, Hresko T, Dimnet J. Spondylolisthesis, pelvic incidence, and spinopelvic balance: a correlation study. Spine. 2004 Sep 15;29(18):2049-2054.
  32. Duval-Beaupere G, Schmidt C, Cosson PH. A Barycentremetric study of the sagittal shape of spine and pelvis: the conditions required for an economic standing position. Annals of biomedical engineering. 1992 Jul 1;20(4):451-62.
  33. Kuslich SD, Danielson G, Dowdle JD, Sherman J, Fredrickson B, Yuan H, Griffith SL. Four-year follow-up results of lumbar spine arthrodesis using the Bagby and Kuslich lumbar fusion cage. Spine. 2000 Oct 15;25(20):2656-2662.
  34. Tsantrizos A, Baramki HG, Zeidman S, Steffen T. Segmental stability and compressive strength of posterior lumbar interbody fusion implants. Spine. 2000 Aug 1;25(15):1899-1907.
  35. Mehta VA, McGirt MJ, Garcés Ambrossi GL, Parker SL, Sciubba DM, Bydon A, Wolinsky JP, Gokaslan ZL, Witham TF. Trans-foraminal versus posterior lumbar interbody fusion: comparison of surgical morbidity. Neurological research. 2011 Jan 1;33(1):38-42.
  36. Dantas FL, Prandini MN, Ferreira MA. Comparison between posterior lumbar fusion with pedicle screws and posterior lumbar interbody fusion with pedicle screws in adult spondylolisthesis. Arquivos de neuro-psiquiatria. 2007 Sep;65(3B):764-770.
  37. Azad AK. Evaluation of posterior lumbar Interbody Fusion (PLIF) using cage combined with decompression and stabilization for lumbar spinal canal Stenosis in spondylolisthesis [*MS Thesis*], NITOR, Dhaka. 2016.
  38. Tasmeem MR. Evaluation of the results of transforaminal lumbar interbody fusion by using cage with bone graft and stabilization by pedicle screws and rods in spondylolisthesis [*MS Thesis*], NITOR, Dhaka. 2016.