

Study of Ophthalmic Lesions: Diagnostic Utility of Histopathology and Clinopathological Correlation

Dr. Riddhi Patel^{1*}, Nisha Raval², Dr.T.S.Chokshi³^{1,2}C.U.Shah Medical College, Pathology Department, C. U. Shah Medical College, Surendranagar, Gujarat, India³Professor, Pathology Department, C.U. Shah Medical College, Surendranagar, Gujarat, IndiaDOI: [10.36347/sjams.2020.v08i01.017](https://doi.org/10.36347/sjams.2020.v08i01.017)

| Received: 04.01.2020 | Accepted: 11.01.2020 | Published: 14.01.2020

*Corresponding author: Dr. Riddhi Patel

Abstract

Original Research Article

Background: Ophthalmic pathology is subspecialty of pathology and ophthalmology that focuses on diseases of eye and its neighbouring tissue that ranges from benign to precancerous and malignant lesion. **Aims and objective:** To study morphological and clinico-pathological correlation of ophthalmic lesions and to enhance the communication between ophthalmic surgeon and histopathologist to get detailed information regarding patients' clinical history, signs, symptoms and associated features so that we could correlate with histopathological features. **Methods:** This study was conducted in C. U. Shah Medical College, Surendranagar during year 2016-17. Total 50 specimens were received from ophthalmology department and studied for histopathology. **Result:** Out of 50 cases, 48.8% were benign, 14.89 % were malignant, 18.76% were inflammatory and 17.45 % were non-categorised. Eyelid was the most common site (53.19%). Clinico-histopathological concordance was in approximate 69% cases and discordance was in 31% of cases. Out of these cases of discordance, 43% cases were found to be malignant and diagnosed by clinico-pathological correlation as malignancy was not evident clinically. **Conclusion:** All ophthalmic lesions removed surgically should always be subjected to histopathological examination to establish correct diagnosis and greatest benefit to ongoing patient care.

Keywords: Ophthalmic lesions, Histopathological study, Eyelid.

Copyright @ 2020: This is an open-access article distributed under the terms of the Creative Commons Attribution license which permits unrestricted use, distribution, and reproduction in any medium for non-commercial use (NonCommercial, or CC-BY-NC) provided the original author and source are credited.

INTRODUCTION

Ophthalmic biopsies are one of the rare biopsies we receive in the department of pathology. But we should never forget that ophthalmic pathology is unique in many respects as it encompasses wide range of tissues and shows wide range of diseases.

Ophthalmic Pathology is the subspecialty of Pathology and Ophthalmology that focuses on diseases of the eye and its neighbouring tissues. Ophthalmic Pathologists study tissues excised by Ophthalmologists to provide a precise diagnosis of the disease [1]

It has been reported that 90% of the skin cancers occur in head and neck region and out of them, 10% cases are of ophthalmic lesions [2].

Eyelids are affected by variety of lesions and they may be epithelial, adnexal, vascular, neural, histiocytic, melanocytic or inflammatory in origin. Moreover, eyelids are also affected by different systemic diseases.

Many lesions are identified by clinical appearance and its behaviour; however there are few diagnostic challenging cases which need histopathological evaluation.

The goal of histopathological study of ophthalmic lesions is to enhance communication between the ophthalmic surgeon and the pathologist and to provide detail histopathological information that can be correlated with patient's history and other clinical data giving greatest benefit to ongoing patient care [3].

Objectives of this study were to determine the prevalence of ophthalmic lesions in a patient population treated over one year period in a teaching hospital and also to study the clinicopathological correlation [4].

MATERIALS AND METHODS

The study was carried out in the pathology department of C.U.Shah Medical College and hospital, Surendranagr. Total 100 biopsies & whole specimen of

tumours were obtained from Ophthalmology Department. Institute affiliated to the medical college. A detailed history of each patient regarding age, chief complaints, & other relevant findings were taken. The surgically resected specimens fixed in the 10% formalin were received. Thorough gross examination of each mass for its size, shape, and consistency was done. Several representative areas of tissue were taken from received surgical specimen & subjected to routine paraffin embedding. Four to five sections 2-3 mm thick were taken from different areas of specimen & processed in automatic tissue processor. Blocks were prepared with the help of leuckhart's piece. After trimming of blocks, sections 5-7 um thick were cut with help of rotatory microtome. Sections were floated on water at temperature of 45 degree & were taken on albuminized slides. The sections were stained by haematoxylin & eosin stain in all cases.

RESULT

TOTAL 50 patients comprising 28 males (56%) and 22 females (44%) having ophthalmic lesions were studied. The age ranges from 11 years to 90 years with mean age of 50 years.

Table-1: Age wise distribution of eye lesions

Age Group	No. of cases
11-30	10
31-50	14
51-70	19
70-90	07

Benign lesions were more common in 3rd and 4th decades whereas malignant lesions were more common in 5th to 7th decade of life.

Table 2: Incidence of various lesions studied

Type Of Lesion	Incidence (%)
Benign	48.80
Inflammatory	18.76
Malignant	14.89
Non-catagorised	17.45

Out of total 50 cases, 48.8% were benign, 18.76% was inflammatory, 14.89% were malignant and 17.45% were non-catagorised.

Table-3: Location wise distribution of lesions

SITE	INCIDENCE (%)
EYELID	54
CONJUNCTIVAL	26
CORNEAL	20

Eyelid was the most common site to be involved. (54%) followed by Conjunctiva (26%) and cornea (20%).

Table-4: Incidence of most common benign and malignant lesion

Benign Lesion	Malignant Lesion
Naevus	Squamous epithelial carcinoma
Epidermal cyst	Basal cell carcinoma

Among Benign lesions, Cysts (epidermal) were the most common lesion involved followed by naevus (compound, junctional). Squamous cell carcinoma followed by basal cell carcinoma were the most common malignant lesions involved in present study.

Table-5: Various lesions studied in present study

Type of Lesion	No. of cases studied
Naevus	08
Cysts	07
Capillary haemangioma	05
Pigmented seborheic keratosis	04
Sebaceous adenoma	01
Eccrine hydrocystoma	01
Trichoepithelioma	01
squamous cell carcinoma	03
Basal cell carcinoma	01
Merkel cell carcinoma	01
Sebaceous gland carcinoma	01
Malignant melanoma	01

Table-6: Clinopathological discordance

	CLINICALLY SUSPECTED	DIAGNOSED HISTOLOGICALLY	DISCORDANCE
MALIGNANT LESIONS	1 CASE OF Basal cell carcinoma(BCC)	BCC	
	IN 6 CASES-SENT AS MASS NOT SUSPECTED MALIGNANCY	MALIGNANCY WAS DIAGNOSED (6 CASES)	19.35%
BENIGN LESION (TOTAL 43 CASES)		10 CASES	11.65%
TOTAL			31%

Table-7: Out of total discordance cases- 43% cases were of malignant lesions which were not suspected clinically

Clinical diagnosis	Histopathological diagnosis	Clinohistopathological discordance
Mass	Basal cell carcinoma Squamous cell carcinoma Malignant melanoma Merkel cell carcinoma Sebaceous gland carcinoma	Total 43% of all discordance (7/16)

In present study, Out of 7 cases of malignancy, only in 1 case basal cell carcinoma was suspected clinically. In rest of 6 cases, malignancy was diagnosed after histopathological examination in which malignancy was not suspected before excision. In benign cases, there was 11.65% clinohistopathological discordance So total 31% discordance was there in present study.

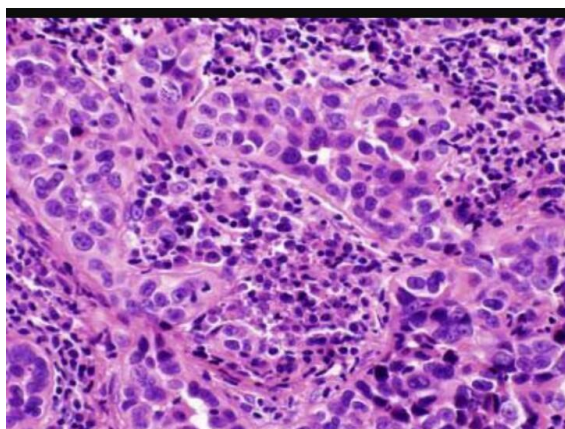


Fig-1: Histological image of Sebaceous gland carcinoma

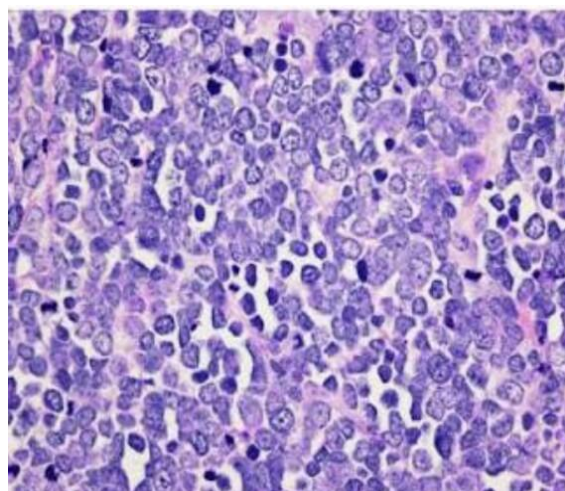


Fig-2: Histological image of Merkel cell carcinoma

DISCUSSION

The present study was conducted with an aim to assess the histopathological types of eye lesions. It was a hospital based cross sectional study which enrolled 50 clinically suspected eye growths. Out of them 07 were neoplastic and 43 were non- neoplastic growth. In our series we found 14.89% malignant, 48.8% benign growth and rest were inflammatory lesions. There was only one case of premalignant lesion. A study from Japan in 2012 has reported that out of 118 eyelid tumors that were removed and examined, 106 (89.8%) were benign and 12 (10.2%) were malignant [5].

Previous study in a tertiary care hospital in Thailand, has reported that out of 212 cases of eyelid tumor, 71.4% were benign and 10.8% were malignant [6]. We found a higher percentage of malignant growths. This might be due to the delay in seeking treatment because of lack of awareness, education and treatment facilities in rural areas, low socioeconomic status and less cosmetic concern.

In the present study, the majority of the patients (33 out of 50) were in the 31 to 70 years age group. Mean age of the study population in the present study is 50 years.

Most of the malignant eyelid lesions were in patients above 51 years of age and benign growths were within the age group 26-50 years. Mean age of the patients with malignant lesions was 56.3 years and those with benign was 35.9 years. Both benign and malignant lesions of the eyelid were most commonly seen in patients in their forties and fifties [7]. Studies from Thailand, Taiwan and Japan have reported the mean age of diagnosis of eyelid cancers was between 52.4 to 72 years [8,9,10]. However, malignant tumors like squamous and basal cell carcinoma of the eyelid have been reported in patients below 25 years of age [11].

Among the malignant tumors in the present study, most common was squamous cell carcinoma (42.85%) followed by basal cell carcinoma (36.45%). In western countries, basal cell carcinoma is the most common among malignant eyelid tumors, whereas in Japan and other parts of Asia, the frequency of sebaceous gland carcinoma and squamous cell carcinoma are relatively high [10]. Sebaceous gland carcinoma tumor is more common in Asian countries, reportedly comprising 33% of eyelid tumors and second behind basal cell carcinoma [12]. The etiology of sebaceous carcinoma is not entirely known. Human papilloma virus and increased expression of TP53 gene has been implicated as genetic factor in invasive sebaceous gland carcinoma [13, 2]. In the present study, sebaceous gland carcinoma was found in 14.28% cases with malignant tumors. Eyelid squamous cell carcinoma is an invasive tumor arising from the squamous cell

layer of the skin epithelium and affects mainly elderly fair-skinned individuals. The most common risk factor is exposure to ultraviolet light. Most commonly, it involves the lower lid margin and inner canthus. It may arise de novo but often it may arise from preexisting lesions such as actinic keratosis, xeroderma pigmentosum, carcinoma in situ (Bowen's disease), or following radiotherapy [14].

Among the benign lesions of eyelid, nevi were the most common in the present study. Out of 43 benign lesions, nevus was the most common (18.60%), followed by cysts (16.27%), haemangioma (11.62%), seborrheic keratosis (9.3%) and 1 case of eccrine hydrocystadenoma, 1 case of trichoepithelioma and 1 case of sebaceous adenoma. Similar pattern of benign growth of eyelids were reported by others [15].

Conjunctiva, lacrimal sac, sclera and eyelids are the most common ocular sites. Eyelid is composed of heterogeneous tissue [13].

Hence, we tend to see a variety of tumor types and subtypes, both benign and malignant. The early diagnosis of these tumors is essential for proper treatment and favorable prognosis. The present study has showed the pattern of eyelid tumors in our population. The information is important to ophthalmologists for accurate diagnosis of eye growths and its proper management.

In our study, Out of 7 cases of malignancy, only in 1 case basal cell carcinoma was suspected clinically. In rest 6 cases, malignancy was diagnosed after histopathological examination. In benign cases, There was 11.65% clinohistopathological discordance So there was total 31% discordance was there in present study.

Table-8: Comparison of clinohistopathological discordance to other studies: [16, 17]

Name of study	Clinical discordance	Clinical concordance
Pudasaini <i>et al.</i> [12,13]	46.5%	54.4%
Present study	31%	69%

Table-9: Comparison of incidence of benign and malignant lesions with other studies

Name of study	Benign	Malignant
Obata H <i>et al.</i> [14]	73%	27%
Tesluk GC <i>et al.</i> [16]	82.60%	41.10%
Abdi U <i>et al.</i> [15]	58.90%	41.1%
Present Study	85.11%	14.89%

CONCLUSION

Every ophthalmological lesion treated surgically should always be subjected to histopathological examination and should be correlated with clinical history that will help in ongoing patient management especially in cases of malignant lesion.

Eyelid malignancies are completely treatable if detected early. Early diagnosis of eyelid growth is thus of extreme importance to avoid high morbidity and mortality.

REFERENCES

- Ophthalmic Pathology Primer. Available from: http://www.vetmed.ucdavis.edu/courses/vet_eyes/eye_path/epath_overview_index.html. Accessed January 24th 2012.
- Myers M. Gurwood As periocular malignancies and primary eye care. *Optometry*, 2001; 72(11): 705-712.
- Ophthalmic patho service. Available from: http://www.smbs.buffalo.edu/ophthalmology/clinicalservices/pathology_fed.htm. Accessed Jan 24th 2012.
- Ophthalmic Pathology Service. Available from: <http://www.smbs.buffalo.edu/ophthalmology/clinic>
- alServices/pathology_fed.htm. Accessed January 24th 2012. Volume 2 Issue 2 Apr – June 2012 print ISSN: 2249 4995 eISSN: 2277 8810 Page 136
- Toshida H, Mamada N, Fujimaki T, Funaki T, Ebihara N, Murakami A and Okisaka S. Incidence of benign and malignant eyelid tumors in Japan. *Int J Ophthalmic Pathol*. 2012; 1(2): 112-114.
- Pornpanich K, Chindasub P. Eyelid tumors in Siriraj Hospital from 2000-2004. *J Med Assoc Thai*. 2005; 88(Suppl 9): S11-14.
- Mondal SK and Dutta TK. Cytohistological study of eyelid lesions and pitfalls in fine needle aspiration cytology. *J Cytol*. 2008; 25(4): 133-137.
- Lin HY, Cheng CY, Hsu WM, Kao WH and Chou P. Incidence of eyelid cancers in Taiwan: a 21-year review. *Ophthalmology*. 2006; 113(11): 2101-2107.
- Pombejara FN, Tulvatana W and Pungpapong K. Malignant tumors of the eye and ocular adnexa in Thailand: a six-year review at King Chulalongkorn Memorial Hospital. *Asian Biomed*. 2009; 3: 551-555.
- Takamura H, Yamashita H. Clinicopathological analysis of malignant eyelid tumor cases at Yamagata University hospital: statistical comparison of tumor incidence in Japan and in other countries. *Jpn J Ophthalmol*. 2005; 49: 349-354.
- Abdi U, Tyagi N, Maheshwari V, Gogi R, Tyagi SP, Tumours of eyelid: a clinico-pathologic study. *J Indian Med Assoc*. 1996 Nov; 94(11): 405-9, 416, 418.

12. Kanski JJ. Clinical ophthalmology: a systematic approach. 5th ed. Philadelphia PA: Butterworth Heinmann; 2003.
13. Obata H, Aoki Y, Kubota S, Kanai N, Tsuru T, Incidence of benign and malignant lesions of eyelid and conjunctival tumors. *Nippon Ganka Gakkai Zasshi*. 2005; 109(9):573-9.
14. Font RL. Eyelids and lacrimal drainage system. In: Spencer WH, editor. *Ophthalmic pathology- an atlas and textbook*, vol. 4. 4th ed. Philadelphia: WB Saunders. 1996; 2229–2232.
15. Coroi MC, Rosca E, Mutiu G, Coroi T, Bonta M. Eyelid tumors: histopathological and clinical study performed in County Hospital of Oradea between 2000–200
16. Chauhan S, Shah S, Solanki P. Accuracy of clinical diagnosis of eyelid lesion in a medical college in Gujarat. *Int'l J Res Med*. 2013; 2: 114-7.
17. Sujata Pudasaini. A histopathological study of ophthalmic lesions. *Nepal Med Coll J*. 2013; 15(1): 78-80.