

Efficacy of Transversus Abdominis Plane (TAP) Block for Postoperative Analgesia in Caesarean Section

Dr. Bishnu Prasad Mohapatra¹, Dr. Basant Kumar Pati^{2*}

¹Asst Prof. Department of Anaesthesiology and critical care, SCB Medical College & Hospital, Cuttack, Odisha, India

²Department of Obstetrics & Gynecology, Institute of Medical Sciences & SUM Hospital Bhubaneswar Odisha, India

Original Research Article

*Corresponding author

Dr. Basant Kumar Pati

Article History

Received: 03.01.2018

Accepted: 15.01.2018

Published: 30.01.2018

DOI:

10.36347/sjams.2018.v06i01.025



Abstract: Recently the transversus abdominis plane (TAP) block is widely used block to provide adequate post-operative analgesia to the anterior abdominal wall. We evaluated the analgesic efficacy of the transversus abdominis plane block using bupivacaine in patients undergoing caesarean section. 100 patients posted for elective and emergency caesarean section were randomized to two groups of 50 each. All patients were given TAP block with bupivacaine. All patients received spinal subarachnoid block. After completion of surgery bilateral TAP block (ultrasound guided) was performed using 30 ml of 0.25% bupivacaine or saline on each side. Each patient in both groups were assessed postoperatively by a blinded investigator in the postanesthesia care unit at 2, 4, 6, 12, 24, 36, 48 h postoperatively. The transversus abdominis plane block using bupivacaine decreased the postoperative visual analogue scale pain scores in comparison to placebo block. Amount of rescue analgesia required and incidence of postoperative nausea and vomiting was found less with transversus abdominis plane block. Post-operative transversus abdominis plane block with bupivacaine decreased post-operative analgesia requirements and provided effective postoperative prolonged analgesia.

Keywords: Caesarean section, perioperative analgesia, and transversus abdominis plane block.

INTRODUCTION

Postoperative pain produces both acute and chronic psychological symptoms. So treatment of postoperative pain through different regional blocks and pharmacological agents can be done to reduce postoperative complications and facilitate quick recovery [1].

Reduction of post-operative pain is important to provide early ambulation, decrease the chance of paralytic ileus, and increase enteral motility, decrease hospital stay. Inadequate postoperative pain relief in abdominal surgery can delay early ambulation thereby increasing chances of DVT and produces other co morbidities [2]. The efficiency of transversus abdominis plane (TAP) block has been studied in several abdominal surgeries [3]. In TAP block neural afferent supplying the abdominal wall are blocked by local anaesthetics. Thoraco lumbar nerves from T7 to L1 innervating the anterior abdominal wall are blocked, as described by Dr Rafi [4]. Patients feel pain after caesarean section which affects infant care. TAP block may be one of the effective method in reducing post-operative pain. Transversus abdominis plane (TAP) block has been used for postoperative analgesia in patients undergoing caesarean section under subarachnoid block [5-7]. The aim of the present study was to find out the efficacy of bupivacaine in

transversus abdominis plane block for providing postoperative analgesia after caesarean section under spinal anaesthesia.

MATERIALS AND METHODS

This study was conducted from Jan 2017 to Dec 2018 after approval of the institutional ethics committees. Informed consent was obtained from all patients. ASA status I and II patients of age 18-45 years, scheduled for caesarean section under spinal anaesthesia were included in the study. Patient with history of cardiovascular diseases, allergy to local anaesthetics and body mass index more than 30 were excluded from this study.

100 patients were divided randomly into two groups of 50 each. All patients received inj. Ranitidine 50 mg IV and Inj. Metoclopramide 0.15 mg / kg IV. Baseline SBP, DBP, MAP, heart rate, ECG and oxygen saturation were monitored. Subarachnoid block was

given using a 25G Quincke type spinal needle in the L3-L4 intervertebral space in midline in sitting position with 2.5 mL of 0.5% bupivacaine heavy. After the surgery was over, all patients in the study group received bilateral TAP blocks.

Transversus abdominis plane block was given by help of ultrasound as described by Borglum *et al.* [8] using a 1.5-inch, 22-gauge needle. The same procedure was followed in the other side. Group B received total 30 ml of 0.25% bupivacaine and group C received total 30 ml of distilled water on both side. Rescue analgesic was given as inj. Tramadol 100 mg IV when there was VAS score > 4. Rescue antiemetic was given as inj. Ondansetron 4 mg IV if there was complain of nausea or vomiting. The patients were assessed in the post-

operative period at 6, 12, 24 and 48 hours after surgery. Pain (VAS), requirement of rescue analgesics, nausea and vomiting were monitored. All patients were asked to assess pain and post-operative nausea and vomiting using the following scales and scores. Visual Analog Scale (VAS)[9] : 10 cm line in which 0=no pain and 10=worst pain. Categorical nausea scoring system: 0=none; 1=mild; 2=moderate; 3=severe. The data was recorded in a master chart and analysis was completed using the SPSS version 21 software.

RESULTS

The study was conducted in a total of 100 patients. There was no statistically significant difference regarding demographic parameters.

Table-1: Requirement of analgesics and antiemetics

| Parameter | Study group(B) | Control group(C) | P Value |
|---------------------------------------------------|----------------|------------------|---------|
| Total tramadol requirement (mg) | 175.00±18.5 | 285.00±20.4 | 0.001 |
| Mean time to request first dose of tramadol (hrs) | 8.1±1.5 | 3.5±0.9 | 0.001 |
| Total antiemetic (Ondansetron) requirement (mg) | 8.5±1.9 | 18.64±3.6 | 0.001 |

The total amount of rescue analgesic requirement was measured as total milligrams of tramadol (rescue analgesic) received. Mean values of total tramadol requirement were 175.00±18.5mg for

group B and 285.00±20.4mg for group C (table 1) (fig 1). The difference was statistically significant (p value < 001).

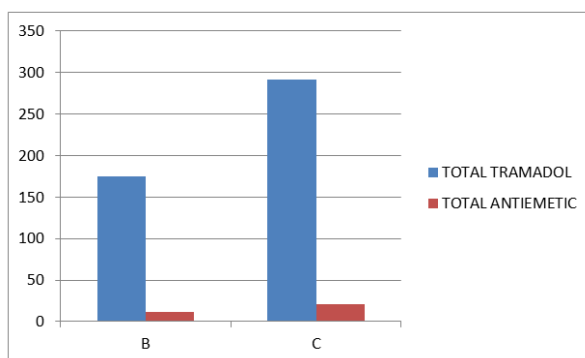


Fig-1: Requirement of analgesics and antiemetics

Average time taken for administration of the first dose of rescue analgesic was 8.1±1.5hours in the group B and 3.5±0.9hours in the group C (Table 1). This difference was also found to be statistically significant (P < 0.001) (Table 1). Average amount of antiemetic (ondansetron) was also found to be significantly less in group B (Table 1; figure1).

The VAS scores at different time interval was compared using independent t test. There was a significant decrease in the scores in the group B compared to group C (fig 2).

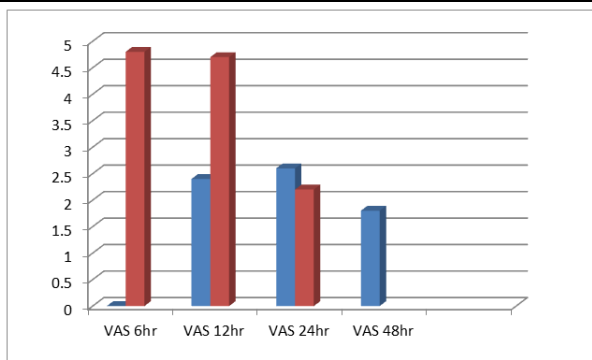


Fig-2: Post-operative Visual Analogue Scale (VAS) score comparison in B and C group

DISCUSSION

In our study we have found that transversus abdominis plane block after caesarean section reduce rescue analgesic requirement in postoperative period. It delayed the time to request for rescue analgesia and decreased postoperative nausea and vomiting. The requirement of antiemetic was significantly reduced in the patients who received the block. This may be secondary to the tramadol sparing effect of the block.

Venkatraman R in their study opined that the ultrasound-guided TAP block provides good postoperative analgesia, reduces analgesic requirements, and provides lower VAS scores with fewer complications following inguinal hernia surgery [9]. Srivastava U et al.[10] in his study found that the TAP block was effective in providing analgesia with a substantial reduction in tramadol use during 48 h after caesarean section. According to Sharkey et al.[11] transversus abdominis plane block significantly improved the quality of postoperative analgesia and reduced total opioid requirement and thereby reducing opioid related side effects in women undergoing caesarean section. Bhattacharjee et al.[12] concluded that preincisional TAP block decreased intraoperative fentanyl requirements and provided effective postoperative analgesia which was similar to our study findings. Sharma et al.[13] also found same result after abdominal surgeries. Mankikar et al.[14] has done ultrasound guided TAP block using ropivacaine and found that there was reduced analgesia requirement. TAP block with ropivacaine compared with normal saline reduced post-operative VAS at 24 h. Time for rescue analgesia in the study group was prolonged from 4.1 to 9.53 h ($P = 0.01631$). Mean requirement of tramadol in the first 24 h was reduced in the study group which was similar to our study. Prabhu et al. in their study found that the duration of analgesia provided by 0.25% bupivacaine was significantly longer than that provided by 0.125% bupivacaine through US-guided TAP block in inguinal hernia repair[15].

CONCLUSION

The Transversus abdominis plane block has become as a part of a multimodal analgesic regimen which has a role in providing quality analgesia in the

postoperative period. Transversus abdominis plane block provided prolonged post-operative analgesia after caesarean section under subarachnoid block. It reduced the dose of rescue analgesia requirement thus reducing the incidence of post-operative nausea and vomiting and antiemetic requirement. Thus, TAP block can be reliably used for postoperative pain relief after caesarean section under spinal anaesthesia.

REFERENCES

- Hurley RW, Wu CL, Acute postoperative pain. In: Miller RD, editor. Miller's anesthesia. 7th ed. Philadelphia, PA: Churchill – Livingstone; 2010:2758-2579.
- McDonnell JG, O'donnell B, Curley G, Heffernan A, Power C, Laffey JG. The analgesic efficacy of transversus abdominis plane block after abdominal surgery: a prospective randomized controlled trial. *Anesthesia & Analgesia*. 2007 Jan 1;104(1):193-7.
- Belavy D, Cowlshaw PJ, Howes M, Phillips F. Ultrasound-guided transversus abdominis plane block for analgesia after caesarean delivery. *Br J Anaesth* 2009;103:726-30.
- Rafi AN. Abdominal field block: a new approach via lumbar triangle. *Anaesthesia* 2001;56:1024-6.
- Qazi N, Bhat WM, Iqbal MZ, Wani AR, Gurcoo SA, Rasool S. Postoperative Analgesic Efficacy of Bilateral Transversus Abdominis Plane Block in Patients Undergoing Midline Colorectal Surgeries Using Ropivacaine: A Randomized, Double-blind, Placebo-controlled Trial. *Anesthesia, Essays and Researches*. 2017;11(3):767-772.
- Desale Tewelde Kahsay, Waltraud Elsholz & Habteselassie Zerezghi Bahta. Transversus abdominis plane block after Caesarean section in an area with limited resources, *Southern African Journal of Anaesthesia and Analgesia*, 2017; 23(4): 90-95,
- John R, Ranjan RV, Ramachandran TR, George SK. Analgesic Efficacy of Transverse Abdominal Plane Block after Elective Cesarean Delivery – Bupivacaine with Fentanyl versus Bupivacaine Alone: A Randomized, Double-blind Controlled Clinical Trial. *Anesthesia, Essays and Researches*. 2017;11(1):181-184.

8. J. Borglum, C. Maschmann, B. Belhage, K. Jensen. Ultrasound –guided bilateral dual transversus abdominis plane block: a new four-point approach. *Acta Anaesthesiol Scand* 2011;55(6): 658-663.
9. Venkatraman R, Abhinaya RJ, Sakthivel A, Sivarajan G. Efficacy of ultrasound-guided transversus abdominis plane block for postoperative analgesia in patients undergoing inguinal hernia repair. *Local and Regional Anesthesia*. 2016;9:7-12.
10. Srivastava U, Verma S, Singh TK, Gupta A, Saxena A, Jagar KD. Efficacy of transversus abdominis plane block for post caesarean delivery analgesia: A double blind randomized trial. *Saudi J Anaesth* 2015;9:298-302
11. Sharkey A, Finnerty O, Mc Donnell JG. Role of transversus abdominis plane block after caesarean delivery. *Curr Opin Anaesthesiol* 2013;26(3):268-72
12. Bhattacharjee S, Ray M, Ghose T, Maitra S, Layek A. Analgesic efficacy of transversus abdominis plane block in providing effective perioperative analgesia in patients undergoing total abdominal hysterectomy: a randomized controlled trial; *J Anaesthesiol Clin Pharmacol*. 2014;30:391-396
13. Sharma P, Chand T, Saxena A, Mittal A, Srivastava U. Evaluation of postoperative analgesic efficacy of transversus abdominis plane block after abdominal surgery: A comparative study. *J Nat Sci Biol Med*. 2013;4(1):177-180
14. Mankikar M G, Sardesai S P, Godki P S, Ultrasound – guided transversus abdominis plane block for post-operative analgesia in patients undergoing caesarean section. *Indian J of anaesthesia*. 2016 April; 60(4): 253-257.
15. Prabhu R, Singh D, Krishnaveni. A Comparative Study of Postoperative Analgesia Provided by Ultrasound-Guided Transversus Abdominis Plane Block Using Two Concentrations of Bupivacaine in Patients Undergoing Inguinal Hernia Repair *Anesth Essays Res*. 2017 Oct-Dec; 11(4): 934–939.