

Perioperative Management of Surgical Clipping of Ruptured Brain Aneurysms: Preliminary Study on a Serie of 113 Patients.

Bah MD^{1*}, Ndiaye PI², Léye PA², Thioub M³, Barboza D⁴, Traoré MM⁵, Gaye I², Ba EB², Diop EN², Béye MD², Kane O¹, Diouf E.²

¹Anaesthesia-Intensive care department- Fann Teaching Hospital- Dakar

²Anaesthesia-Intensive care department-Aristide Le Dantec Teaching Hospital- Dakar

³Neurosurgery clinic- Fann Teaching Hospital- Dakar

⁴Anaesthesia-Intensive care department- Ziguinchor Hospital- Ziguinchor

⁵Anaesthesia-Intensive care department- Albert Royer Teaching Hospital- Dakar

Original Research Article

*Corresponding author

Bah MD

Article History

Received: 10.10.2017

Accepted: 25.11.2017

Published: 30.1.2018

DOI:

10.36347/sjams.2018.v06i01.060



Abstract: Meningeal hemorrhage (MH) by aneurysm rupture is a serious neurovascular emergency affecting a young and healthy population. Surgical clipping is a therapeutic way to avoid recurrence of bleeding which has very poor prognosis. The purpose of our study was to evaluate the perioperative anesthetic management of patients, who had undergone surgical clipping of a ruptured cerebral aneurysm that had been diagnosed with subarachnoid hemorrhage. This is a preliminary, retrospective, descriptive and analytical study conducted from January 1st, 2013 to June 30th, 2017. All patients who underwent clipping of a ruptured cerebral aneurysm that determined a MH were included in the study. During that period, 113 patients benefited from the clipping of a cerebral aneurysm. The average age was 47.1 years [19-66 years]. The aneurysm was located in the anterior communicating, middle cerebral and carotid arteries in 37.7%, 26.4% and 15.1%, respectively. To improve brain relaxation, EtCO₂ was fixed at around 30mm/Hg, 35 patients (39.6%) had benefited from the mannitol infusion and 6 patients (5.3%) had external CSF drainage. The rupture of the aneurysmal sac occurred in 6 patients (5.3%) during the surgical approach with an estimated average blood loss of 500ml. Postoperatively, an arterial vasospasm determining cerebral ischemia (5.3%), an hydrocephalus (4.4%) and hyponatremia (8.8%) were the main postoperative complications noted. Death occurred for 9 patients (7.9%). The importance of the initial bleeding (P = 0.002) and the occurrence of vasospasm (P = 0.003) were the identified death factors. Knowledge of pathophysiology and procedures helps prevent complications from preoperative management.

Keywords: Cerebral aneurysms - Meningeal hemorrhage - Neuroanesthesia - Arterial vasospasm.

INTRODUCTION

Aneurysm is the most common vascular malformation and is the leading cause of meningeal hemorrhage (MH) [1]. Aneurysmal rupture, associated with a high mortality between 30 and 50% is burdened with three main risks: hydrocephalus, the occurrence of delayed ischemic complications and rebleeding [2]. Emergency surgical clipping allowing the exclusion of the aneurysm from the blood circulation is a therapeutic way to prevent rebleeding, which has a very poor prognosis by doubling mortality [3]. The aim of our study was to evaluate the perioperative anesthetic management of patients who had undergone surgical clipping of a ruptured cerebral aneurysm that had been diagnosed with MH.

PATIENTS AND METHODS

This is a preliminary, retrospective, descriptive and analytical study conducted from 1st of January 2013 to 30th of June 2017 at the neurosurgery department of Fann University Hospital, in Dakar. Were included in the study all patients who underwent clipping of a ruptured brain aneurysm that determined an MH. From hospital records and anesthesia files, we collected data on age, sex, antecedents, clinics (Glasgow score, neurological grade WFNS, aneurysm seat, Fischer score at angio-CT, delay between bleeding and clipping), and intraoperative management (ways of monitoring, anesthetic drugs used, ways of cerebral relaxation, hemodynamic, ventilatory and neurological complications). We also collected data on postoperative management (extubation delay, treatment, occurrence

of secondary cerebral exacerbation factors of systemic origin, occurrence of arterial vasospasm) and finally on evolution. For all patients, the average preoperative blood pressure objectives were between 100 and 120 mm/Hg. In the operating room, monitoring included electrocardiographic tracing, non-invasive or invasive blood pressure, peripheral O₂ saturation (SpO₂) and capnography with EtCO₂ at around 30 mm/Hg. Two large peripheral channels, one dedicated to blood transfusion, had been set up. The induction of anesthesia combined a hypnotic (Thiopental or Propofol) with Fentanyl and Vecuronium. Maintenance of the anesthesia was performed with Propofol continuously to the electric syringe pump. For all patients, cerebral relaxation was applied, and combined a current volume of the respirator with 6 ml/kg, EtCO₂ around 30mm/Hg, and for some a 10% mannitol drip or an external CSF drainage. Postoperatively, patients were admitted to the neuro-resuscitation unit and immediately extubated to normothermia. A cerebral CT was performed on D₁ and immediately after any abnormal neurological examination. The results are expressed in averages.

RESULTS

Over the study period, 113 patients who were presented with MH benefited from the clipping of a cerebral aneurysm. The average age was 47.1 years with extremes of 9 and 66 years. The predominant age group was between 40 and 60 years old (Figure 1). A

clear predominance of women was noted (73.1%). High blood pressure was the most common antecedent (43.4%). The aneurysm was located in the anterior communicating, middle cerebral and internal carotid arteries in respectively 38%, 27% and 15%. (Table1). The preoperative neurological examination found a neurological grade WFNS I and II in respectively 78% and 17% (Table 2). Clipping was performed during the first 3 days in 20 patients (22.6%) and in 93 patients (77.4%) beyond the 21st week. For the prevention of arterial vasospasm, Nimodipine was administered preoperatively to 34 patients (38%). Propofol and Thiopental were the hypnotics used in 60.4% and 39.6% of cases, respectively. To improve cerebral relaxation, 35 patients (39.6%) had received mannitol drip and 6 patients (5.3%) had external CSF drainage. The rupture of the aneurysmal sac occurred in 6 patients (5.3%) during the surgical approach with an estimated average blood loss of 500ml. Postoperatively, the average time to extubation was 8 hours with extremes of one hour and 216 hours (9 days). An arterial vasospasm determining cerebral ischemia in 6 patients (5.3%), hydrocephalus in 5 patients (4.4%), and hyponatremia in 10 patients (8.8%) were the main postoperative complications noted (Table 3). The evolution was towards death for 9 patients (7.9%). The identified death factors were the importance of initial bleeding (P = 0.002) and the occurrence of arterial vasospasm (P = 0.003).

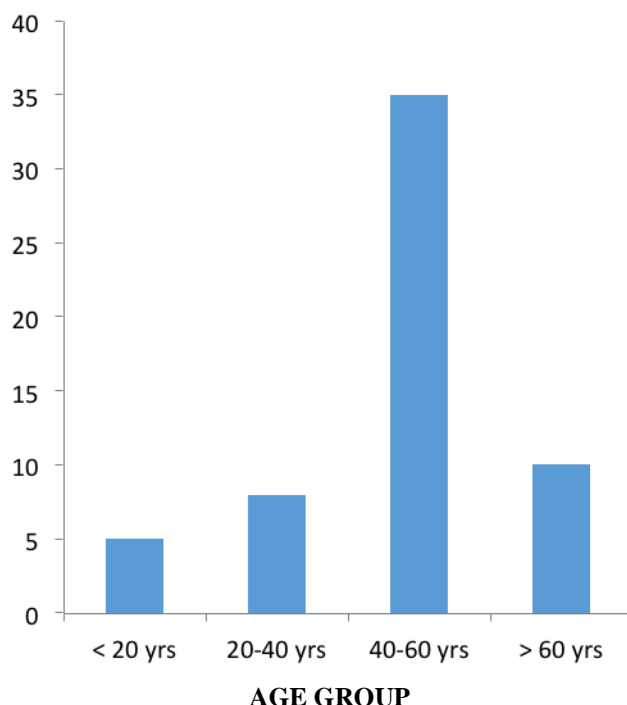


Fig-1: Repartition of patients according to age group

Table-1: Repartition of patients according to the arterial localization of aneurysm.

Cerebral arteries	Number (n)	Percentage %
Carotid artery	17	15
Anterior communicating artery	43	38
Posterior communicating artery	15	13
Anterior cerebral artery	08	7
Middle cerebral artery	30	27
Total	113	100

Table-2: Repartition of patients according to the neurological score WFNS.

WFNS score	Number (n)	Percentage %
I	88	78
II	19	17
III	04	03
IV	02	02
Total	113	100

Table-3: Post-opérative complications.

Complications	Number (n)	Percentage %
Cerebral ischemia by arterial vasospasm	6	5,3
Hydrocephalus	5	4,4
Hyponatremia	10	8,8
Nosocomial pneumonitis	3	2,6

DISCUSSION

Our serie is a relatively young population with an average age of 47 years old. The 40-60 age group are the most affected. MH by aneurysm rupture represents 1 to 5% of all cerebrovascular accidents, but before age of 35, this proportion increases to 50% [4]. Treatment of a ruptured aneurysm must be done urgently to avoid rebleeding. Rebleeding is the main cause of adverse outcomes after MH. Indeed the majority of patients (70%) who rebleeded, finally died [5]. Preoperatively, the neurological assessment of our patients focused on investigating possible intracranial hypertension. Thus, the clinical examination included a simple order response, an assessment of the degree of orientation, the search for a possible phasic disorder or motor deficit, the evaluation of the Glasgow score and the state of the pupils. The majority of our patients had WFNS neurological grade I (78%) and no evidence of intracranial hypertension. The management of the blood pressure had been one of the axes of preoperative management. High blood pressure during MH is usual. It is part of the compensation mechanisms. Our blood pressure goals were systolic blood pressure between 140 and 150 mm/Hg because of the risk of rebleeding. And similarly, because of the risk of arterial vasospasm occurring, systolic blood pressures below 140 mm/Hg were proscribed. After an MH, 30 to 70% of patients present an angiographic arterial vasospasm which, through a decrease in blood pressure, will determine an ischemic neurological deficit [6]. Arterial vasospasm, which can occur suddenly before or after clipping, is one of the most serious complications. It occurs usually between the 4th and the 14th day of evolution. Its occurrence would be responsible for an increase of 1.5 to 3 times of the mortality. Its prevention involves the

administration of Nimodipine, a calcium channel blocker with an affinity for the cerebral vessels. It had been prescribed to 39% of our patients. One of the obstacles to its prescription is its expensive cost. In per-operative the anesthetic objective had been to avoid hypertensive outbreaks that increase the risk of aneurysm rupture and hypotension source of cerebral hypoperfusion. The most delicate situation during anesthesia is undoubtedly the induction and intubation phase. Blood pressure can vary rapidly between low values (risk of cerebral ischemia) and high values (risk of rebleeding). Aneurysmal rupture, contemporary of an algebraic stimulus such as laryngoscopy, has been reported [7]. Maintaining good cerebral relaxation limits the use of retractors and decreases brain tension under the retractors responsible for local ischemia. Hypocapnia with EtCO₂ around 30 mm/Hg, mannitol drip and thorough anesthesia are effective potentiating ways that allow good cerebral relaxation. We performed pre or perioperative CSF drainage for 6 patients (5.3%). CSF drainage is performed with caution because of the risk of a sudden drop in intracranial pressure responsible for an increase in transmural pressure of the aneurysm causing rebleeding. Perioperative aneurysmal rupture occurred in 6 patients (5.3%). Aneurysmal rupture during surgery was not an exceptional event because it occurred in 19 to 40% of the procedures according to the series [8-9]. The operative conditions favoring aneurysmal rupture were the opening of the dura mater, cerebral retraction, and evacuation of a hematoma and dissection of the aneurysm [10]. Temporary clipping on the aneurysm or on the afferent artery allowed rapid control of bleeding. Blood loss was estimated at an average of 500ml. Temporary clipping of less than 5 minutes was associated with a deepening

of the anesthesia with boluses of hypnotics like Thiopental or Propofol. The duration of the temporary clamping should not exceed 20 minutes under penalty of an alteration of neurological prognosis at 3 months [11]. Postoperatively, arterial vasospasm occurred in 6 patients (5.3%) and determined cerebral ischemia. Early management included maintaining arterial hypertension with MAP between 100 and 120 mm/Hg, oxygenation or mechanical ventilation when the Glasgow score was less than or equal to 8 and administration of Nimodipine. This arterial vasospasm occurred in patients who had a high WFNS neurological grade, ie greater than or equal to III. The transcranial doppler, a non-invasive and renewable examination, allows daily monitoring of the evolution of the blood velocities of the Willis polygon arteries. Hydrocephalus in 6 patients (5.3%) is a common complication of MH and occurs in approximately 20% of patients [12]. It can be early or late and may be due to a CSF resorption disorder, clots in the Sylvius Aqueduct or the 4th ventricle. The care had brought in an external derivation of the CSF. The mortality rate of our serie is 7.1%. The importance of initial bleeding (P = 0.002) and the occurrence of arterial vasospasm (P = 0.003) were the main identified death factors. MH remains a serious condition. About 12% of patients died before any medical treatment [13]. One year after receiving aneurysmal treatment, 10% of patients died, 18% had severe and disabling sequelae, and only 20% of patients have no sequelae [14].

CONCLUSION

Meningeal hemorrhage by aneurysmal rupture is a serious pathology of sudden onset in young subjects. Surgical clipping is an effective way to prevent rebleeding. Perioperative anesthetic management focuses on the prevention and management of potential complications that are responsible for high morbidity and mortality. It will be in the continuity of neuro-resuscitation.

CONFLICT OF INTEREST

Authors declare no conflict of interest

REFERENCES

1. Brisman JL, Song JK, Newell DW. Cerebral aneurysms. *N Engl J Med* 2006; 355(9): 928-39.
2. Niewcamp DJ, Setz LE, Algra A, Linn FHH, De Rooij NK, Rinkel GJE. Changes in case fatality of aneurysmal subarachnoid hemorrhage over time, according to age, sex and region: a meta-analysis. *Lancet Neurol* 2009; 8(7): 635-42.
3. Marshman LAG. Cushing's response acute hypotension after subarachnoid hemorrhage. *Stroke* 1997; 28: 1450-55.
4. Feigin VL, Lawes CM, Bennett DA, Anderson CS. Stroke epidemiology: a review of population-based studies of incidence, prevalence and case-fatality in the late 20th century. *Lancet Neurol* 2003; 2(1): 43-53.

5. Lescot T, Abdenmour L, Allouane L, Puybasset L. Prise en charge des hémorragies méningées anévrysmales. *Le praticien en anesthésie réanimation* 2009, 13: 168-77.
6. Audibert G, Baumann A. Hémorragie sous arachnoïdienne anévrysmale. *Ann Fr anesth réanim* 2017; 3: 37-47.
7. Eng CC, Lam AM, Byrd S, Newell DW. The diagnosis and management of a perianesthetic cerebral aneurysmal rupture aided with transcranial Doppler ultrasonography. *Anesthesiology* 1993; 78(1): 191-4.
8. Batjer H, Samson D. Intraoperative aneurysmal rupture: incidence outcome, and suggestions for surgical management. *Neurosurgery* 1986; 18 (6): 701-7.
9. Fridriksson S, Saveland H, Jakobson KE, Edner G, Zygmunt S, Brandt L. Intraoperative complications in aneurysm surgery: a prospective national study. *J neurosurg* 2002; 96 (3): 515-22.
10. Houkin K, Kuroda S, Takahashi A, Takikawa S, Ishikawa T, Yoshimoto T. Intra-operative premature rupture of the cerebral aneurysms. Analysis of the cause and management. *Acta Neurochir (wien)* 1999; 141 (12): 1255-63.
11. Hindman BJ, Bayman EO, Pfisterer WK, Torner JC, Todd MM. No association between intraoperative hypothermia or supplemental protective drug and neurologic outcomes in patients undergoing temporary clipping during cerebral aneurysm surgery: findings from the intraoperative hypothermia for aneurysm surgery trial. *Anesthesiology* 2010; 112(1): 86-101.
12. Hasan D, Vermeulen M, Wijdicks E, Hijdra A, Van Gijn J. Management problems in acute hydrocephalus after subarachnoid hemorrhage. *Stroke* 1989; 20:747-1161.
13. Schievink WI, Wijdicks EF, Parisi JE, Piegras DG, Whisnant JP. Sudden death from aneurysmal subarachnoid haemorrhage. *Neurology* 1995 (5); 45:871-4.
14. Molyneux A, Ken R, Stratton I, Sandercok P, Clarke M, Shrimpton J. International subarachnoid aneurysm trial (ISAT) of neurosurgical clipping versus endovascular coiling in 2143 patient with ruptured intracranial aneurysms: a randomised trial. *Lancet* 2002; 360(9342): 1267-74.