

Isolated Involvement of Tongue in Oral Lichen Planus Mimicking Oral Candidiasis

Dr. Mudita Gupta¹, Dr. Kuldeep Verma², Dr. Saru Thakur³

¹Assistant Professor Department Of Dermatology, Venereology and Leprosy Indira Gandhi Medical College Shimla, Himachal Pradesh, India.

²Post graduate student Indira Gandhi Medical College Shimla, Himachal Pradesh, India.

³Post graduate student Indira Gandhi Medical College Shimla , Himachal Pradesh, India.

*Corresponding author

Dr. Mudita Gupta

Article History

Received: 31.08.2017

Accepted: 08.09.2017

Published: 30.09.2017



Abstract: Oral lichen planus (OLP) is a chronic inflammatory disease of unknown aetiology. Buccal mucosa is the commonest site involved, but the gingivae, tongue, floor of the mouth and retro molar pads may also be affected. OLP occurs more frequently than the cutaneous form and tends to have a persistent and resistant course. Lichen planus involving a single oral site is uncommon finding and only few cases have been reported in the literature. We report a case of oral lichen planus which was confined to tongue only. In our patient, erosive and plaque form coexisted. Patient was managed with oral disperse therapy for six weeks and significant improvement was noticed in the lesions.

Keywords: Oral lichen planus (OLP), inflammatory disease, Buccal mucosa

INTRODUCTION

Oral lichen planus (OLP) is a chronic inflammatory oral mucosal disease of unknown aetiology with a prevalence of 0.5-2.2% in the general population [1]. In contrast to cutaneous lichen planus (LP), OLP has a higher incidence especially in females, occur more frequently than the cutaneous forms and is more resistant to treatment [2]. Lichen planus involving a single oral site is uncommon. Only few cases of OLP have been reported in literature which has involved a single oral site like confined to the tongue[3],

gingiva [4] or lip [5]. Though tongue involvement in OLP is as high as 52 % [6], isolated involvement of tongue is rarely reported. We report an atypical case of erosive and plaque type oral lichen planus in a 23 year old female which was confined to dorsa of tongue, which was being misdiagnosed leading to delay in initiating the correct treatment.

CASE HISTORY

A 23 year female presented in dermatology OPD with a chief complaint of ulcerative lesions over the tongue from last 2 months. There was history of appearance of new pustular lesions over tip of the tongue from last 4 days. The lesions were extremely painful and restricted her oral intake also. There were no systemic complaints General physical examination and cutaneous examination was within normal limits. There was no other mucosal involvement. Patient had history of on and off constipation from last 1 year. In local examination, over dorsa of tongue, there was a single well to ill-defined white plaque of size 2x2 cm approximately with multiple well defined pustules of

size 0.1x0.1 cm and well to ill-defined erosions of size 0.1x0.1 cm to 1x2 cm approximately (Fig-1).

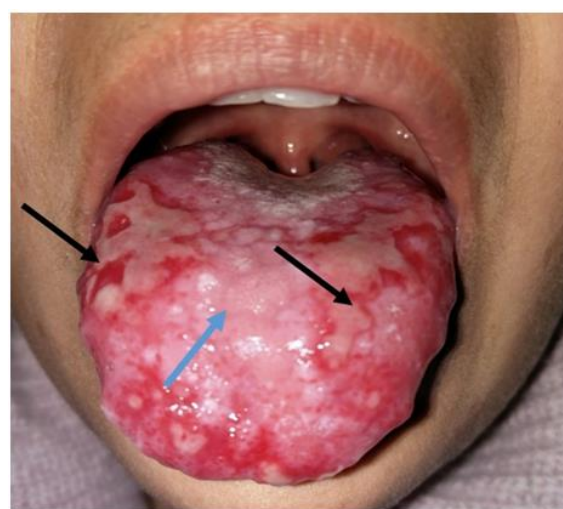


Fig-1: Erosions (black arrows) and plaques (blue arrow) on dorsum of tongue

Rest of the oral mucosa was normal and dental hygiene was adequate. Patient was suspected to be having oral candidiasis and a potassium hydroxide smear was prepared from lingual mucosa which was negative. But because of high index of suspicion she was prescribed oral itraconazole 100 mg twice a day for 2 weeks. On her follow up visit she was found to have no relief. No bacilli or hyphae could be seen on gram staining. Tzanck smear was negative for acantholytic cells and multinucleate giant cells. With a suspicion of some inflammatory mucositis a biopsy of the tongue was taken with the possibilities of erosive lichen planus, pustular psoriasis, Sweet's syndrome, Crohn's disease and Oral candidiasis. Biopsy showed moderately dense superficial perivascular lichenoid infiltrate of lymphocytes and plasma cells with irregular acanthosis and vacuolation of the basal layer. The dermoepidermal junction was focally infiltrated by lymphocytes and shows scattered necrotic keratinocytes (Fig-2).

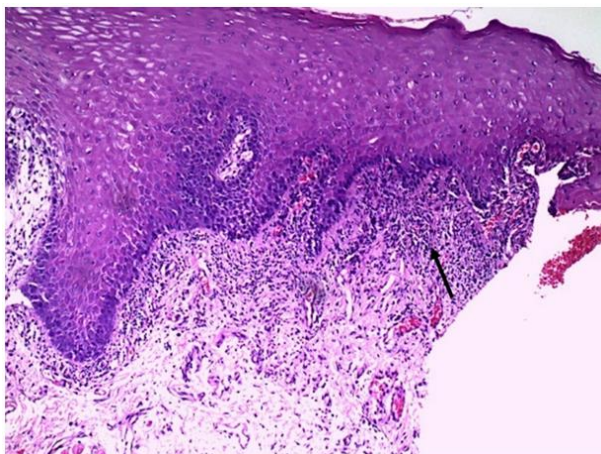


Fig-2: Histopathology (H&E stain 40X) Black arrow showing band like upper dermal lymphocytic infiltrate

Findings were consistent with Oral Lichen planus. Patient was started on topical steroids and tacrolimus. Dapsone in a dose of 100 mg was added along with symptomatic local anaesthetic benzocaine. Patient showed improvement at three weeks [Figure 3], topical steroids were discontinued while she was continued on daily dose of Dapsone and topical tacrolimus. At 6 weeks there was marked improvement as shown in figure (Fig-4).

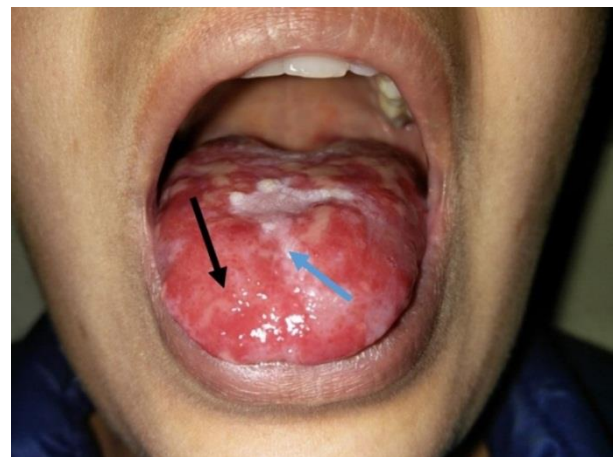

Fig-3: After three weeks of treatment erosions are reduced

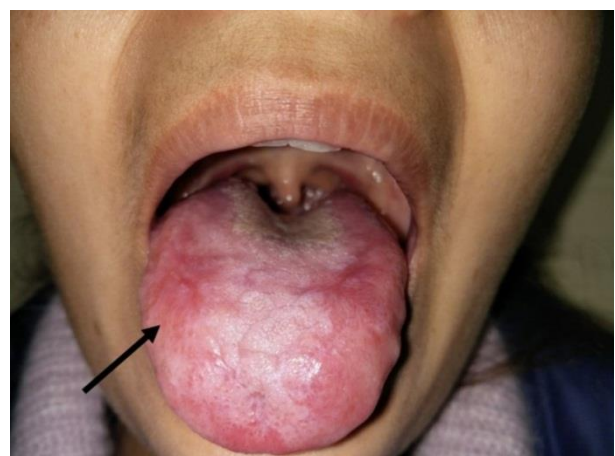

Fig-4: After 6 weeks of treatment black arrow shows only few residual types of erosion

DISCUSSION

Thieberg was the first one to identify the oral lesion of lichen planus. Oral LP (OLP) can be the sole clinical presentation of the disease or it can be accompanied by cutaneous or other mucosal manifestations including the genital area, gastrointestinal tract, and eyes. Other sites like scalp, nails, esophagus, and eyes are the less common associations seen.

Though thought to be of multifactorial origin the exact etiopathogenesis is not known. In a genetically predisposed individual various endogenous and exogenous triggers (e.g. trauma, friction due to sharp edge of tooth, cigarette smoke, tobacco chewing, etc.) exist. This leads to activation of cytotoxic T cells against the basal cells of the mucosa, which further increases adhesion molecules [7]. All these immunological changes lead to vacuolar degeneration, lysis of basal cells, and, ultimately, liquefaction of the basal cells [8].

Anderson described six clinical forms of OLP according to their clinical morphology, these are reticular, papular, plaque, atrophic, ulcerative, and bullous [5], but a simpler clinical classification given by Eisen [3] consists of 3 types of lesions: reticular(which included lacy, papular and plaque type), atrophic or erythematous type and erosive, including ulcerations and bullae. In OLP normally mixed pattern is seen. Overall, OLP is normally an under reported disease which is because the more common variants of the disease (reticular, papular and plaque type) are generally asymptomatic and often discovered incidentally during an oral examination. The relatively less common atrophic and erosive lesions frequently result in discomfort, pain and often restrict oral intake as was seen in our patient.

OLP normally has a multifocal involvement .i.e. multiple sites in oral mucosa are involved which are bilaterally symmetrical. The commonest site involved is the buccal mucosa in most of the studies [3]. Few studies report tongue to be the second common site involved in OLP [6] while other report gingiva [3] Rare sites of oral mucosal involvement are the floor of the mouth, soft palate and lips [3]. Isolated involvement of one site of oral mucosa is very rare. Gingiva has been the commonest single site reported with an incidence of as high as 8.6 % [3]. Sole involvement of lips has been reported by Petrusi *et al.* [1] and unilateral lichen planus was detected in 5.2 % of OLP patients in a study by Andreasen [5]. Though OLP involves the dorsa of tongue very commonly as a multifocal disease, isolated involvement is an uncommon finding and was seen in only 0.6 % of patients by Eisen *et al.* [3].

Reticulate pattern is very rarely seen on dorsum of tongue while plaque form is the commonest morphologic type reported. In our patient she had an isolated involvement of dorsum of tongue with mixed morphologic pattern of plaque, atrophy with erosions and pustular type.

Isolated tongue involvement with such morphologic patterns can be seen in oral candidiasis, pemphigus vulgaris and drug eruptions. KOH negative smear with lack of response to anti-fungal ruled out candidiasis. As there were no acantholytic cells so pemphigus was excluded. Histopathology was done to confirm the diagnosis. Our patient had a band of lymphocytic infiltrate with no parakeratosis in contrast to lesions of lichenoid drug eruptions which show parakeratosis with perivascular and periadnexal infiltrate.

OLP is a disease which is resistant to treatment and shows frequent remissions. Good oral hygiene is a prerequisite. Topical steroids and calcineurin inhibitors are prescribed as first line therapy. Topical retinoids,

steroid and cyclosporine rinses have also been tried. For recalcitrant therapy psoralens with ultraviolet A, griseofulvin and dapsone have been tried with variable results. Very resistant cases various immunosuppressive agents like systemic steroids, mycophenolate, azathioprine are required. Biologic agents like efalizumab may be required. In resistant painful erosions photodynamic therapy and lasers like diode, excimer and CO₂ have also been used [9,10]. Though OLP is resistant to treatment our case responded quite well to dapsone treatment and topical corticosteroids and calcineurin inhibitors.

CONCLUSION

OLP is fairly common autoimmune inflammatory disorder in general population which generally involves multiple sites. It is generally much easier to diagnose clinically if bilateral buccal mucosa depicts a classical reticular pattern with or without involvement of gingiva, tongue, palate or lips. Presence of classical lesions of Cutaneous Lichen Planus further aid in confirming the diagnosis of oral lichen planus. OLP involving a single oral site is an uncommon finding like in our case and a high index of suspicion is required to diagnose these cases. Tzank smear can be done in these patients as it helps to rule out other causes as well as help in keeping differential diagnosis for biopsy. Dapsone was used as a 1st line therapy in our case and patients responded well to Dapsone alone. Later patient was shifted to Topical tacrolimus ointment and she's under regular follow up without any new lesions.

REFERENCES

1. Petrucci M, De Benedittis M, Pasture L, Pannone G, Grassi FR, Serpico R. Isolated lichen planus of the lip. International journal of immunopathology and pharmacology. 2007 Jul;20(3):631-5.
2. Mollaoglu N. Oral lichen planus: a review. British Journal of oral and maxillofacial surgery. 2000 Aug 1;38(4):370-7.
3. Eisen D. The clinical features, malignant potential, and systemic associations of oral lichen planus: a study of 723 patients. Journal of the American Academy of Dermatology. 2002 Feb 28;46(2):207-14.
4. Scully C, El-Kom M. Lichen planus: review and update on pathogenesis. Journal of Oral Pathology & Medicine. 1985 Jul 1;14(6):431-58.
5. Andreasen JO. Oral lichen planus: I. A clinical evaluation of 115 cases. Oral Surgery, Oral Medicine, Oral Pathology. 1968 Jan 1;25(1):31-42.
6. Varghese SS, George GB, Sarojini SB, Vinod S, Mathew P, Mathew DG, Sebastian J, George A. Epidemiology of oral lichen planus in a cohort of south Indian population: a retrospective study. Journal of cancer prevention. 2016 Mar;21(1):55.

7. Lavanya N, Jayanthi P, Rao UK, Ranganathan K. Oral lichen planus: An update on pathogenesis and treatment. *Journal of oral and maxillofacial pathology: JOMFP*. 2011 May;15(2):127.
8. Carbone M, Arduino PG, Carozzo M, Gandolfo S, Argiolas MR, Bertolusso G, Conrotto D, Pentenero M, Brocchetto R. Course of oral lichen planus: a retrospective study of 808 northern Italian patients. *Oral diseases*. 2009 Apr 1;15(3):235-43.
9. Trehan M, Taylor CR. Low-dose excimer 308-nm laser for the treatment of oral lichen planus. *Archives of dermatology*. 2004 Apr 1;140(4):415-20.
10. Van der Hem PS, Egges M, Van der Wal JE, Roodenburg JL. CO₂ laser evaporation of oral lichen planus. *International journal of oral and maxillofacial surgery*. 2008 Jul 31;37(7):630-3.