

## Minimal Invasive Dynamic Hip Screw for Intertrochanteric Fractures

Sandeep Shrivastava<sup>1</sup>, Romil Rathi<sup>2</sup>, Sohael Khan<sup>3</sup>

<sup>1</sup>Professor and Unit Head, Department of Orthopaedics, Jawaharlal Nehru Medical College, Wardha, Maharashtra, India

<sup>2</sup>Assistant Professor, Department of Orthopaedics, Jawaharlal Nehru Medical College, Wardha, Maharashtra, India

<sup>3</sup>Assistant Professor and Consultant Spine Unit, Department of Orthopaedics, Jawaharlal Nehru Medical College, Wardha, Maharashtra, India

### \*Corresponding author

Romil Rathi

### Article History

Received: 10.09.2017

Accepted: 16.09.2017

Published: 30.09.2017



**Abstract:** Intertrochanteric fracture of femur is one of the most common fracture of the hip especially in elderly with osteoporotic bones, usually due to low energy trauma like simple falls. With rise in Osteoporosis and geriatric population the risk of getting intertrochanteric fracture is on rise. Rigid fixation with early mobilization of patients is the standard treatment. There is lot controversy about the choice of implant, between Dynamic Hip screw plate and the intra-medullary implants. The Intramedullary implants in treatment of Intertrochanteric fractures, are thought to be a superior choice because of minimal Invasiveness in its application, biomechanical stability and minimal loss of blood. For unstable fractures they are the gold standard now. But many studies still suggest that Dynamic hip screw fixation first introduced by Clawson in 1964 is still a gold standard for fixation of stable intertrochanteric fractures. To develop and evaluate role of minimal invasive approach for Dynamic Hip screw (MIDHS) for the treatment of stable intertrochanteric fracture. This is a prospective study of 28 patients of intertrochanteric fracture of OTA 31 - A1, A2 and Boyd's I, -II fracture and Evan's stable fracture who underwent treatment by MIDHS with 4 hole side Dynamic compression plate. They were operated with minimal invasive approach. Patients were reviewed immediate postoperatively and at one, two, three, four, six, and 12 months after fracture. They were evaluated for outcomes pertaining to approach, fixation and union. The mean length of incision was 4 cms, mean amount of blood loss.-75ml, and Mean time taken for completion of surgery was 42 minutes. The mean size of Hip screw was 85 mm, 4 DCP plate was used, Hip screw were mostly placed Centrally and Postero-inferior, Tip apex distance was within 5mm in 21 cases and >5mm in 7 cases. There was 1 case of DVT, no screw cut through and no infection. Mean fall in postoperative hemoglobin was 0.5 gm/dl. The Vas pain score was mean of 3.5 /10 after 24 hrs. Mean Time to mobilization to partial weight bearing was within 3 days. Mean radiological union time was 10.6 weeks and mean follow up is 48.4 weeks. MIDHS is a innovative improvised technique for Dynamic hip screw fixation with small wound size, low blood loss, low pain, requires less hospital stay, low hospital cost, allows early mobilization and have low incidence of wound infection. It is a very effective way of maintain the adherences to gold standard of Dynamic Hip Screw fixation for Stable Intertrochanteric fracture of femur.

**Keywords:** Intertrochanteric fracture, Dynamic hip screw, Minimal invasive

### INTRODUCTION

Intertrochanteric fractures are one of the commonest fractures around hip, especially in elderly age group with osteoporotic bones, usually due to low energy trauma like tripping & falling. The incidence of intertrochanteric fracture is rising because of increasing in life expectancy. By 2040 it is estimated to be doubled. Surgical reconstruction is now considered as the standard care for such fractures. The exception to this is when the patient's medical co-morbidity precludes surgery. Rigid

fixation with early mobilisation of patients is considered as the standard treatment [1-3].

Successful outcome of intertrochanteric fractures depends on many factors including the age of the patient, the patient's general health, time from fracture to treatment, concurrent medical treatment, the adequacy of treatment and stability of fixation [4]. The Intramedullary implants in treatment of Intertrochanteric fractures, are thought to be a superior choice because of minimal Invasiveness in its

application, biomechanical stability and minimal loss of blood. But evidence reveal that Dynamic hip screw (DHS) fixation, first introduced by Clawson in 1964, is the gold standard for fixation of stable intertrochanteric fractures [5-8]. Particularly for stable fracture patterns The DHS allows impaction at the fracture site, shorter operating time, with good bone healing and low rate of complication .However, the disadvantages of conventional DHS (CDHS) techniques are a large skin incision and more soft tissue dissection with greater blood loss. To overcome these, minimal invasive technique for DHS fixation would be an ideal option.

Evaluate Feasibility and Safety of of minimal invasive approach for Dynamic Hip screw (MIDHS) for the treatment of Intertrochanteric fracture of the femur.

### Objectives

- To evaluate feasibility in terms of length of Incision, utility & versatility of incision, and difficulties encountered.
- To evaluate safety in terms of loss of blood, duration of surgery, and- effectivity towards earlier rehabilitation.

### Study design

It is Prospective case based experimental study with minimal invasive dynamic hip screw technique as intervention for treatment of fracture of Inter trochanteric femur.

28 out of 153 patients with intertrochanteric fracture who came to conducted at Teritary Care University hospital between July 2008 to September 2009, were included.

### Inclusion criteria

Patients having IT fracture classified as OTA 31 - A1, -A2, Boyd & Griffith's- I ,-II or Evans' type I.

### Exclusion criteria

Patients having non- union, pathological fracture (other than osteoporosis) or previously failed Surgery for IT fractures. Out of total 153 patients of IT fracture, 37 met the inclusion criteria and 28 underwent treatment by MIDHS. Out of 28 patients 15 were females and 13 were males. The youngest was 22 years old and eldest being 97 years, with mean age being 63 years. Majority of the patients were between age group of 70-80 years.

### Technique

All Patients were underwent surgery under consents and counseling. They all were operated on the

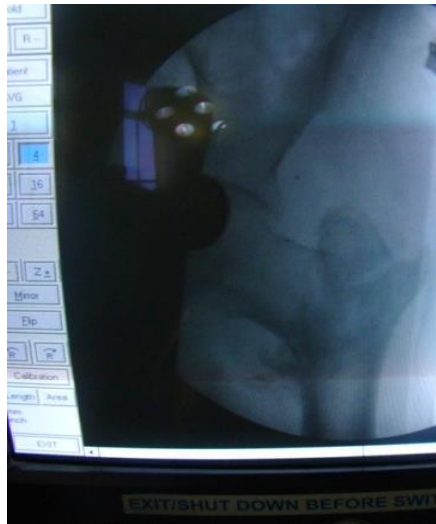fracture traction Table with affected limb in 0 degrees of flexion, 10-15 degrees of abduction and internally rotation. Closed reduction was achieved in all cases with adequate traction. In all cases C-Arm IITV was used (Fig. 1). Reductions were consider adequate within 10° of valgus on Antero-posterior view, Posterior angulation less than 5° on lateral view. It was ensured that proximal fragment was not inferior to the distal fragment on the AP view. The outer border of greater trochanter was marked, and with the help of a guide wire entry point was determined under fluoroscopic guidance, the proximal extent of incision is the skin entry point of the guide wire (Fig.2 & 3). A 4 cm line was drawn from the lower most skin marking, i.e. from the entry point of Guide wire (fig.4). A vertical incision is given and deep fascia cut in the same line, a bone lever is inserted just beneath the Vastus lateralis Muscle and inter-muscular plain is developed than the periosteum is incised and elevated and a lateral sleeve is developed sub-periosteally for plate insertion on the bone. .Incision is retracted obliquely & superiorly to ease the entry of guide wire and subsequently reamed with triple reamer over guide wire and tapped and dynamic hip screw inserted. A 4 hole plate is than slid over the screw almost perpendicular to the bone and fully loaded over the screw, with incision being retracted obliquely to facilitate its entry. It is than rotated a little to bring it parallel to bone, at the same tome the incision is retracted inferiorly to facilitate the plate insertion beneath the muscular plane and over the bone. The plate is gently tapped to sit on the bone and rests of cortical screws are placed (Fig.5 A, B, C,D , E , F).

The incision is than closed over the drain in two layers. The patient was mobilized as soon as possible, and most of them were sitting with legs dangling, bedside by 24 hrs and partial weight bearing within 72 hrs. The sutures were removed after 10-12 days. All patients' received bactericidal antibiotics for 3 days. They received analgesics for I/V 24 hrs and then SOS. They were followed up on completion of 3 weeks, 6 weeks and 12 weeks and then after 6 Months and then every 6 month. AP and lateral x rays were taken for all patients at each follow-up and for evaluated for fracture healing and implant position.

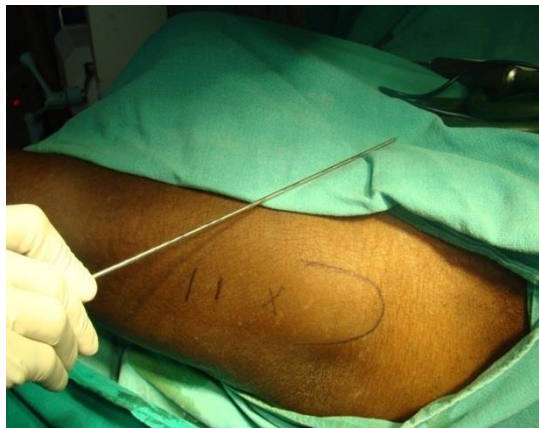### RESULTS AND OBSERVATION

Average radiological union time – 10.6 weeks

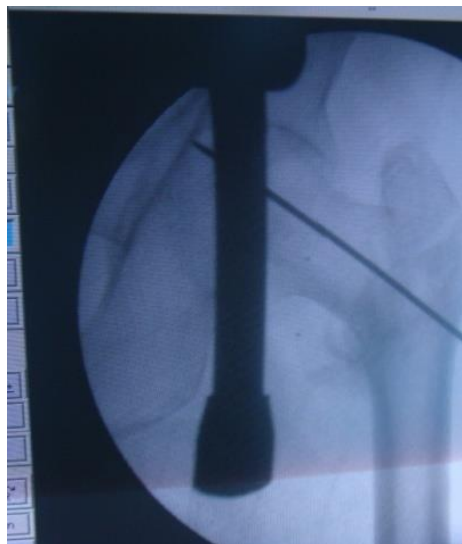Average follows up 48.4 weeks (Table a, b, c)



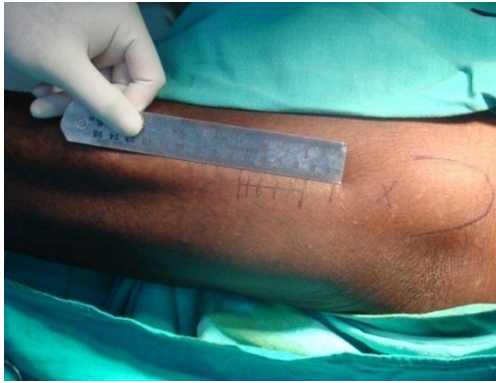**Fig-1: Fracture reduced by closed manipulation**



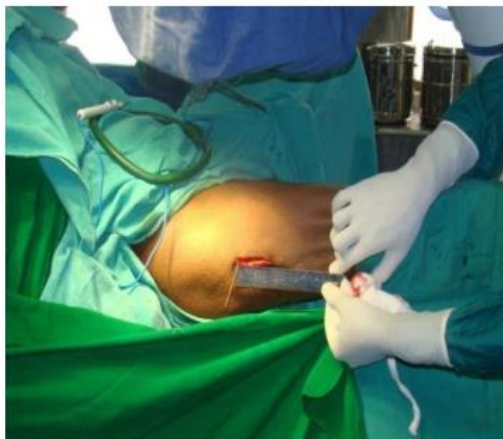**Fig-2: Marking of Greater Trochanter and Placement of Wire with entry point being marked**



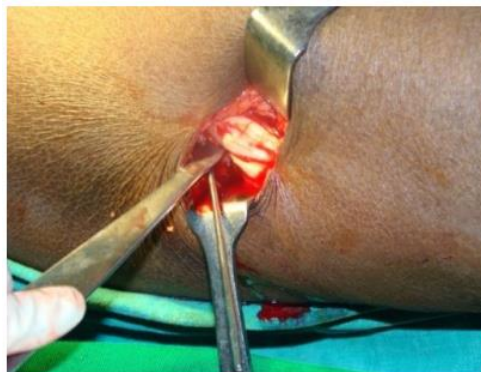**Fig-3: Central Position of guide wire**



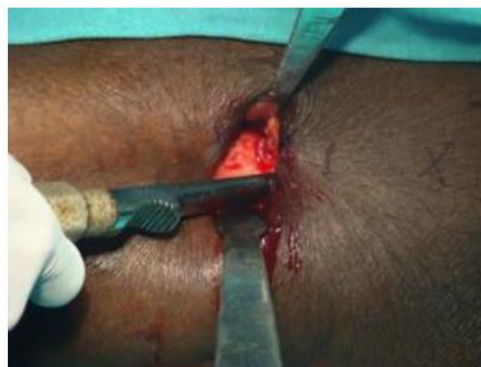**Fig-4:** The skin incision given extending distally upto 4 cm from entry point



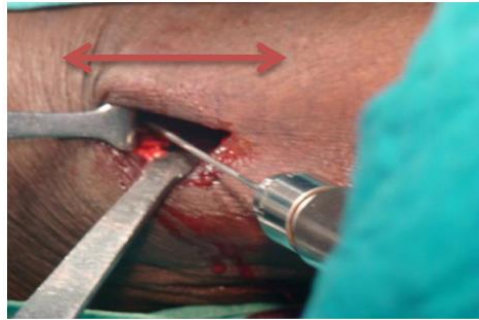
**Fig-5A:** 4 cm vertical incision



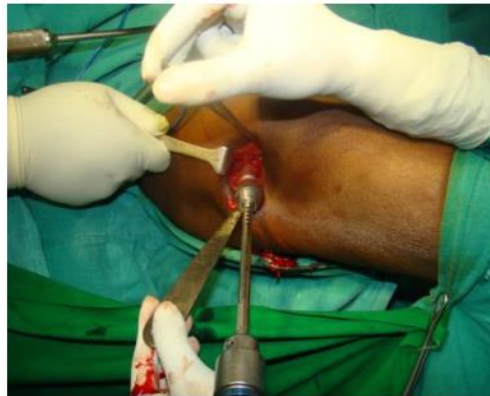**Fig-5B:** Sub-Muscle plane developed



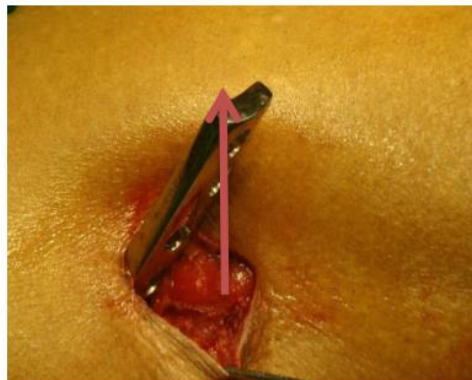**Fig-5C:** Periosteum is elevated



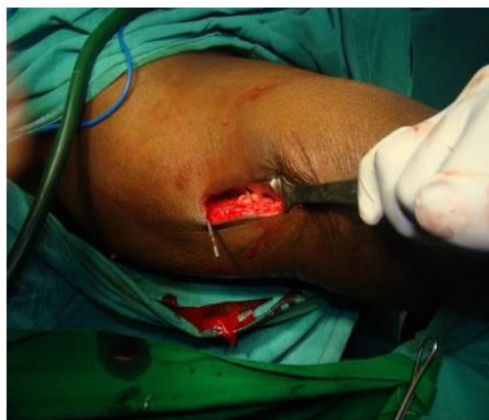**Fig-5D:** Incision retracted superiorly to ease the entry of guide wire



**Fig-5E:** Triple reamer over guide wire



**Fig-5F:** Plate slided, perpendicular to bone



**Fig-5G:** Plate slided in with the help of retractor which retracts the skin inferiorly thereby pushing the plate inside

**Table-A: Intraoperative observations**

Avg Length of incision	Avg Amount of blood loss.	Hole – 3- 4 screw	Total time taken
4cm	75 ml	4 HOLE	42 mins

**Table-B: Observation (complications)**

Position of screw	Tip apex distance	Cut through	Infection	DVT	Other complication
Central-25 Posterior inferior: 3	Within 5mm:21 >5mm:7	Nil	Nil	1	Nil

**Table-C: Post-operative observations**

Avg Post op Haemoglobin.	Avg Post op haematocrit	Avg Time to mobilisation and weight bearing post op.	Avg Length of hospital stay.	Total cost of treatment.	Prevalance of wound infection
1-1.5gm/dl loss		3days	4- 8 days	2000-3000	NIL

## DISCUSSION

For a femoral intertrochanteric fracture, many devices can result in stable fixation and achieve union. The advantage of the DHS was interfragmental compression effect with a high union rate.

According to study Yih-Shiunn Lee *et al.* [9] a minimally invasive technique can offer many advantages. Lower blood loss can decrease the need for blood transfusion. In general, total analgesic use in the first three postoperative days was less in the minimally invasive group. Decreased drug use and costs may make the technique beneficial to both the patient and the hospital. There was no significant difference in the visual analogue pain level between the two groups in the first two days. However, on days three and four, there was a significantly higher pain score in the conventional group. So they concluded that the minimally invasive technique as opposed to conventional technique has smaller wound size, lower pain level, and lower blood loss. Hospital stay and total analgesic use are decreased with a benefit to the patient and reduction in hospital cost.

Michael ho *et al.* [10] in a study of minimal invasive dynamic hip screw for fixation of hip fracture found that there was no difference in the time from surgery to mobilization and weight bearing postoperatively, position of the lag screw of the DHS device in the femoral head and the tip–apex distance. On the other hand, there were significant differences in the duration of surgery and length of hospital stay between the two cohorts of patients. They concluded that minimally invasive DHS requires less operating time, reduces the amount of intraoperative blood loss,

and allows patients to be discharged earlier.

In our study the average hemoglobin level drop showed significantly less and the average hospital stay was smaller in the MIDHS group. The visual analogue pain scores did not significantly dropped on the first two postoperative days. However, patients in the MIDHS group had lower pain scores on days three and four. The average time from surgery to mobilization and weight bearing postoperatively was also less in MIDHS patients i.e. 3 days so average hospital stay was also less i.e. 4-8 days. The duration of surgery was significantly less i.e. average 42 minutes and tip – apex distance was within normal range in almost all the patients. MIDHS also offer better clinical outcome at no extra expense. Its is reasonable and effective against rotating, shearing and varus stress force of the fracture.

## CONCLUSION

MIDHS is a conventional technique with small wound size, low blood loss, requires less hospital stay, low hospital cost, less no of analgesic used by patient post operatively, allows early mobilization and have low incidence of wound infection. It provides possibility of implanting the internal fixator with minimal incision.

## REFERENCE

1. Luger EJ, Arbel R, Eichenblat MS, Menachem A, Dekel S. Femoral notchplasty in the treatment of malunited intercondylar eminence fractures of the tibia. *Arthroscopy: The Journal of Arthroscopic & Related Surgery.* 1994 Oct 1;10(5):550-1.
2. Kaufer H, Matthews LS, Sonstegard D. Stable Fixation of Intertrochanteric Fractures: A

- Biomechanical Evaluation. JBJS. 1974 Jul 1;56(5):899-907.
3. Kyle RF, Gustilo RB, Premer RF. Analysis Of 622 Intertrochanteric Hip-Fractures-Retrospective And Prospective-Study. Journal Of Bone And Joint Surgery-American Volume. 1979 Jan 1;61(2):216-21.
  4. Chapuy MC, Arlot ME, Duboeuf F, Brun J, Crouzet B, Arnaud S, Delmas PD, Meunier PJ. Vitamin D3 and calcium to prevent hip fractures in elderly women. New England journal of medicine. 1992 Dec 3;327(23):1637-42.
  5. Curtis MJ, Jinnah RH, Wilson V, Cunningham BW. Proximal femoral fractures: a biomechanical study to compare intramedullary and extramedullary fixation. Injury. 1994 Mar 1;25(2):99-104.
  6. Haleem S, Lutchman L, Mayahi R, Grice JE, Parker MJ. Mortality following hip fracture: trends and geographical variations over the last 40 years. Injury. 2008 Oct 31;39(10):1157-63.
  7. Jones HW, Johnston P, Parker M. Are short femoral nails superior to the sliding hip screw? A meta-analysis of 24 studies involving 3,279 fractures. International orthopaedics. 2006 Apr 1;30(2):69-78.
  8. Anglen JO, Weinstein JN, American Board of Orthopaedic Surgery Research Committee. Nail or plate fixation of intertrochanteric hip fractures: changing pattern of practice: a review of the American Board of Orthopaedic Surgery Database. JBJS. 2008 Apr 1;90(4):700-7.
  9. Lee YS, Huang HL, Lo TY, Huang CR. Dynamic hip screw in the treatment of intertrochanteric fractures: a comparison of two fixation methods. International orthopaedics. 2007 Oct 1;31(5):683-8.
  10. Ho M, Garau G, Walley G, Oliva F, Panni AS, Longo UG, Maffulli N. Minimally invasive dynamic hip screw for fixation of hip fractures. International orthopaedics. 2009 Apr 1;33(2):555-60.