

Intestinal Obstruction after Cesarean Delivery: Consider Cecal Volvulus: A Case Report

Omar Benour^{1*}, Mohamed Al Amine EL Mouden¹, Anas Barchid¹, Walid Fadil¹, Aymane Jbilou¹, Anas Ahallat¹, Younes Aggouri¹, Said Aitlaalim¹

¹Department of General Surgery, University Hospital Center, Tangier, Morocco

DOI: [10.36347/sajs.2023.v09i08.002](https://doi.org/10.36347/sajs.2023.v09i08.002)

| Received: 06.06.2023 | Accepted: 14.07.2023 | Published: 04.08.2023

*Corresponding author: Omar Benour

Department of General Surgery, University Hospital Center, Tangier, Morocco

Abstract

Case Report

Cecal volvulus is a rare cause of intestinal obstruction. It is diagnosed after the realization of an abdominal CT scan in front of an intestinal obstruction syndrome. The reference treatment is surgery. We present a case of a young patient with intestinal obstruction on a cecal volvulus. A surgical exploration showed a caecum bascule without signs of complication. A right hemicolectomy was performed.

Keywords: Volvulus, caecum, occlusion, case report.

Copyright © 2023 The Author(s): This is an open-access article distributed under the terms of the Creative Commons Attribution 4.0 International License (CC BY-NC 4.0) which permits unrestricted use, distribution, and reproduction in any medium for non-commercial use provided the original author and source are credited.

INTRODUCTION

Cecal volvulus is a rotation of the cecum around its mesenteric axis, which contains its right lower colic pedicle, often resulting from an embryonic anomaly of right colon fixation [1]. It is an extremely rare condition, with an estimated incidence of 2.8 to 7.1 cases per million each year [2]. It often presents as an acute picture of small bowel obstruction and accounts for 1% of all intestinal obstructions [2]. The diagnosis is confirmed by CT scan, and surgical treatment is the standard approach, involving a right hemicolectomy to prevent recurrence. We report a clinical case of a 32-year-old female patient who underwent surgery in our facility for an occlusion caused by cecal volvulus.

PATIENT AND OBSERVATION

A 32-year-old female patient, who has a medical background of hypothyroidism and struggles with adhering to treatment, underwent a cesarean section due to fetal distress. This occurred 48 hours prior to the onset of an obstructive syndrome characterized by the complete halt of intestinal movement accompanied by episodes of vomiting. Upon conducting an abdominal examination, it was observed that the abdomen had become distended uniformly. Palpation of the abdomen revealed the presence of a firm and resonant mass in the periumbilical area, accompanied by overall tenderness but devoid of signs indicating peritoneal irritation. Laboratory analyses displayed indications of renal dysfunction, including

functional renal failure, as well as lower-than-normal levels of sodium and potassium in the blood.

The White Blood Cell count and C-reactive protein levels, however, fell within the normal range. The plain radiography depicted a distended portion of the colon on the left side of the abdomen, filled with gas. Subsequently, an abdominal CT scan revealed either a hyperflexion or a bascule of the caecum, ruling out the possibility of torsion. The caecum, grossly inflated with air, was inverted and positioned in the upper left quadrant of the abdominal cavity (figure 1). An urgent laparotomy was conducted, leading to a surgical exploration that unveiled the absence of any contents in the right iliac fossa. A cecal volvulus affecting the ascending colon and terminal ileum was identified (refer to figure 2). Fortunately, no signs of intestinal necrosis or perforation were observed. The volvulus was manually untwisted (figure 3), followed by a right hemicolectomy and the creation of a manual ileo-transverse anastomosis (figure 4). Following the procedure, her recovery progressed smoothly without any complications, and she was discharged on the sixth day after the operation without any notable incidents.

Citation: Omar Benour, Mohamed Al Amine EL Mouden, Anas Barchid, Walid Fadil, Aymane Jbilou, Anas Ahallat, Younes Aggouri, Said Aitlaalim. Intestinal Obstruction after Cesarean Delivery: Consider Cecal Volvulus: A Case Report. SAS J Surg, 2023 Aug 9(8): 653-655.

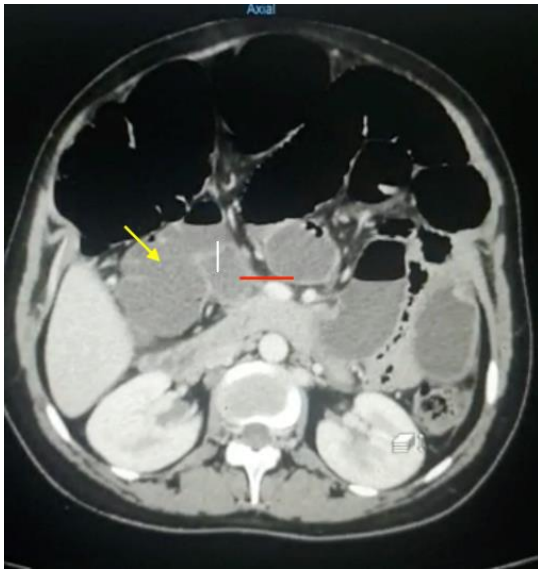


Figure 1: CT scan image of cecum bascule (yellow arrow: caecum, red arrow: last loop of intestine)

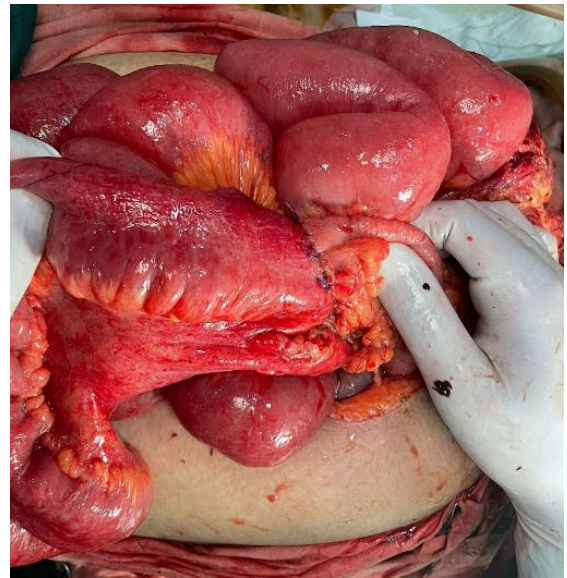

Figure 4: Manual ileo transvers anastomosis

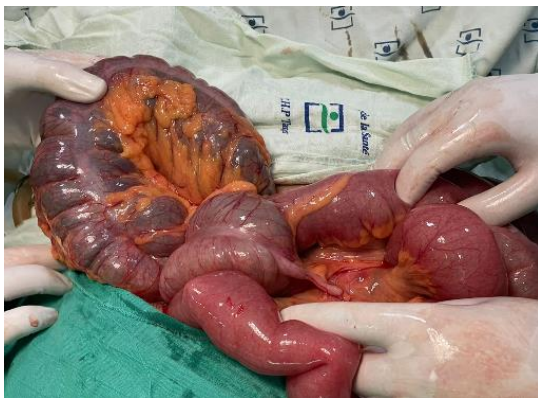

Figure 2: Cecum folded on itself

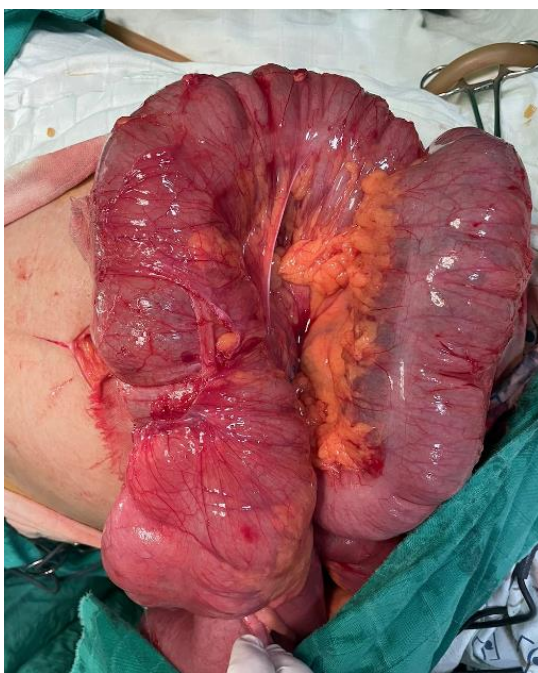


Figure 3: Manual untwisting of volvulus

DISCUSSION

Caecal volvulus occurs due to the twisting (referred to as torsion) or forward folding (known as "bascule") of an enlarged, inadequately anchored, and excessively mobile cecum. Torsion involves the axial rotation of the cecum, terminal ileum, and ascending colon, constituting 90% of all cases of caecal volvulus. On the other hand, caecal bascule refers to the anterior folding of the ascending colon and represents 10% of all instances of caecal volvulus. This is the case of our patient who had a caecal bascule. The excessive mobility of the cecum is due to an incomplete embryological rotation of the intestine or to a lack of attachment of the ascending colon to the posterior parietal peritoneum [3]. The main predisposing factor is female gender [3], likely due to adhesions resulting from pelvic surgery and the rapid changes in uterine volume during pregnancy [4]. Our patient presented with cecal volvulus 2 days after a cesarean delivery. Other predisposing factors have been described, such as an abdominal mass, calcified lymph node, or peritoneal adhesion of non-gynecologic origin [5].

Clinically, cecal volvulus typically presents as an obstructive syndrome characterized by the cessation of stool and gas passage and vomiting. Physical examination typically reveals diffuse abdominal distension, sometimes with right-sided upper abdominal distension asymmetry. In cases of delayed diagnosis, the condition may progress to intestinal necrosis with perforation and a frank presentation of generalized peritonitis [6]. Abdominal radiography permits diagnosis in 70% of cases by 3 typical signs: cecum dilatation, a single air–fluid level in the right lower quadrant, and absence of gas in the colon. The diagnosis is confirmed by performing an abdominal CT scan, which also allows for the detection of complications such as necrosis or perforation. A colonoscopy may be performed in the absence of signs

of ischemia for therapeutic purposes, such as detorsion, but recurrence rates are estimated to be as high as 50% of cases [7]. Surgery remains the standard treatment for cecal volvulus, with several therapeutic options available. Typically, a right hemicolectomy with ileotransverse anastomosis is performed, but manual detorsion with cecopexy may be considered despite the high risk of recurrence. Zabeirou *et al.*, reported a case of cecal volvulus treated with manual detorsion and fixation of the cecum, with a follow-up of 23 months without recurrence [8].

CONCLUSION

When the cecum, which is capable of movement, twists around its mesentery, it results in a condition known as volvulus of the cecum. Despite the absence of specific clinical indicators, the diagnosis is often postponed. An abdominal CT scan is the primary diagnostic tool for identifying the condition. Surgical intervention is the sole remedy available. The patient is satisfied with the treatment.

Competing interests

The authors declare no competing interests.

Informed consent

The patient has given informed consent.

REFERENCES

- O'Mara, C. S., Wilson Jr, T. H., Stonesifer, G. L., & Cameron, J. L. (1979). Cecal volvulus: analysis of 50 patients with long-term follow-up. *Annals of surgery*, 189(6), 724.
- Bandurski, R., Zaręba, K., & Kędra, B. (2011). Cecal volvulus as a rare cause of intestinal obstruction. *Polski Przegląd Chirurgiczny*, 83(9), 515-517.
- O'Mara, C. S., Wilson Jr, T. H., Stonesifer, G. L., & Cameron, J. L. (1979). Cecal volvulus: analysis of 50 patients with long-term follow-up. *Annals of surgery*, 189(6), 724.
- Harer Jr, W. B., & Harer Sr, W. B. (1958). Volvulus Complicating Pregnancy And puerperium: report of three cases and review of literature. *Obstetrics & Gynecology*, 12(4), 399-406.
- Frank, A. J., Goffner, L. B., Fruauff, A. A., & Losada, R. A. (1993). Cecal volvulus: the CT whirl sign. *Abdominal Radiology*, 18, 288-289.
- Donhauser, J. L., & Atwell, S. (1949). Volvulus of the cecum: with a review of one hundred cases in the literature and a report of six new cases. *Archives of Surgery*, 58(2), 129-148.
- Orchard, J. L., Mehta, R., & Khan, A. H. (1984). The use of colonoscopy in the treatment of colonic volvulus: three cases and review of the literature. *American Journal of Gastroenterology (Springer Nature)*, 79(11).
- Zabeirou, A. A., Belghali, H., Souiki, T., Majdoub, K. I., Toughrai, I., & Mazaz, K. (2019). Acute cecal volvulus: A diagnostic and therapeutic challenge in emergency: A case report. *Annals of Medicine and Surgery*, 48, 69-72.