

Benign Versus Malignant Cervical Lymphadenopathy on Ultrasound and Doppler- A Case Series

Dr. Jayesh Sunil Ajwani¹, Dr. Sanjay M. Khaladkar², Dr. Foram Doshi³

¹Post-Graduate Resident, Department of Radio-Diagnosis, Dr. D.Y. Patil Medical College, Dr. D. Y. Patil Vidyapeeth, Pimpri, Pune India

²Professor, Department of Radio-Diagnosis, Dr. D.Y. Patil Medical College, Dr. D. Y. Patil Vidyapeeth, Pimpri, Pune India

³Post-Graduate Resident, Department of Radio-Diagnosis, Dr. D.Y. Patil Medical College, Dr. D.Y. Patil Vidyapeeth, Pimpri, Pune India

Original Research Article

*Corresponding author
Dr. Sanjay M. Khaladkar

Article History

Received: 19.10.2017

Accepted: 15.11.2017

Published: 30.11.2017



Abstract: A prospective study was conducted on 50 patients for a period of two years at Dr.D.Y.Patil Medical College, Hospital and Research Centre, Pimpri on Aloka Arietta S 60 USG machine to differentiate between malignant and benign cervical lymphadenopathy by B-mode, colour doppler and power doppler. Out of total 50 patients, 30 were males (60%) and 20 (40%) were females. The mean age for malignant group of lymph nodes was 42.89 and for benign group of lymph nodes were 31.22. Malignant group of lymph nodes accounted for 36% and benign group of lymph nodes accounted for 64% of cases. Maximum number of lymph nodes were in the upper cervical region (42.5%), followed by supraclavicular region (17.50%). Malignant group of lymph nodes were those occurring from head and neck malignancies (55.55%), lymphoma (16.67%) and unknown primary (27.78%). Benign group of lymph nodes were due to specific infections namely tuberculosis (50%) and those occurring from non-specific infection (50%). Malignant group of lymph nodes had a mean S/L ratio of 0.63 and maximum number was round in shape (77.78%). Benign group of lymph nodes had a mean S/L ratio of 0.50. Benign group of lymph nodes were oval in shape in 90.62%. Maximum number of malignant lymph nodes had ill-defined margins (66.67%) with absence of fatty hilum (72.23%). Maximum number of benign lymph nodes had well-defined margins (93.75%) and absence of fatty hilum (53.12%). Maximum number of malignant lymph nodes were heterogeneous in echotexture (61.12%) followed by hypoechoic (33.34%). Maximum benign lymph nodes were heterogeneous in echotexture (53.12%) followed by hypoechoic (46.87%). Necrosis was present in 77.78% of malignant lymph nodes. In benign lymph nodes, necrosis was present in 50% cases. Majority of malignant group of lymph nodes showed mixed vascularity (77.78%). All reactive lymph nodes showed hilar vascularity while tuberculous lymph nodes were avascular.

Keywords: Cervical lymphadenopathy, Benign Cervical Lymph Nodes, Malignant Cervical Lymph Nodes, Echogenic Fatty Hilum.

INTRODUCTION

Ultrasound, Colour Doppler and Power Doppler are extremely useful in detection and characterization of cervical lymph nodes. B-mode ultrasound is useful in studying size, shape, distribution, presence or absence of echogenic fatty hilum, margins, presence of necrosis, matting and calcification. Colour Doppler and Power Doppler are useful in assessing vascularity of lymph nodes which can be peripheral, central, mixed, hilar or no-vascularity. USG has advantage over CT and MRI as it is readily available, cheaper, and non-invasive and can be repeated for

follow-up with no radiation. Also it can detect and study architecture of smaller lymph nodes less than 5 mm in size which becomes difficult on CT and MRI. Based on features of cervical lymph nodes on B-mode and Doppler, differentiation between benign and malignant cervical lymph nodes is possible [1, 2]. Differentiation between benign and malignant cervical lymph nodes becomes difficult at times and biopsy correlation is needed. USG guided lymph node biopsy is easier. USG when combined with F.N.A.C. has a sensitivity and specificity of 98% and 95% respectively [1, 2].

MATERIALS AND METHODS

The prospective study was carried on 50 patients of all age groups and both sexes, in the Department of Radio-diagnosis at Dr. D.Y. Patil Medical College, Hospital and Research Centre, Pimpri over a period of 2 years, in patients who were referred for USG of neck. Clearance of Institute Ethical Committee was obtained prior to the start of the study. All cases of cervical lymph nodes of all age groups and both sexes were included. Post-operative and post-radiotherapy patients with cervical lymphadenopathy were excluded. Linear transducer (frequency 5-13 MHz) and Convex transducer (frequency 1-5 MHz) were used for assessment of all cervical lymph nodes and deeper lymph nodes respectively. Patient was

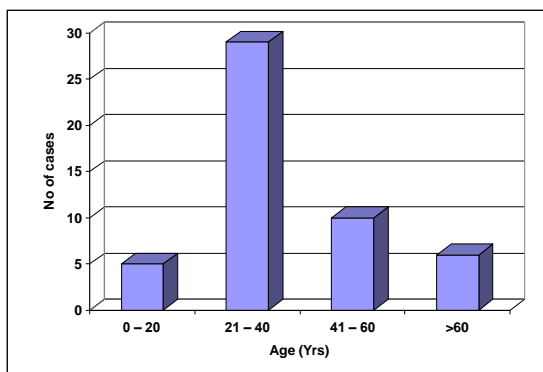
examined in supine position with neck extended with soft pad placed under the patient's shoulders and lower neck for support. Assessment of lymph nodes in transverse and longitudinal planes was done in submental area (region 1), Submandibular area(region 2), parotid (region 3), upper cervical(region 4), Middle cervical(region 5), lower cervical(region 6), supraclavicular fossa(region 7), and posterior triangle(region 8). Pattern of vascularity (hilar, peripheral, mixed, and apparently avascular) was assessed. R.I, P.I. was assessed in prominent intranodal vessels after making angle correction of 45- 60 degrees.

OBSERVATIONS AND RESULTS

Table-1: Age wise distribution of cases in study group

Age (Yrs)	No of cases	Percentage
0 – 20	5	10
21 – 40	29	58
41 – 60	10	20
>60	6	12
Total	50	100

Bar diagram showing age wise distribution of cases in study group.



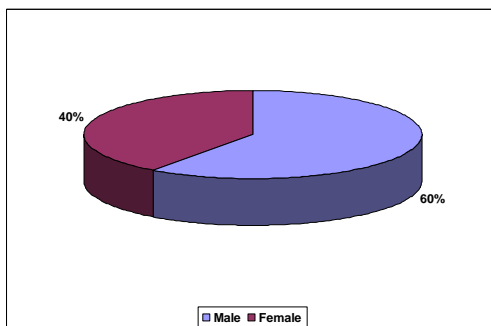
Maximum percentage of patients were in the age group of 21-40 years (58%), followed by 41-60

years (20%), >60 years(12%). 0-20 years age group was least affected(10%).

Table-2: Sex wise distribution of cases in study group

Sex	No of cases	Percentage
Male	30	60
Female	20	40
Total	50	100

Pie diagram showing sex wise distribution of cases in study group.

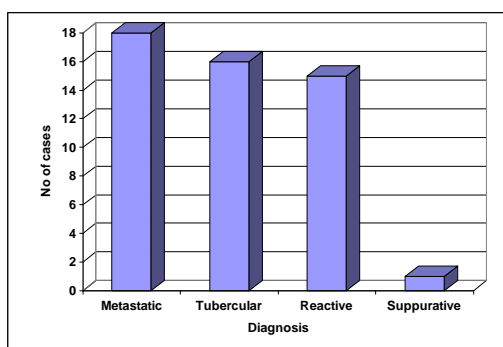


Males accounted for (60%) of cases whereas females accounted for (40%) of cases.

Table-3: Diagnosis wise distribution of cases in study group

Diagnosis	No of cases	Percentage
Metastatic	18	36
Tubercular	16	32
Reactive	15	30
Suppurative	1	2
Total	50	100

Bar diagram showing diagnosis wise distribution of cases in study group.



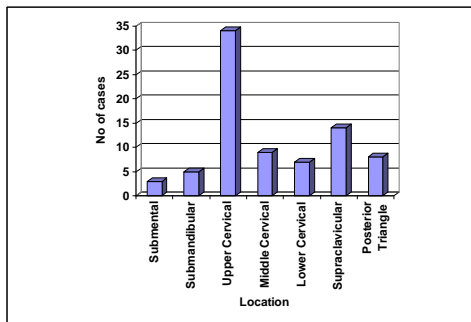
Out of total of 50 cases in our study, the maximum number of cases were metastatic (36%), followed by tubercular (32%), reactive (30%) and only

a single case of suppurative lymphadenitis was seen (2%).

Table-4: Location wise detection of lymph nodes in study group

Location	No of Lymph nodes	Percentage
Submental	3	3.75
Submandibular	5	6.25
Upper Cervical	34	42.50
Middle Cervical	9	11.25
Lower Cervical	7	8.75
Supraclavicular	14	17.50
Posterior Triangle	8	10
Total	80	100

Bar diagram showing location wise detection of lymph nodes in study group.



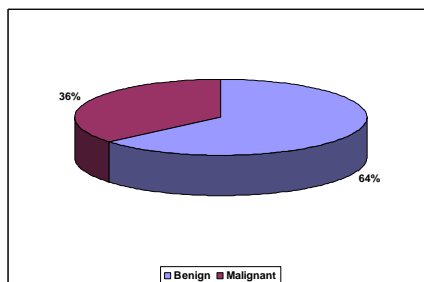
The maximum number of lymph nodes was found in the upper cervical region (42.5%) followed by supraclavicular (17.5%) then in the middle cervical region (11.25%), posterior triangle (10%), lower

cervical region (8.75%), submandibular (6.25%) and least number of lymph nodes was seen in the submental region.

Table-5: Outcome wise distribution of cases by USG in study group

Outcome	No of cases	Percentage
Benign	32	64
Malignant	18	36
Total	50	100

Pie diagram showing outcome wise distribution of cases by USG in study group.

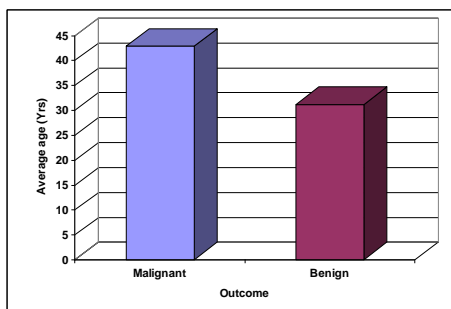


Out of 50 cases, benign cases accounted for (64 %) and malignant cases accounted for (36%) of total cases.

Table-6: Comparison of age according to outcome in study group

Parameter	Malignant (n=18)		Benign (n=32)		t Value	P Value
	Mean	SD	Mean	SD		
Age (Yrs)	42.89	16.93	31.22	12.21	2.82	0.007

Bar diagram showing comparison of age according to outcome in study group



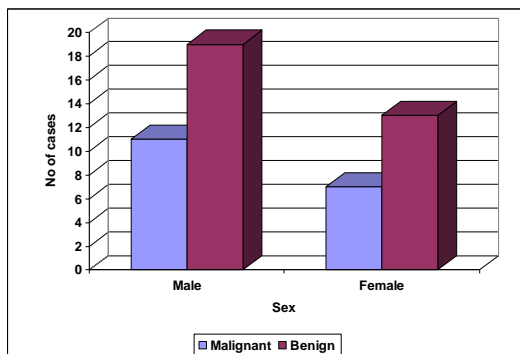
Mean age for cases of benign lymph nodes was 42.89 and mean age for cases of malignant lymph nodes was 31.22

Table-7: Association between sex and outcome in study group

Sex	Malignant	Benign	Total
Male	11	19	30
Female	7	13	20
Total	18	32	50

Chi-square = 0.014, P=0.90

Bar diagram showing association between sex and outcome in study group.

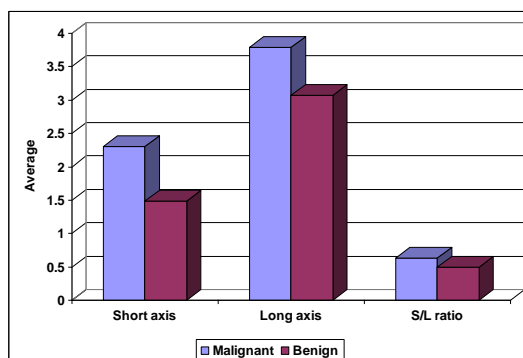


Males accounted for (59.37%) of benign cases and (61.12%) malignant cases whereas females accounted for (40.62%) benign cases and (38.89%) malignant cases.

Table-8: Comparison of short, long and S/L ratio according to outcome in study group

Parameter	Malignant (n=18)		Benign (n=32)		t Value	P Value
	Mean	SD	Mean	SD		
Short axis	2.30	0.94	1.49	0.89	3.03	0.004
Long axis	3.79	1.69	3.07	1.70	1.44	0.16
S/L ratio	0.63	0.15	0.50	0.14	3.20	0.002

Bar diagram showing comparison of short, long and S/L ratio according to outcome in study group

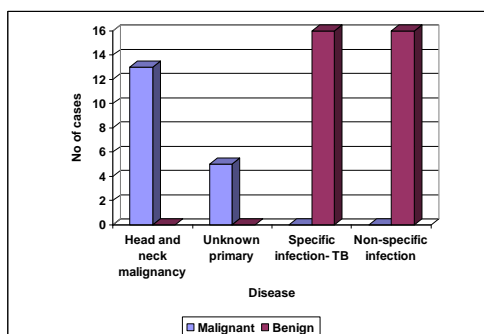


The mean short to long axis ratio of benign cases was 0.50 with a standard deviation of 0.14 and mean for malignant cases was 0.63 with a standard deviation of 0.15.

Table-9: Association between spectrum of disease and outcome in study group

Disease	Malignant	Benign	Total
Known primary-	13	0	13
(a)Head and neck malignancy	10		
(b)Lymphoma	3		
Unknown primary	5	0	5
Specific infection- TB	0	16	16
Non-specific infection	0	16	16
Total	18	32	50

Bar diagram showing association between spectrum of disease and outcome in study group.



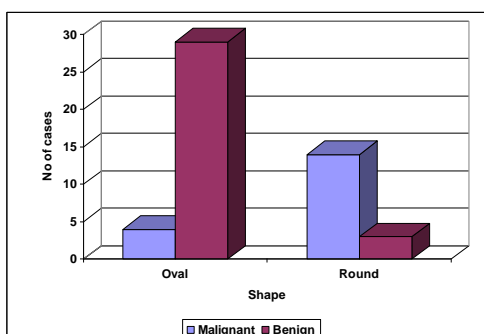
- In malignant cases head and neck cancer accounted for (72.23%) of cases whereas (27.78%) of cases were arising from an unknown primary.
- In benign cases results were equivocal (50%) cases were due to tuberculosis and (50%) cases were due to a non-specific infection.

Table-10: Association between shape of lymph nodes and outcome in study group

Shape	Malignant	Benign	Total
Oval	4	29	33
Round	14	3	17
Total	18	32	50

Chi-square = 24.02, P<0.0001

Bar diagram showing association between shape of lymph nodes and outcome in study group.



90.62% (n=29) cases of benign lymph nodes were oval in shape and 9.37% (n=3) were round in shape. 77.78% (n=14) cases of malignant lymph nodes

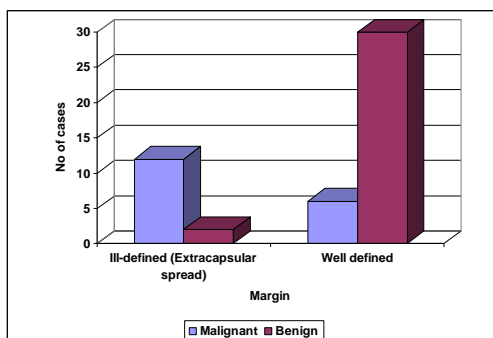
were round in shape and 22.23% (n=4) were oval in shape.

Table-11: Association between margin and outcome in study group

Margin	Malignant	Benign	Total
Ill-defined(Extracapsular spread)	12	2	14
Well defined	6	30	36
Total	18	32	50

Chi-square = 20.86, P<0.0001

Bar diagram showing association between margin and outcome in study group.



93.75% (n=30) cases of benign lymph nodes had well-defined margins and 6.25% (n=2) had ill-defined margins. 66.67% (n=12) cases of malignant

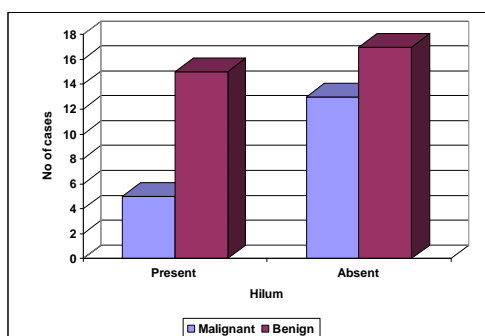
lymph nodes had ill-defined margins/ extracapsular spread and 33.34% (n=6) cases had well-defined margins.

Table-12: Association between Hilum and outcome in study group

Hilum	Malignant	Benign	Total
Present	5	15	20
Absent	13	17	30
Total	18	32	50

Chi-square = 1.75, P=0.19

Bar diagram showing association between Hilum and outcome in study group.



- 27.78% (n=5) cases of malignant lymph nodes showed presence of fatty hilum and 72.23% (n=13) cases showed absence of fatty hilum.

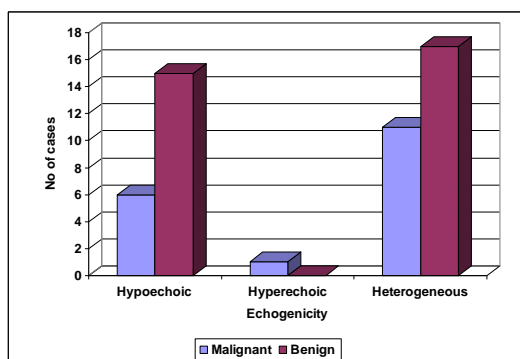
- 46.87% (n=15) cases of benign lymph nodes showed presence of fatty hilum and 53.12% (n=17) cases showed absence of fatty hilum.

Table-13: Association between echogenicity and outcome cases in study group

Echogenicity	Malignant	Benign	Total
Hypoechoic	6	15	21
Hyperechoic	1	0	1
Heterogeneous	11	17	28
Total	18	32	50

Chi-square = 2.41, P>0.05

Bar diagram showing association between echogenicity and outcome cases in study group



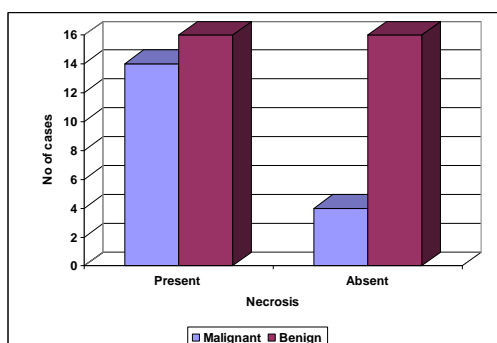
- 61.12% (n=11) cases of malignant lymph nodes were heterogeneous in echotexture followed by 33.34% (n=6) cases which were hypoechoic and 5.56% (n=1) cases were hyperechoic.
- 53.12% (n=17) cases of benign lymph nodes were heterogeneous, followed by 46.87% (n=15) cases which were hypoechoic and none of the cases were hyperechoic.

Table-14: Association between necrosis and outcome in study group

Necrosis	Malignant	Benign	Total
Present	14	16	30
Absent	4	16	20
Total	18	32	50

Chi-square = 3.70, P=0.054

Bar diagram showing association between necrosis and outcome in study group



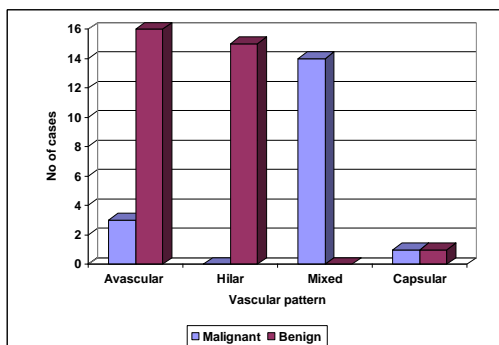
- 77.78% (n=14) cases of malignant lymph nodes showed presence of necrosis and 22.23% (n=4) cases showed absence of necrosis.
- 50% (n=16) cases of benign lymph nodes showed presence of necrosis and 50% (n=16) cases showed absence of necrosis.

Table-15: Association between vascular pattern and outcome in study group

Vascular pattern	Malignant	Benign	Total
Avascular	3	16	19
Hilar	0	15	15
Mixed	14	0	14
Capsular	1	1	2
Total	18	32	50

Chi-square = 36.86, P<0.0001

Bar diagram showing association between vascular pattern and outcome in study group.

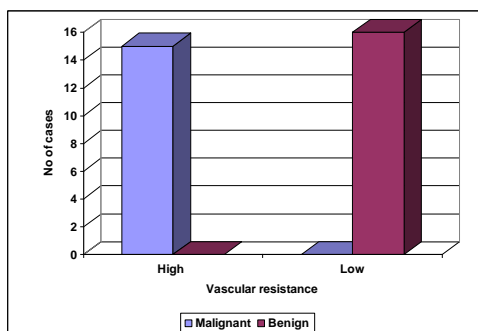


- 77.78% (n=14) cases of malignant lymph nodes showed mixed vascularity followed by 16.67% (n=3) cases which were avascular and 5.56% (n=1) cases showed capsular flow (n=1). None of the cases showed hilar flow.
- 50% (n=16) cases of benign lymph nodes of cases were avascular followed by 46.87% (n=15) cases which showed hilar flow and 3.12% (n=1) cases showed capsular flow. None of the cases showed mixed vascularity.

Table-16: Vascular resistance wise distribution of malignant and benign cases in study group

Vascular resistance	Malignant	Benign	Total
High	15	0	15
Low	0	16	16
Total	15	16	31

Bar diagram showing vascular resistance wise distribution of malignant and benign cases in study group.



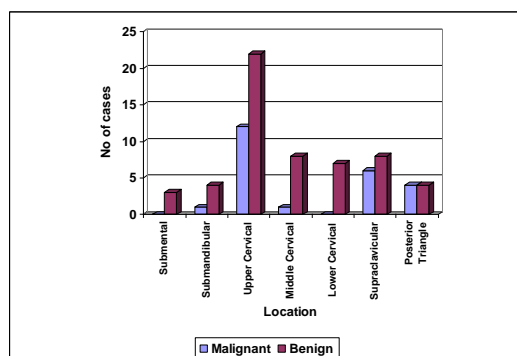
Out of 31 cases of lymph nodes showing vascularity, 15 malignant cases showed high vascular

resistance and 16 benign cases showed low vascular resistance.

Table-17: Location wise distribution of malignant and benign cases in study group

Location	Malignant	Benign	Total
Submental	0	3	3
Submandibular	1	4	5
Upper Cervical	12	22	34
Middle Cervical	1	8	9
Lower Cervical	0	7	7
Supraclavicular	6	8	14
Posterior Triangle	4	4	8
Total	24	56	80

Bar diagram showing location wise distribution of malignant and benign cases in study group.



- Out of the total number of malignant lymph nodes examined (n=24), 50% (n=12) of lymph nodes were in the upper cervical region, followed by 25% (n=6) of lymph nodes in the supraclavicular region; followed by 16.67% (n=4) of lymph nodes in the posterior triangle, 4.17% (n=1) of lymph nodes in middle cervical and submandibular region which had equal number of lymph nodes. No lymph nodes were seen in the submental and lower cervical region.
- Out of total number of benign lymph nodes examined (n=56), 39.28% (n=22) of lymph nodes were seen in the upper cervical region, followed by 14.28% (n=8) of lymph nodes at middle cervical and supraclavicular region which had equal number of lymph nodes, followed by 12.5% (n=7) of lymph nodes in lower cervical region, 7.14% (n=4) of lymph nodes in submandibular and posterior triangle region which showed equal number of lymph nodes and 5.35% (n=3) of lymph nodes in submental region.

DISCUSSION

This prospective study was carried out in Dr. D.Y. Patil Medical College, Hospital and Research Centre, Pimpri, Pune-18 over a period of two years in patients who were referred for ultrasonography of neck to department of radio-diagnosis for further examination. Patients were evaluated with Aloka Arietta S 60 USG machine with a linear probe L55 of

frequency 5-13 MHz was used. A convex transducer C 25P of 1-5 MHz frequency was used sometimes to assess deep lesions. A provisional diagnosis was given after USG examination and correlated with histopathology findings where ever applicable.

In our study of total 50 patients 80 lymph nodes were assessed out of which there were 30 (60%) males and 20 (40%) females (all age groups), and most of the cases (n=29) were present in the age group of 21-40 years (58%) and there were 32 benign cases (64%) and 18 malignant cases (36%).

Out of the total 32 cases of benign lymph nodes 19 (59.37%) were males and 13 (40.62%) were females and in all benign cases we had 16 (50%) cases of tuberculous lymph nodes and other 16 (50%) were of non-specific infection out of which 15 (46.87%) were reactive lymph nodes and 1 (3.12%) case was of suppurative lymphadenitis.

Out of the total 18 cases malignant group of lymph nodes 11(61.11%) were males and 7 (38.88%) were females and in all malignant cases we had 10 (55.55%) cases of head and neck malignancy, 3 (16.67%) cases of lymphoma and 5 (27.78%) cases of metastatic lymph nodes from an unknown primary.

In our study maximum number of patients with benign lymph nodes was in the age group of 21-40

years and patients with malignant lymph nodes were in the age group of 41-60 years. The mean age for malignant cases in our study was 42.89 and for benign lymph nodes were 31.22. Venkatesh Jayaraman *et al.* conducted a study in 30 patients and found out that there is a considerable difference in the mean age group of benign and malignant patients and it is due to the high incidence of malignancy in older age groups. Our study is in accordance with Venkatesh Jayaraman *et al.*[1].

Out of the 56 benign lymph nodes assessed (n=22) 39.28% were present in the upper cervical region, (n=8) 14.28% were seen in the middle cervical and supraclavicular region which had equal number of lymph nodes, followed by (n=7)12.5% in lower cervical group of lymph nodes, (n=4) 7.14% were present in the submandibular and posterior triangle group which had equal number of lymph nodes and (n=3) 5.35% of benign lymph nodes were present in the submental region.

Out of the total 24 malignant lymph nodes assessed (n=12) 50% were seen in the upper cervical region, followed by (n=6) 25% in the supraclavicular region and (n=4) 16.67% in the posterior triangle, (n=1) 4.17% of lymph nodes were seen in the middle cervical and submandibular group of lymph nodes, however no malignant lymph nodes were seen in the submental and lower cervical region in the malignant group of lymph nodes.

Kuna SK *et al.* conducted a study on 631 patients and found that, metastatic lymph nodes were situated in the lower third of the neck and reactively

enlarged lymph nodes occurred more frequently in the upper part of the neck. Our study correlate well with Kuna SK *et al* [4].

The benign lymph nodes had a S/L mean ratio of 0.50 with a standard deviation of 0.14 (0.50 ± 0.14) whereas malignant lymph nodes had a mean S/L ratio of 0.63 with a standard deviation of 0.15 (0.63 ± 0.15). Mahyar Gafoori *et al.* conducted a study in 43 patients in which he found that metastatic lymph nodes and a S/L ratio of more than 0.5 and benign lymph nodes had a S/L ratio of less than 0.5. Our study correlated well with Mahyar Gafoori *et al.*[5]. Ahuja AT *et al.* conducted a study and concluded that benign lymph nodes should have a S/L ratio of less than or equal to 0.5. Our study correlate well with Ahuja *et al.*[1]. Toriyabe *et al.* concluded from his study that malignant lymph nodes had a S/L ratio of >0.6 and benign lymph nodes had a S/Lratio <0.6 . Our study correlate well with Toriyabe *et al.*[6]Yushka *et al.* concluded from her study that malignant lymph nodes have a S/L ratio of >0.73 and benign lymph nodes had a S/L ratio < 0.54 . Our study is in accordance with Yushka *et al.*[7].

In benign group of lymph nodes (n=32), (n=16) 50% cases were of tuberculous lymph nodes. All tuberculous lymph nodes 100% (n=16) were oval in shape, (n=13) 81.25% cases showed fairly well defined margins however, (n=3) 18.75% cases showed presence of ill-defined margins/ extracapsular spread. (n=16) 100% cases of tuberculous lymph nodes were heterogeneous in echotexture with presence of necrosis and showed loss of fatty hilum. (Figure 1). One case showed presence of calcifications.

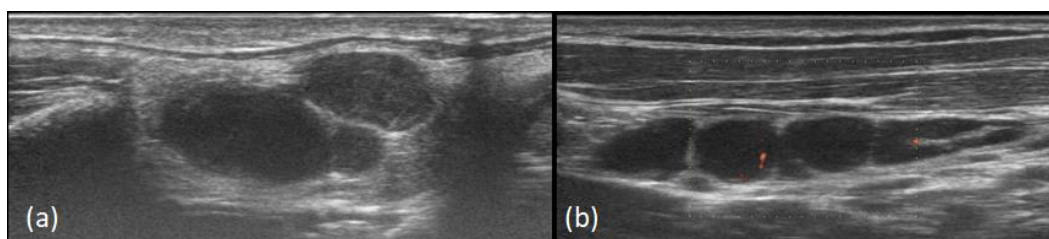


Fig-1: Tuberculous Lymph Nodes- (a) Well-defined conglomerate hypoechoic lymph nodes seen at upper and middle cervical lymph nodes on the right side. (b) Power Doppler image of the lymph node showing the avascular nature of the lymph node

In the benign group of lymph nodes (n=32), (n=15) 46.87% cases were reactive lymph nodes out of which (n=14) 93.34% cases were oval in shape and (n=1) 6.67% cases appeared to be round in shape. All

cases showed well-defined margins with maintained fatty hilum and appeared hypoechoic in echotexture. There was no presence of necrosis and calcifications in any of the cases. (Figure 2)

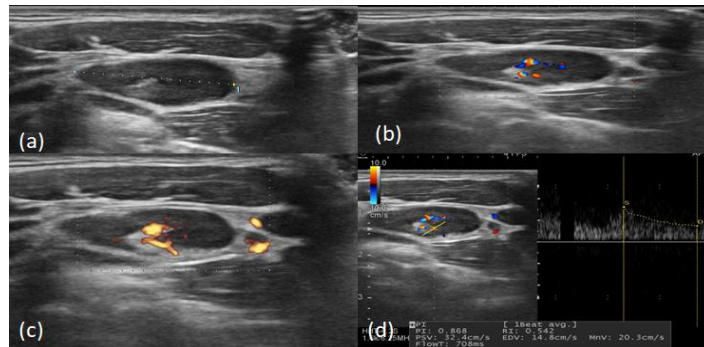


Fig-2: Reactive Lymph Nodes- (a) Well-defined hypoechoic lymph node seen at upper cervical region on the right side showing presence of echogenic fatty hilum. (b) Colour doppler image of the lymph node showing presence of central/hilar vascularity. (c) Power Doppler image of the lymph node showing presence of central/hilar vascularity. (d) R.I.=0.542 and P.I.=0.868 were recorded which were consistent with findings of benign lymph nodes of low vascular resistance. FNAC was suggestive of reactive lymph nodes.

There was a single case of suppurative lymphadenitis which was oval in shape with well-defined margins and loss of fatty hilum and appeared heterogeneous in echotexture with presence of central liquefaction. However, there was no presence of any calcifications within the lymph node.

There were in all 18 malignant cases out of which (n=14) 77.78% were round in shape and (n=4) 22.23% cases were oval in shape. (n=12) 66.67% cases showed presence of extracapsular spread with ill-defined margins and (n=6) 33.34% cases showed well-defined margins. (n=5) 27.78% cases of malignant

lymph nodes showed presence of fatty hilum and (n=13) 72.23% of cases showed absence of fatty hilum within the lymph nodes. (n=11) 61.12% cases of lymph nodes appeared heterogeneous in echotexture, (n=6) 33.34% cases appeared hypoechoic and (n=1) 5.56% cases appeared hyperechoic. (n=14) 77.78% cases showed presence of necrosis within the lymph nodes whereas in (n=4) 22.23% cases there was absence of necrosis within the lymph nodes. (Figures 3, 4) A single case of metastatic lymph node showed presence of calcifications as the metastasis was from papillary carcinoma of thyroid.

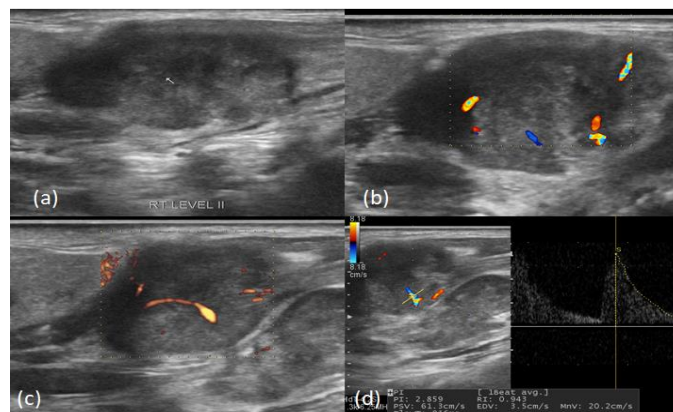


Fig-3: Metastatic Cervical Lymph Nodes- (a) Ill-defined heterogeneously hypoechoic lymph nodes seen at upper cervical region on right side. (b) Colour Doppler image of the lymph node showing mixed vascularity (both central as well as peripheral vascularity). (c) Power Doppler image of the lymph node showing mixed vascularity (both central as well as peripheral vascularity). (d) R.I.=0.943 and P.I.=2.859 of the lymph node was measured which showed findings of high vascular resistance consistent with findings of metastatic lymph nodes.

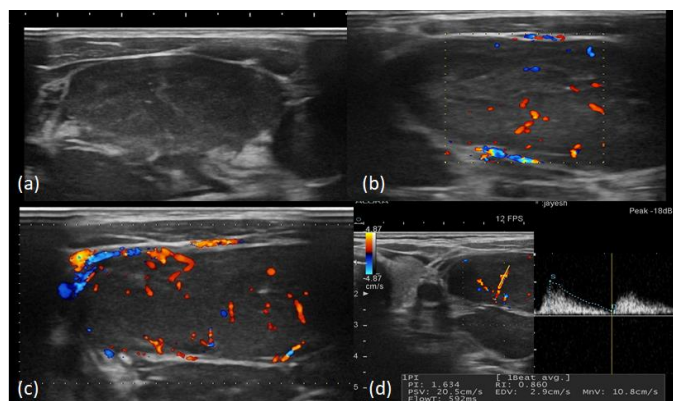


Fig-4: Hodgkin's Lymphoma- (a) Well-defined heterogeneous conglomerate lymph nodes seen on the left side at upper cervical region. (b) Colour Doppler image of the lymph node showing presence of mixed vascularity (central as well as peripheral). (c) Colour Doppler image of the lymph node showing presence of mixed vascularity (central as well as peripheral). (d) R.I.=0.860 and P.I.=1.634 were measured which were consistent with findings of high vascular resistance of metastatic lymph nodes. FNAC was suggestive of Hodgkin's lymphoma.

Yushka *et al.* conducted a study in which 73% non-malignant lymph nodes had presence of fatty hilum and 97% of metastatic lymph nodes had absence of fatty hilum. Our study is in accordance with Yushka *et al.*[7].

Chintamaneni Raja Lakshmi *et al.* conducted a study in which all malignant cases showed absence of fatty hilum and all benign cases showed presence of fatty hilum. In our study all cases of reactive lymph nodes showed presence of fatty hilum and 72.23 % malignant lymph nodes showed absence of fatty hilum. Our study correlate well with findings of Chintamaneni Raja Lakshmi *et al.*[8].

Ahuja *et al.* conducted a study in 286 patients and found out in his study that malignant lymph nodes were round in shape (56-100%), with absence of fatty hilum (57-91%) and had sharp borders (56-100%). In our study, 77.78% malignant lymph were round in shape with absence of fatty hilum in 72.23 % cases and 66.67% cases showed ill-defined margins due to extracapsular spread. Our study correlates well with Ahuja *et al.* [9].

Kuna SK *et al.* conducted a study in 631 patients and found that malignant lymph nodes were round in shape, with various echo structures but were predominantly hypoechoic, with absence of fatty hilum and presence of cystic necrosis. Our study is in accordance with Kuna SK *et al.*[4]

Out of the total 32 benign cases (n=16) 50% cases of tuberculous lymph nodes were avascular, (n=15) 46.87% cases of reactive lymph nodes showed presence of central/hilar vascularity and one case of suppurative lymphadenitis showed presence of capsular/peripheral vascularity. None of the cases of benign lymph nodes showed presence of mixed

vascularity within them. All 16 cases of benign lymph nodes showing vascularity showed presence of low vascular resistance flow within the lymph nodes. R.I. and P.I. of benign lymph nodes in this study were less than 0.8 and less than 1.5 respectively. (Figure 2).

Out of the total 18 malignant cases (n=3)16.67% cases of metastatic lymph nodes were avascular, (n=14) 77.78% cases showed presence of mixed vascularity (both peripheral and central vascularity) within them, (n=1) 5.56% cases showed presence of capsular/peripheral vascularity within the lymph nodes. However, none of the cases of metastatic lymph nodes showed presence of hilar vascularity within the lymph nodes. All 15 cases of metastatic lymph nodes which showing vascularity showed presence of high vascular resistance flow. R.I. and P.I. of malignant lymph nodes in this study were more than 0.8 and more than 1.5 respectively. (Figures 3,4).

Na DG *et al.* conducted a study in 105 patients and found out that 94% of benign reactive lymph nodes showed normal patterns of nodal vascularity; central hilar vascularity, radial symmetric central vascularity, and no peripheral vascularity. At least one of six abnormal patterns of vascularity (eccentric or absent hilar vascularity; deformed radial, aberrant multifocal, or absent central vascularity; and peripheral vascularity) was observed in 98% of malignant lymph nodes and he also established cut off values of 0.8 for the resistivity index and 1.5 for the pulsatility index that were 100% specific for malignancy. Our study correlate well with findings of Na DG *et al.*[10].

Michael Ying *et al.* conducted a study in 50 patients and found out that metastatic nodes (R.I. 0.81 ± 0.11 ; P.I. 1.89 ± 0.89) have higher intranodal vascular resistance than reactive nodes (R.I. 0.65 ± 0.08 ; P.I. 1.07 ± 0.26) and most of the metastatic nodes showed

presence of capsular vascularity (capsular, 16%; capsular and hilar, 78%), whereas majority of the reactive nodes showed hilar vascularity (98%). Our findings are in accordance with Michael Ying *et al.*[11].

Anil Ahuja *et al.* conducted a study on 118 patients with malignant lymph nodes and found out that 58.3% showed the presence of mixed (hilar and capsular) vascularity, 0.9% showed only hilar vascularity, 36.1% had peripheral vascularity, and 4.7% were avascular. In our study, 77.78 % malignant lymph nodes showed mixed, 5.56 % had peripheral vascularity and 16.67 % were avascular. Our study is in accordance with Anil Ahuja *et al.*[12].

Few limitations were observed while conducting the study. Echogenic fatty hilum was maintained in few cases of metastatic lymph nodes, especially in early stages. Many of the metastatic lymph nodes had ill-defined margins at the time of diagnosis due to extracapsular spread. Few cases of metastatic lymph nodes were avascular.

CONCLUSIONS

Grey scale Ultrasonography, Colour Doppler and Power Doppler were extremely useful in studying characteristics of benign and malignant lymph nodes. Benign lymph nodes were observed in younger age group and malignant cervical lymph nodes were seen in the older age group. Upper and middle cervical lymph nodes were commonly involved in benign etiology. Upper cervical, supraclavicular and posterior triangle were commonly involved in malignant lymph nodes. Majority of reactive lymph nodes were oval in shape, hypochoic in echotexture with maintained echogenic central hilum with hilar vascularity. Tuberculous lymph nodes were oval in shape, with heterogeneous echotexture due to central necrosis and loss of fatty hilum and were avascular.

Metastatic lymph nodes were commonly observed due to head and neck malignancy, majority were round in shape with irregular margins due to extracapsular spread, appeared heterogeneous with loss of fatty hilum and showed mixed vascularity with high R.I. and P.I. values due to increased resistance. Metastatic lymph node from papillary carcinoma of thyroid showed calcification. Good correlation was observed with histopathology in differentiating between benign and malignant lymph nodes.

REFERENCES

1. Ahuja AT, Ying M, Ho SY, Antonio G, Lee YP, King AD, Wong KT. Ultrasound of malignant cervical lymph nodes. *Cancer Imaging* 2008;8:48-56.
2. Ahuja A, Ying M. Sonography Of Neck Lymph Nodes, part II: Abnormal Lymph Nodes. *Clinical Radiology* 2003;58:359-366.

3. Jayaraman Venkatesh, Austin Ravi David, Ramasamy. The Efficacy Of Colour Doppler Ultrasound In Differentiating Malignant And Nonmalignant Head And Neck Lymph Node Enlargement. *International Journal Of Dental Science And Research* 2013;vol. 1 no.1:8-15.
4. Kuna SK, Bracic I, Tesic V, Kuna K, Herceg GH, Dodig D. Ultrasonographic differentiation of benign from malignant neck lymphadenopathy in thyroid cancer. *J Ultrasound Med* 2006;25:1531-1537.
5. Ghafoori M, Azizian A, Pourrajabi Z, Vaseghi H. Sonographic Evaluation of Cervical Lymphadenopathy; Comparison of Metastatic and Reactive Lymph Nodes in Patients With Head and Neck Squamous Cell Carcinoma Using Gray Scale and Doppler Techniques. *Iranian Journal of Radiology*. 2015;12(3):e11044.
6. Toriyabe Y, Nishimura T, Kita S, Saito Y, Miyokawa N. Differentiation between benign and metastatic cervical lymph nodes with ultrasound. *Clinical radiology*. 1997 Dec 1;52(12):927-32.
7. Chang DB, Yuan A, Yu CJ, Luh KT, Kuo SH, Yang PC. Differentiation of benign and malignant cervical lymph nodes with color Doppler sonography. *AJR. American journal of roentgenology*. 1994 Apr;162(4):965-8.
8. Lakshmi Chintamaneni Raja, Rao SM, Ravikiran A, Satish Sivan, Bhavana SM. Evaluation Of Ultrasonographic Parameters In Different Benign And Metastatic Cervical Group Of Lymph Nodes. *ISNR Otolaryngology*. Volume 2014.
9. Ahuja A, Ying M, King W, Metreweli C. A practical approach to ultrasound of cervical lymph nodes. *The Journal of Laryngology & Otology*. 1997 Mar;111(3):245-56.
10. Na DG, Lim HK, Byun HS, Kim HD, Ko YH, Baek JH. Differential diagnosis of cervical lymphadenopathy: usefulness of color Doppler sonography. *AJR. American journal of roentgenology*. 1997 May;168(5):1311-6.
11. Ahuja A, Ying M, Ho S, Metreweli C. Distribution of intranodal vessels in differentiating benign from metastatic neck nodes. *Clinical radiology*. 2001;56(3):197—201.
12. Ahuja A, Ying M, King A, Yuen HY. Lymph node hilus: gray scale and power Doppler sonography of cervical nodes. *Journal of ultrasound in medicine*. 2001 Sep 1;20(9):987-92.