

Inflammatory Fibroid Polyp of Ileum: A Case Report

Nanda Patil¹, Jyoti Tele², Neha Sharma^{3*}

¹Professor, Department of Pathology, Krishna Institute of Medical Sciences, Deemed to be University, Karad, Maharashtra, India

²Assistant Professor, Department of Pathology, Krishna Institute of Medical Sciences, Deemed to be University, Karad, Maharashtra, India

³Tutor, Department of Pathology, Krishna Institute of Medical Sciences, Deemed to be University, Karad, Maharashtra, India

Case Report

*Corresponding author

Neha Sharma

Article History

Received: 20.10.2018

Accepted: 27.10.2018

Published: 30.11.2018

DOI:

10.36347/sjams.2018.v06i11.031



Abstract: Inflammatory fibroid polyps are benign tumors which arise from the submucosa of the stomach, small intestine, large intestine and oesophagus. They form polypoid lesion and present as intussusception or intestinal obstruction. Case history: We present a case of inflammatory fibroid polyp in a male patient of 52 years age. The polyp was arising from the lumen of ileum and presented as intestinal obstruction. Conclusion: Histopathological examination plays an important role in the diagnosis of intestinal fibroid polyp in cases presenting as intussusception or intestinal obstruction, as radiological and clinical features have no distinctive role in the diagnosis of these lesions.

Keywords: Inflammatory fibroid polyp, ileum, intestinal obstruction.

INTRODUCTION

Inflammatory fibroid polyps (IFP) are rare benign tumors of mesenchymal nature. Their origin is from submucosa of the stomach, small intestine and rarely in the oesophagus and in the colon [1-3]. In 1949, Josef Vanek reported 6 cases of gastric lesion as gastric submucosal granuloma with eosinophilic infiltration [4]. In 1953, Helwig and Ranier first described the term Intestinal fibroid polyp [5]. For decades, intestinal fibroid polyps were regarded as reactive lesions. However, in 2008 the neoplastic nature of intestinal fibroid polyp became obvious with the detection of PDGFRA mutations in these neoplasms [6].

CASE REPORT

A 52 year old male patient presented in surgical OPD with pain in abdomen, vomiting and constipation since 2 days.

X-ray abdomen showed multiple air-fluid levels (Figure 1). Ultrasonography of abdomen revealed features of acute small bowel obstruction (Figure 2). Peripheral blood smear was within normal limits. Emergency exploratory laparotomy was done and a segment of ileum was sent for histopathological examination.

Gross examination revealed a segment of ileum measuring 8 cm in length. The lumen revealed a polypoid mass measuring 4 x 3.3 x 3.1 cm. External surface was grey brown. Cut section was solid, grey white with area of hemorrhages (Figure 3 and 4). Rest

of the mucosal surface of ileum was unremarkable. Microscopy of sections from the lesion revealed a polypoid mass arising from the submucosa of the ileum. There was surface ulceration covered with inflammatory exudate. The polyp showed edematous connective tissue with numerous vascular channels and intervening thin smooth muscle bundles. Inflammatory cell infiltrate with predominance of eosinophils was noted (Figure 5,6,7).

Considering these features diagnosis was given as Intestinal fibroid polyp arising from the ileum. Six months follow-up of this patient is uneventful.

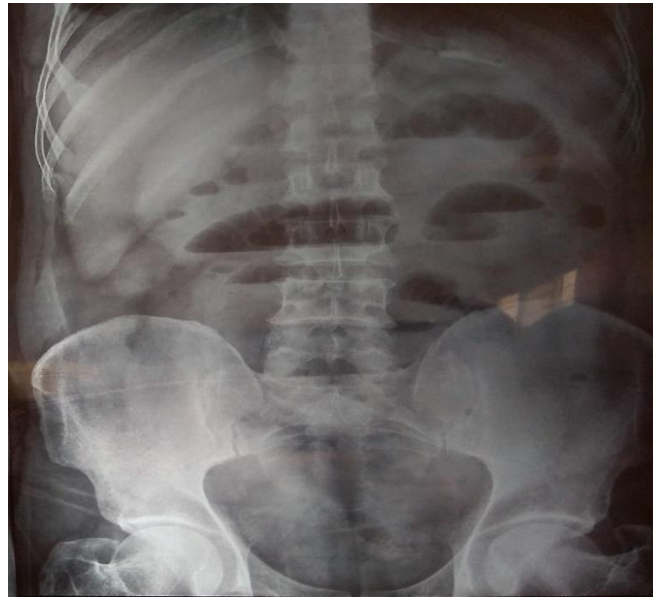

Fig-1: X-ray abdomen showing multiple air-fluid levels

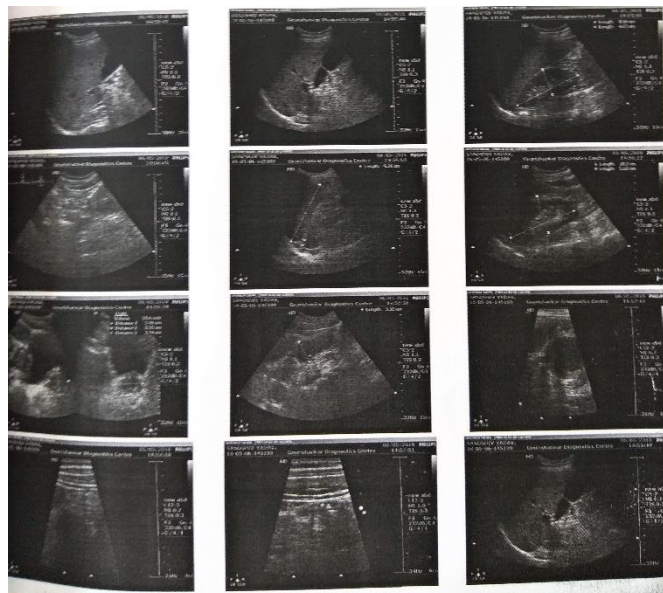

Fig-2: Ultrasonography of abdomen showing features of small bowel obstruction

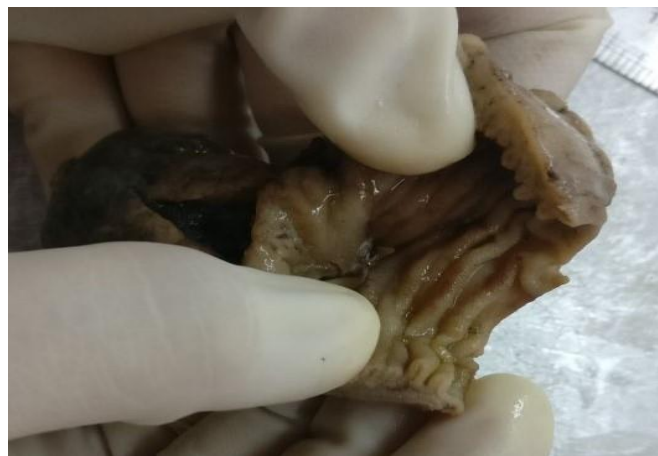

Fig-3: Polypoidal mass arising from the lumen of the ileum.

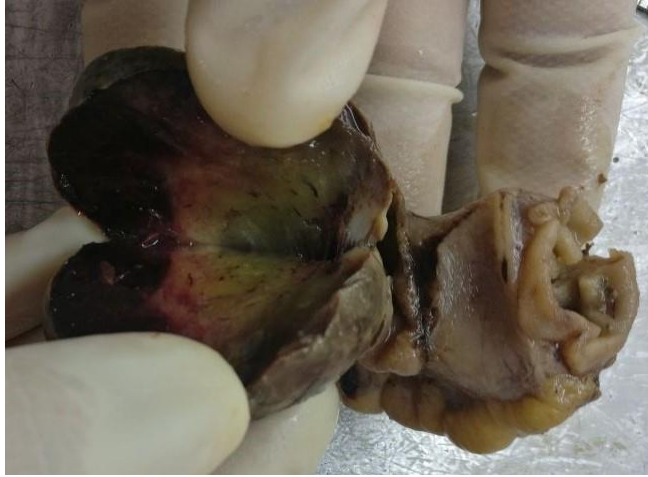

Fig-4: Cut section of the mass showing grey white and hemorrhagic areas

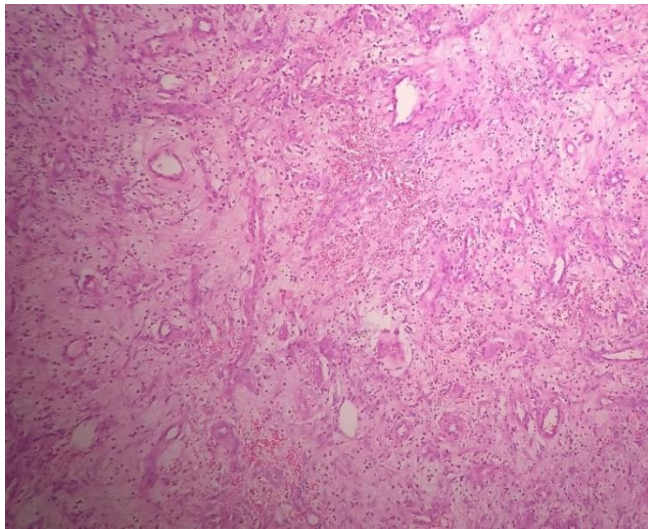


Fig-5: The polyp composed of proliferative connective tissue and prominent vascular elements with inflammatory cell infiltrate (H&E, x 100)

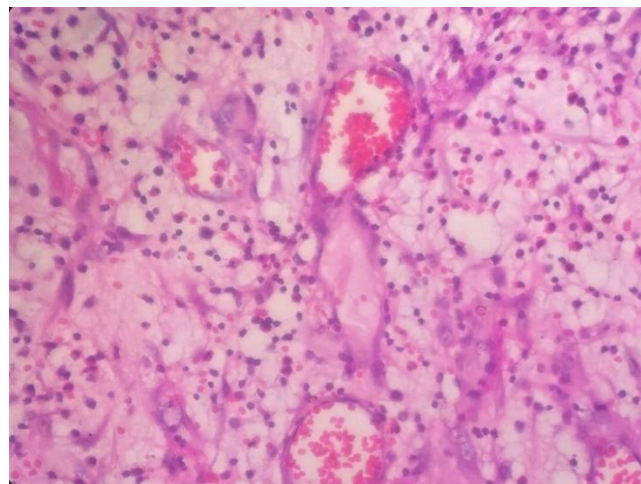


Fig-6: Inflammatory cell infiltrate with proliferating vascular channels. (H&E, x 400)

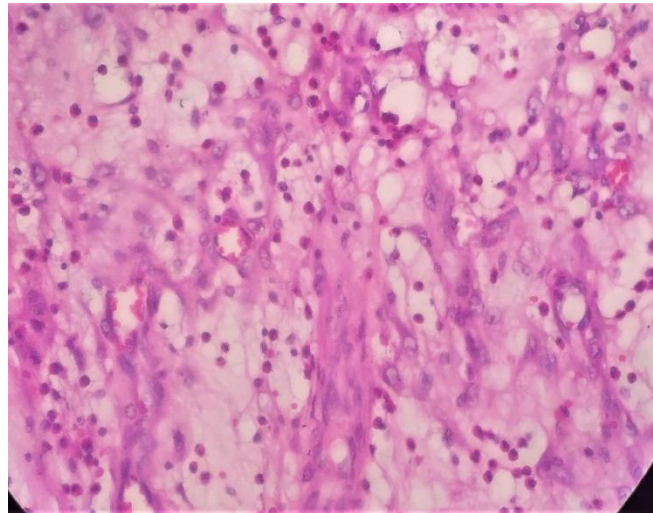


Fig-7: Inflammatory cell infiltrate showing eosinophils (H&E, x 400)

DISCUSSION

Inflammatory fibroid polyps reveal a slight female preponderance and occur in a wide range from 2 – 90 years, the mean age being 60 years [7, 8]. The clinical features of IFP depend upon the size and site of the lesion. IFPs originating from the stomach and large intestine present as incidental finding discovered during surgical procedures performed for other reasons. IFPs arising from small intestine often present as intussusception or intestinal obstruction. Duodenal IFPs are rare and may present with biliary obstruction [9-11].

Our case was a male patient presented as intestinal fibroid polyp of ileum at the age of 52 years with complaints of intestinal obstruction. Gross examination of IFP reveal a solitary sessile or polypoidal lesion usually less than 5 cm. Histologically, they are well circumscribed lesions arising from submucosa and splay muscularis mucosae. These polyps reveal bland, spindle shaped cells set in a myxoid, edematous or fibrous background with numerous small to medium sized blood vessels and inflammatory infiltrate predominantly composed of eosinophils with few lymphocytes and plasma cells[7].

The differential diagnosis of IFP includes GISTs, schwannoma, leiomyoma, neurofibroma, inflammatory myofibroblastic tumor (IMT) and eosinophilic gastroenteritis. The characteristic microscopic features of IFP rule out these conditions. GISTs are DOG1 and CD117 positive unlike IFPs. S100 protein positivity helps in the diagnosis of schwannoma and neurofibroma. Eosinophilia in peripheral blood favours the diagnosis of parasitic infestation. Eosinophilic gastroenteritis does not present as a mass lesion. Hence, the classical microscopic features are helpful in making the diagnosis of IFPs[12]. IFPs have no distinctive radiological or clinical findings.

The treatment of intestinal fibroid polyp is surgical resection and the recurrence rate is very rare [13,14].

CONCLUSION

Intestinal fibroid polyps are benign lesions with low rate of recurrence. Since clinical examination and radiological findings are not helpful, histopathological examination plays a definitive role in making the diagnosis of IFPs presenting as intussusception or intestinal obstruction.

REFERENCES

1. Shih L-N, Chang S-L, Chuang S-M, Kuo C-F. Inflammatory fibroid polyp of the jejunum causing intussusception. *Am J Gastroenterol.* 1997; 92: 162-4.
2. De La Plaza R, Picardo AL, Cuberes R, Jara A, Martinez-Penalver I, Villanueva MC, Medina M, Alias D, Osorio S, Pacheco E, Suarez A. Case report: inflammatory fibroid polyps of the large intestine. *Digestive diseases and sciences.* 1999 Sep 1;44(9):1810-6.
3. Ott DJ, Wu WC, Shiflett DW, Pennell TC. Inflammatory fibroid polyp of the duodenum. *Am J Gastroenterol.* 1980; 73: 62-4.
4. Vanek J. Gastric submucosal granuloma with eosinophilic infiltration. *Am J Pathol.* 1949;25:397-411.
5. Helwig EB, Ranier A. Inflammatory fibroid polyps of the stomach. *Surg Gynecol Obstet.* 1953 Mar;96(3):335-67.
6. Schildhaus HU, Cavlar T, Binot E, Büttner R, Wardelmann E, Merkelbach-Bruse S. Inflammatory fibroid polyps harbour mutations in the platelet-derived growth factor receptor alpha (PDGFRA) gene. *J Pathol.* 2008 Oct;216(2):176-82.
7. Liu TC, Lin MT, Montgomery EA, Singhi AD. Inflammatory fibroid polyps of the gastrointestinal tract: spectrum of clinical, morphologic, and

- immunohistochemistry features. *Am J Surg Pathol.* 2013;37:586-592.
8. Ozolek JA, Sasatomi E, Swalsky PA, Rao U, Krasinskas A, Finkelstein SD. Inflammatory fibroid polyps of the gastrointestinal tract: clinical, pathologic, and molecular characteristics. *Appl Immunohistochem Mol Morphol.* 2004;12:59-66.
 9. Dawson PM, Shousha S, Burn JI. Inflammatory fibroid polyp of the small intestine presenting as intussusception. *Br J Clin Pract.* 1990; 44: 495-7.
 10. Kerr WH, Mark JBD. Ileal intussusception in the adult due to inflammatory fibroid polyps. *Surgery.* 1968; 63: 604-8.
 11. Dilawari RA, Patterson WB. Inflammatory fibrous polyp (pseudotumor) of ileum, a rare cause of intestinal obstruction. *Am Surgeon.* 1976; 4: 920-2.
 12. Lasota J, Wang ZF, Sobin LH, Miettinen M. Gain-of-function PDGFRA mutations, earlier reported in gastrointestinal stromal tumors, are common in small intestinal inflammatory fibroid polyps. A study of 60 cases. *Mod Pathol.* 2009;22:1049-1056.
 13. Anthony PP, Morris DS, Vowles KDJ. Multiple and recurrent inflammatory fibroid polyps in three generations of a Devon family: a new syndrome. *Gut* 1984; 25: 854-62.
 14. McGreevy P, Doberneck RC, McLeay JM, Miller FA. Recurrent eosinophilic infiltrate (granuloma) of the ileum causing intussusception in a two-year-old child. *Surgery.* 1967; 61: 280-4.