


Adult Idiopathic Hypertrophic Pyloric Stenosis Complicated by a Mega-Stomach: A Case Report and Review of the Literature

Hafida Sghir^{2*}, Imane Elhidaoui², Karima Benjouad², Yomna Dannouni², Sofia Oubaha¹, Zouhour Samlani², Khadija Krati²

¹Physiology Department, Faculty of Medicine and Pharmacy at Cadi Ayyad University, Marrakech

²Gastroenterology Department, Mohammed VI University Hospital, Marrakech

<p>Case Report</p> <p>*Corresponding author Hafida Sghir</p> <p>Article History Received: 15.12.2018 Accepted: 26.12.2018 Published: 10.01.2019</p> <p>DOI: 10.21276/sasjm.2019.5.1.1</p> 	<p>Abstract: In children, idiopathic hypertrophic pyloric stenosis (IHPS) is a relatively common disease (1). However, in adults it is a rare cause of gastric obstruction (2,3). We report a case of a 55-year-old female patient who presented with chronic postprandial vomiting associated to epigastric pain and fullness. She underwent upper gastrointestinal endoscopy that showed residual food and a distended stomach with a constricted and impenetrable pylorus. The upper gastrointestinal barium study showed a distended stomach with delayed gastric emptying due to pyloric stenosis. The abdominal CT scan revealed thickening of the distal stomach. The patient underwent a gastrectomy with gastrojejunal anastomosis. The pathology revealed hypertrophy and hyperplasia of the inner circular muscle of the pylorus without any malignancy, which was compatible with IHPS. We reported this case to clarify this rare disease.</p> <p>Keywords: Idiopathic hypertrophic stenosis, adults, obstruction, distended stomach, chronic vomiting.</p>
---	--

Copyright © 2019: This is an open-access article distributed under the terms of the Creative Commons Attribution license which permits unrestricted use, distribution, and reproduction in any medium for non-commercial use (NonCommercial, or CC-BY-NC) provided the original author and source are credited.

INTRODUCTION

In children, congenital hypertrophic pyloric stenosis is a relatively common disease [1]. However, hypertrophic stenosis of the pylorus in adults is a rare cause of gastric obstruction [2, 3]. There are only about 200 cases of primary hypertrophic pyloric stenosis in adults reported in the literature [4]. Approximately 80% of the cases reported to date were men and the age of onset is extremely variable, ranging from 17 to 82 years [2, 5, 6-8]. Untreated, the disease leads to several complications, hence the interest of clarifying this affection by this observation with review of the literature.

Observation

This is the case of a 55-year-old woman with a history of unexplored chronic epigastric pain and intermittent chronic vomiting for more than 15 years. In the past year, the vomiting worsened and became persistent and mostly post-prandial, associated with epigastric fullness and easy satiety with asthenia and severe weight loss.

On admission, the patient was dehydrated and malnourished with a BMI of 16 kg / m². Her clinical

examination noted epigastric tenderness without any masses. Lab results showed: hyponatremia, hypocalcemia, acute kidney failure, hypocholesterolemia and hypoalbuminemia.

An etiological evaluation is then performed including an upper gastrointestinal endoscopy, which has shown residual food and a distended stomach with a constricted and impenetrable pylorus. There was no evidence of an ulcer or other mucosal defect in the pyloric channel. The abdominal CT scan noted a thickening of the wall in distal stomach with a mega-stomach arriving at the hypogastrium. An UGI barium study showed delayed gastric emptying with a stomach reaching the pelvis and an elongated narrowing pyloric channel.

The management consisted in a nutritional rehabilitation of the patient, a discussion of the case in a multidisciplinary consultation meeting where a surgical treatment was indicated. At exploratory laparotomy, a massively dilated stomach was found, the pylorus was thickened and no adhesion was noted. The patient underwent a gastrectomy with gastrojejunal anastomosis. The surgery was uneventful.

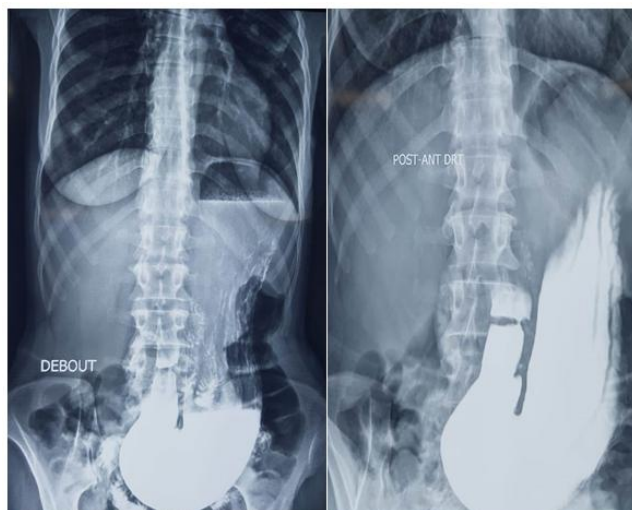


Image: UGI barium showed delayed gastric emptying with a stomach reaching the pelvis and an elongated narrowing pyloric channel

The pathology revealed no malignancy but showed prominent hypertrophy and hyperplasia of the inner circular muscle layer of pylorus. Hypertrophy of muscularis mucosae with muscle strands within the lamina propria was also noted. The patient was then diagnosed with AIHPS as any evidence of malignancy had been ruled out. Postoperatively, the patient had a gradual recovery with a satisfactory weight gain after 6 months.

DISCUSSION

Adult idiopathic hypertrophic pyloric stenosis is a rare condition; approximately 200 cases have been reported in the literature [4]. This condition is most often congenital, affecting approximately 6 children out of 1000 newborns with a peak frequency between the third and the twelfth week of life [9]. It could be classified as primary and secondary. Secondary types are more common and can be induced by many causes, including scarring of anterior gastric or duodenal ulcers, hypertrophic gastritis, carcinomas, gastrointestinal stromal tumors, bezoars, vagal hyperactivity and postoperative extrinsic adhesions [10, 11].

The development of hypertrophic stenosis of the pylorus without predisposing factor is defined as primary or idiopathic, and is characterized by hypertrophy and hyperplasia of the pyloric muscle. The exact occurrence of this pathology in adults cannot be accurately estimated because cases may remain asymptomatic. For no known reason, hypertrophic stenosis of the adult pylorus occurs more frequently in middle-aged and male patients [12, 13].

The etiology of hypertrophic stenosis of the pylorus is still uncertain. It seems that both genetic and environmental factors are involved. Several hypotheses suggest that this entity is due to the persistence of the mild infantile form that persists in adult life [11, 14, 15, 4]. Hypertrophy of the pylorus may not become

symptomatic until certain factors are added such as edema, spasm, or inflammation[15-17] Other possible etiologies have been suggested such as prolonged pylorospasm, vagal hyperactivity, and neuromuscular incoordination due to changes in the plexus[18, 17].

The clinical manifestations are variable. These are usually the same signs of high digestive obstruction, mainly with abdominal pain, persistent vomiting, early satiety, anorexia, and dyspepsia and weight loss [19, 20].

The radiological signs of AIHPS are not pathognomonic. UGI barium study is indicated but cannot differentiate AIHPS from tumors or inflammatory disorders [11, 17]. The diagnosis should be suspected if it shows elongation of 2-4 cm of the pyloric channel with various degrees of obstruction. It should be emphasized that the radiographic diagnosis should be based on the presence of several findings because no individual sign is pathognomonic. Trans-abdominal ultrasonography is successfully used for the diagnosis of the infantile form of hypertrophic stenosis of the pylorus. Its utility for the diagnosis of adult hypertrophy is also described [2].

The endoscopic aspect is that of a stenosis of the pyloric channel with gastric distension. Endoscopy is often necessary to establish the diagnosis of the disease and exclude other causes. Schuster has defined a unique endoscopic sign called the "cervical sign" to describe the narrowing of the pylorus [21].

Pathologically, microscopic examination notes marked hypertrophy and hyperplasia of inner circular muscle layer of pylorus, which may be associated with reactive mucosal gastropathy. However, there should be no process of inflammation or neoplasm seen in the muscularis propria[4].

The indicated treatment is surgery in symptomatic or complicated forms. Partial gastrectomy, gastroenterostomy, pyloromyotomy, and pyloroplasty have been proposed as treatments by various physicians. Endoscopic dilatation has also been suggested but has a high rate of recurrence. Some authors prefer partial gastrectomy because of a high risk of malignant transformation [22, 19].

CONCLUSION

Adult idiopathic hypertrophic pyloric stenosis is a rare and unrecognized condition of the gastric wall. This is a difficult clinical and radiological diagnosis. Therefore; it should be discussed whenever a pyloric stenosis that has neither intrinsic cause nor malignant proliferation is found on pathological examination. Treatment is surgical, especially in symptomatic cases.

REFERENCES

- Graadt van Roggen JF, van Krieken JH. Adult hypertrophic pyloric stenosis: case report and review. *J ClinPathol.* 1998; 51: 479-80.
- Quigley RL, Pruitt SK, Pappas TN, Akwari O. Primary hypertrophic pyloric stenosis in the adult. *Arch Surg.* 1990; 125: 1219-21.
- Kreel L, Harold E. Pyloric stenosis in adults: a clinical and radiological study of 100 consecutive patients. *Gut* 1965; 6: 253-60.
- Thielemann H, Anders S, Naveke R, Diermann J. Primary hypertrophic pyloric stenosis. A rare form of stomach outlet stenosis in the adult. *ZentralblChir.* 1999; 10: 947-9.
- Barling HG. Hypertrophic stenosis of the pylorus in adults. *Lancet.* 1913; 1: 231-2.
- Lewin KJ, Riddell RH, Weistein WM. *Gastrointestinal pathology and its clinical implications*, 1st Ed. New York. Igaku-Shoin. 1992
- Hackamimi H, Cogbill CL. Primary adult hypertrophic pyloric stenosis. Case report and review of literature. *Am Surg.* 1968; 34: 446-9.
- Orsoni P, Merrot T, Berdah S, mambrini p, sappa p, grimaud jc, picaud r. L'hyperplasie fibromusculaire antro-pylorique de l'adulte: une cause rare de stenose digestive haute. *Gastroentérologie clinique et biologique.* 1996;20(11).
- Rollins MD, Shields MD, Quinn RJM, Wooldridge MAW. Pyloricstenosis: congenital or acquired? *Arch Dis Child.*1989;64:138—47
- Simson JNL, Thomas AJ, Stoker TAM. Adult hypertrophic pyloricstenosis and gastric carcinoma. *Br J Surg* 1986;73:379_80.
- Dye TE, Vidals VG, Lockhart CE, Snider WR. Adulth yperrophicpyloric stenosis. *Am Surg* 1979;45:478_84.
- Knight CD. Hypertrophic pyloric stenosis in the adult. *AnnS urg.*1961;153:899_910.
- Craver WL. Hypertrophic pyloric stenosis in adults. *Gastroenterology.*1957;33:914_24.
- Kirklin BR, Harris MT. Hypertrophy of the pyloric muscle of adults: a distinctive roentgenologic sign. *Am J Roentgenol.* 1933;29:437_42.
- Bateson EM, Talerman A, Walrond ER. Radiological and pathological observations in a series of seventeen cases of hypertrophic pyloric stenosis of adults. *Br J Radiol.* 1969;42:1
- Keynes WM. Simple and complicated hypertrophic pyloric stenosis in the adult. *Gut* 1965;6:240-52.
- MacDonald JA. Adult hypertrophic pyloric stenosis. *Br J Surg.* 1973;60(1):73–75.
- Taliaferro L, Barnett TA, Mann NS. Adult hypertrophic pyloric stenosis: case report. *Texas Med.* 1986; 82:27_8.
- Zúñiga SR. Estenosispilóricahipertrófica en el adulto. *Rev MedHondur.* 1979;47:37---42.
- North JP, Johnson JH Jr. Pyloric hypertrophy in the adult. *AnnSurg.* 1950;131:316---29
- Schuster MM. The pyloric" cervix sign" in adult hypertrophic pyloric stenosis. *Gastrointest Endosc.* 1970;16:210-1.
- Hellan M, Lee T, Lerner T. Diagnosis and therapy of primaryhypertrophic pyloric stenosis in adults: case report and reviewof literature. *J Gastrointest Surg.* 2006;10:265---9.